

CT Scan in Subaxial Cervical Facet Injury: Is It Enough for Decision-Making?

Juan P. Cabrera, MD^{1,2} , Ratko Yurac, MD^{3,4} ,
Andrei F. Joaquim, MD, PhD⁵ , Alfredo Guiroy, MD⁶ ,
Charles A. Carazzo, MD, MSc⁷ , Juan J. Zamorano, MD^{3,4},
Marcelo Valacco, MD⁸, and the AO Spine Latin America
Trauma Study Group

Global Spine Journal
2023, Vol. 13(2) 344–352
© The Author(s) 2021
Article reuse guidelines:
sagepub.com/journals-permissions
DOI: 10.1177/2192568221995491
journals.sagepub.com/home/gsj



Abstract

Study Design: Cross-sectional survey.

Objectives: Assessment of subaxial cervical facet injuries using the AO Spine Subaxial Cervical Spine Injury Classification System is based on CT scan findings. However, additional radiological evaluations are not directly considered. The aim of this study is to determine situations in which spine surgeons request additional radiological exams after a facet fracture.

Methods: A survey was sent to AO Spine members from Latin America. The evaluation considered demographic variables, routine use of the Classification, as well as the timepoint at which surgeons requested a cervical MRI, a vascular study, and/or dynamic radiographs before treatment of facet fractures.

Results: There was 229 participants, mean age 42.9 ± 10.2 years; 93.4% were men. Orthopedic surgeons 57.6% with 10.7 ± 8.7 years of experience in spine surgery. A total of 86% used the Classification in daily practice. An additional study (MRI/vascular study/and dynamic radiographs) was requested in 53.3%/9.6%/43.7% in F1 facet injuries; 76.0%/20.1%/50.2% in F2; 89.1%/65.1%/28.4% in F3; and 94.8%/66.4%/16.6% in F4. An additional study was frequently required: F1 72.5%, F2 86.9%, F3 94.7%, and F4 96.1%.

Conclusions: Spine surgeons generally requested additional radiological evaluations in facet injuries, and MRI was the most common. Dynamic radiographs had a higher prevalence for F1/F2 fractures; vascular studies were more common for F3/F4 especially among surgeons with fewer years of experience. Private hospitals had a lower spine trauma cases/year and requested more MRI and more dynamic radiographs in F1/F2. Neurosurgeons had more vascular studies and dynamic radiographs than orthopedic surgeons in all facet fractures.

Keywords

spinal injuries, magnetic resonance imaging, tomography, radiography, facet joint, spine, vertebral artery

¹ Department of Neurosurgery, Hospital Clínico Regional de Concepción, Concepción, Chile

² Faculty of Medicine, University of Concepción, Concepción, Chile

³ Department of Orthopedic and Traumatology, University del Desarrollo, Santiago, Chile

⁴ Spine Unit, Department of Traumatology, Clínica Alemana, Santiago, Chile

⁵ Department of Neurosurgery, University of Campinas (UNICAMP), Campinas-SP, Brazil

⁶ Spine Unit, Orthopedic Department, Hospital Español de Mendoza, Mendoza, Argentina

⁷ Neurosurgery, University of Passo Fundo, São Vicente de Paulo Hospital – Passo Fundo – RS, Brazil

⁸ Department of Orthopedic and Traumatology, Hospital Churrucá Visca, Buenos Aires, Argentina

Corresponding Author:

Juan P. Cabrera, Department of Neurosurgery, Hospital Clínico Regional de Concepción, San Martín 1436, Concepción, Chile.

Email: jucabrera@udec.cl



Creative Commons Non Commercial No Derivs CC BY-NC-ND: This article is distributed under the terms of the Creative Commons Attribution-Non Commercial-NoDerivs 4.0 License (<https://creativecommons.org/licenses/by-nc-nd/4.0/>) which permits non-commercial use, reproduction and distribution of the work as published without adaptation or alteration, without further permission provided the original work is attributed as specified on the SAGE and Open Access pages (<https://us.sagepub.com/en-us/nam/open-access-at-sage>).

Introduction

Fractures of the cervical spine are generally treated based on the classification of injuries according to different existing classification systems.¹⁻³ The AO Spine Subaxial Cervical Spine Classification System is one of the newest proposed systems with some validated clinical studies and an acceptable reliability.⁴ This classification is based on morphological characteristics of the fracture including facet injuries, neurological status, and additional modifiers such as bone quality and comorbidities.⁵

In this context, cervical facet fractures can be seen as isolated or concomitant to more severe injuries potentially requiring additional radiological evaluation. The most common radiological methods used for diagnosing cervical trauma besides CT scans include cervical magnetic resonance imaging (MRI), which allows better evaluation of neural elements as well as soft tissue injuries. Arterial studies such as CT angiogram, MR angiogram, or digital subtraction angiography can evaluate the vertebral artery. Dynamic cervical spine lateral radiographs can rule out occult instability. In Latin America, some trauma centers do not provide further radiological evaluations in an emergency setting, which can significantly delay the management of these fractures thereby increasing their morbidity.⁶

Here, we focused on each type of cervical facet fractures and we performed a survey to analyze this problem considering the scarce information available in the literature about the real needs and benefits of additional radiological evaluation, as well as the potential delay in treatment on account of having these exams in most spinal trauma centers from developing countries. The aim of this study is to determine situations in which spine surgeons request complementary radiological exams after a diagnosis of a subaxial cervical facet fracture on a CT scan.

Materials and Methods

Study Design

This was a cross-sectional survey was performed. The survey was sent by e-mail to spine surgeons who were members of AO Spine from Latin America. A total of 987 members received an e-mail from AO Spine.

Questions Regarding Subaxial Cervical Spine Fractures

General questions: We enquired about the demographic features of the participants and surgeon characteristics as well as specific questions to evaluate the surgeon's opinion regarding the diagnosis of subaxial cervical spine fractures (C3–C7). The variables analyzed were nationality, gender, age, surgeon's specialty, years of experience, level of complexity of the hospitals, number of spine trauma surgeries per year, and the use (or not) of the AO Spine Subaxial Cervical Spine Injury Classification System in daily practice.

Specific questions: We assessed the needs of additional radiological evaluation besides CT scans in F1, F2, F3, and F4 facet fractures. The radiological exams proposed to the surgeons were: a cervical spine MRI, a vascular study of any type, and a dynamic cervical spine analysis via simple plain radiographs before the decision to treat each type of facet fracture. We only provided the type of the facet fracture; there was no description of the neurological status.

Collecting Data

The survey was sent twice to the community of members registered to AO Spine with a 10-day interval during May 2020. The e-mail contained an explanation of the AO Subaxial Cervical Spine Classification, the purpose of the study, and a link to the classification system.

Facet Injury According to AO Spine Subaxial Cervical Spine Injury Classification System

A brief explanation of the classification system was presented at the beginning of the survey detailing the kinds of fractures of the subaxial cervical spine listed below along with an illustration of each type of fracture:

- F1. Non-displaced facet fracture; fragment of less than 1 cm and less than 40% of the lateral mass.
- F2. Facet fracture with potential for instability; fragment of >1 cm or >40% of the lateral mass or displaced fragment.
- F3. Floating lateral mass including disruption of the pedicle and lamina resulting in disconnection of the superior and inferior articular process at a given level or set of levels.
- F4. Pathologic subluxation or perched/dislocated facet.

Statistical Analysis

Categorical data was presented as counts and percentages. Surgeons' responses were compared with regard to the kind of facet fractures, age, gender, years of experience, number of spine trauma cases treated yearly, use of the AO Classification System, and the specialty of the surgeon. Comparisons were performed using the Chi-square test or Fisher's exact test as appropriate. The significance level was set at $P < 0.05$. Data was processed and analyzed using SPSS version 25.0 (IBM, Armonk, New York, USA).

Results

A total of 231 members answered the survey questions (23.4% of all members from this Region who received the e-mails) of which 229 fully completed the survey. The responders were from 15 different countries mainly Argentina (20.1%) and Chile (19.7%). The distribution of the surgeons was according to countries and are summarized in Figure 1.

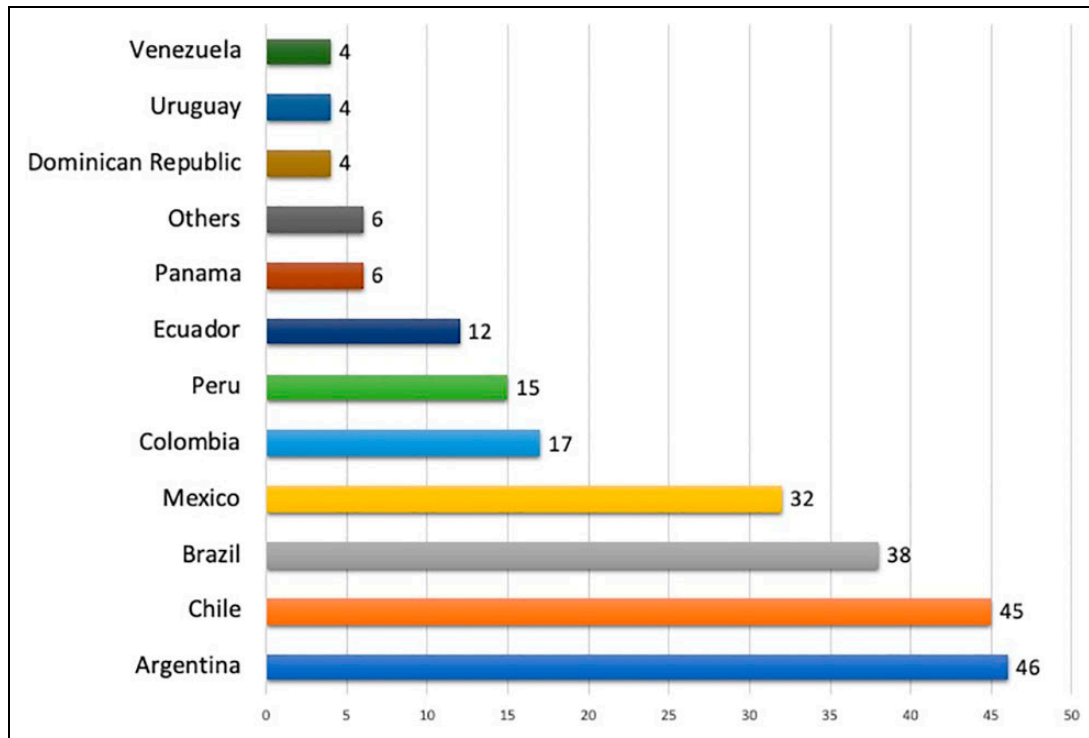


Figure 1. Distribution of participants by country (n = 229).

The mean age of the surgeons was 42.9 ± 10.2 years. Most were men (93.4%), and the distribution according to specialty was 97 (42.4%) neurosurgeons and 132 (57.6%) orthopedic surgeons.

The main hospital practice of each surgeon was in private hospitals (87; 38%), trauma referral centers (25; 10.9%), general hospitals (72; 31.4%), and academic/ university hospitals (45; 19.7%).

Considering the number of years of experience in spine surgery, the mean time was 10.7 ± 8.7 years. The mean number of spine trauma cases treated yearly was 34.1 ± 25.5 cases. The vast majority of the members were found to use the AO Spine Classification System in daily practice (197; 86%).

Specific Radiological Assessment

When asking about the needs of an additional radiological exam to treat facet injuries without a specific clinical scenario, the following answers were obtained:

Type 1 morphology (Table 1)

Most (53.3%) surgeons required an MRI, 9.6% a vascular study, and 43.7% a dynamic cervical lateral x-ray. Surgeons from private hospitals statistically requested more MRIs than those from trauma referral centers or university hospitals ($P = 0.009$); similarly, surgeons who had a lower volume of spine trauma cases (≤ 30 /year) requested more MRIs compared with those with a higher volume (> 30 /year) ($P = 0.003$). Interestingly, neurosurgeons requested more vascular ($P = 0.034$) and dynamic studies ($P = 0.009$) than orthopedic surgeons.

Type 2 morphology (Table 2)

A total of 76% of the surgeons required an MRI; 20.1% had a vascular study, and 50.2% dynamic cervical lateral x-rays. Similar to type 1 injuries, surgeons from private hospitals statistically requested more MRIs than those from trauma referral centers, general hospitals, or university hospitals ($P = 0.011$); surgeons who had a lower volume of spine trauma cases (≤ 30 /year) requested more MRIs compared with those with a higher volume (> 30 /year) ($P = 0.043$). In type 1 injuries, neurosurgeons requested more vascular ($P = 0.001$) and dynamic studies ($P = 0.013$) than orthopedic surgeons.

Type 3 morphology (Table 3)

A total of 94.8% of the surgeons requested an MRI, 66.4% had a vascular study, and 16.6% required dynamic cervical lateral x-rays. MRI exams also were more likely to be requested in private hospitals ($P = 0.023$); neurosurgeons requested vascular studies ($P = 0.001$) and dynamic x-rays ($P = 0.002$) more often when compared with orthopedic surgeons.

Type 4 morphology (Table 4).

A total of 72.5% of the surgeons required an MRI, 86.9% a vascular study, and 16.6% dynamic cervical lateral x-rays. MRIs were more commonly requested in private hospitals ($P < 0.001$) and among surgeons with a lower volume of spine trauma cases (≤ 30 cases/year) ($P = 0.009$). Surgeons with relatively fewer years of experience (≤ 8 years) as well neurosurgeons (when compared with orthopedics) ($P = 0.034$) also requested more vascular studies and dynamic x-rays.

The rate of requesting any modality of a complementary study before treatment was 72.5% for F1, 86.9% for F2, 94.7% for F3, and 96.1% for F4.

Table 1. F1 Facet Injury.

Variable	MRI			Vascular study			Dynamic radiographs		
	Yes	No	P Value	Yes	No	P Value	Yes	No	P Value
Age									
≤40 years	59	60	0.244	13	106	0.482	56	63	0.282
>40 years	63	47		9	101		44	66	
Gender									
Male	116	98	0.286	22	192	0.372*	95	119	0.404
Female	6	9		0	15		5	10	
Specialty									
Neurosurgeon	48	49	0.324	14	83	0.034	52	45	0.009
Orthopedic surgeon	74	58		8	124		48	84	
Complexity of hospital									
Private hospital	56	31	0.009	8	79	0.393	42	45	0.226
Trauma center	7	18		2	23		13	12	
General hospital	38	34		10	62		31	41	
University hospital	21	24		2	43		14	31	
Experience									
≤8 years	61	59	0.437	14	106	0.267	55	65	0.488
>8 years	61	48		8	101		45	64	
Spine trauma cases/year									
≤30	85	54	0.003	15	124	0.450	69	70	0.024
>30	37	53		7	83		31	59	
AO Classification System									
Using in practice	105	92	0.985	19	178	0.962	83	114	0.245
Not using in practice	17	15		3	29		17	15	

(*) Fisher's exact Test. Age, years of experience and number of spine trauma cases/year are divided by the median.

Table 2. F2 Facet Injury.

Variable	MRI			Vascular study			Dynamic radiographs		
	Yes	No	P Value	Yes	No	P Value	Yes	No	P Value
Age									
≤40 years	89	30	0.660	28	91	0.176	60	59	0.949
>40 years	85	25		18	92		55	55	
Gender									
Male	165	49	0.134	45	169	0.315*	109	105	0.413
Female	9	6		1	14		6	9	
Specialty									
Neurosurgeon	77	20	0.302	30	67	0.001	58	39	0.013
Orthopedic surgeon	97	35		16	116		57	75	
Complexity of hospital									
Private hospital	73	14	0.011	17	70	0.765	41	46	0.247
Trauma center	13	12		5	20		12	13	
General hospital	55	17		17	55		43	29	
University hospital	33	12		7	38		19	26	
Experience									
≤8 years	93	27	0.573	31	89	0.023	61	59	0.845
>8 years	81	28		15	94		54	55	
Spine trauma cases/year									
≤30	112	27	0.043	28	111	0.979	74	65	0.256
>30	62	28		18	72		41	49	
AO Classification System									
Using in practice	150	47	0.888	39	158	0.786	98	99	0.723
Not using in practice	24	8		7	25		17	15	

(*) Fisher's exact Test. Age, years of experience and number of spine trauma cases/year are divided by the median.

Table 3. F3 Facet Injury.

Variable	MRI			Vascular study			Dynamic radiographs		
	Yes	No	P Value	Yes	No	P Value	Yes	No	P Value
Age									
≤40 years	104	15	0.394	83	36	0.122	33	86	0.820
>40 years	100	10		66	44		32	78	
Gender									
Male	191	23	0.671*	142	72	0.122	62	152	0.565*
Female	13	2		7	8		3	12	
Specialty									
Neurosurgeon	89	8	0.267	76	21	0.001	38	59	0.002
Orthopedic surgeon	115	17		73	59		27	105	
Complexity of hospital									
Private hospital	83	4	0.023	52	35	0.443	27	60	0.672
Trauma center	22	3		15	10		6	19	
General hospital	64	8		50	22		22	50	
University hospital	35	10		32	13		10	35	
Experience									
≤8 years	108	12	0.641	88	32	0.006	34	86	0.986
>8 years	96	13		61	48		31	78	
Spine trauma cases/year									
≤30	126	13	0.345	93	46	0.468	38	101	0.663
>30	78	12		56	34		27	63	
AO Classification System									
Using in practice	174	23	0.361	123	74	0.038	57	140	0.647
Not using in practice	30	2		26	6		8	24	

(*) Fisher's exact Test. Age, years of experience and number of spine trauma cases/year are divided by the median.

Table 4. F4 Facet Injury.

Variable	MRI			Vascular study			Dynamic radiographs		
	Yes	No	P Value	Yes	No	P Value	Yes	No	P Value
Age									
≤40 years	110	9	0.101	84	35	0.160	25	94	0.062
>40 years	107	3		68	42		13	97	
Gender									
Male	204	10	0.180*	143	71	0.589	34	180	0.283*
Female	13	2		9	6		4	11	
Specialty									
Neurosurgeon	92	5	0.960	74	23	0.006	22	75	0.034
Orthopedic surgeon	125	7		78	54		16	116	
Complexity of hospital									
Private hospital	86	1	0.001	57	30	0.980	15	72	0.509
Trauma center	23	2		16	9		3	22	
General hospital	71	1		49	23		15	57	
University hospital	37	8		30	15		5	40	
Experience									
≤8 years	113	7	0.673	90	30	0.004	25	95	0.070
>8 years	104	5		62	47		13	96	
Spine trauma cases/year									
≤30	136	3	0.009	93	46	0.833	23	116	0.981
>30	81	9		59	31		15	75	
AO Classification System									
Using in practice	187	10	0.782	131	66	0.923	34	163	0.502
Not using in practice	30	2		21	11		4	28	

(*) Fisher's exact Test. Age, years of experience and number of spine trauma cases/year are divided by the median.

Discussion

Very few spine surgeons managed cervical facet injuries with only CT. A growing prevalence of additional radiological exams were requested according to the crescent injury severity (from F1 to F4). Surgeons who work in private centers generally requested cervical MRIs more frequently for almost all types of injuries. Surgeons with a lower volume of cases and surgeons with fewer years of experience also requested more supplementary exams, which may be partially explained by the need for additional information by less experienced surgeons.

The contemporary treatment of unstable cervical spine injuries consists of early surgery when possible and necessary to improve the neurological outcome⁷ and to avoid neurological deterioration. A classification system³ can guide the decision-making in the treatment of these spine injuries and is important for surgeons to standardize their treatments. However, the spectrum of presentations of cervical fractures in real-life may require complementary studies before the final treatment decision. In developing countries, additional radiological evaluation after a CT scan may significantly delay treatment and negatively affect the final outcome. This may be extrapolated to other low-income regions of the world. Another important fact not addressed here is that additional radiological evaluations increase hospital costs—both in terms of the exam and the longer hospitalization time until the final decision is reached on the best treatment option. MRI was the most common additional exam requested and MRI is not cost-effective for further evaluation of unstable injury in neurologically intact patients with blunt trauma after a negative cervical spine CT result.⁸ However, Rathod et al in a recent study including 45 patients with subaxial cervical spine fracture concluded that vertebral artery injury in cervical spine trauma is an underrecognized phenomenon and MRI can be an instrumental low-cost screening tool in resource-deficient parts of the world.⁹ Thus, studies investigating the real need and the impact of further radiological evaluation on patient outcomes in context of facet fracture are necessary.

Regional variations and the varied experiences of surgeons during diagnosis and treatment of cervical facet dislocation injuries have been recently studied by the AO Spine Cervical Classification Validation Group. They found that >50% of the 272 AO spine members across all geographic regions initiate radiological investigation of a cervical facet dislocation with an MRI. There was a participation of 40 spine surgeons from Latin/South America.¹⁰ This current study included a large sample of spine surgeons exclusively from this same region who are AO Spine members. We obtained information regarding diagnosis in each type of facet injury and evaluated other radiological modalities than MRI. In this region, there are significant differences in the treatment of unilateral cervical facet joint dislocation: 65% of the spine surgeons studied considered it mandatory to have an MRI before treatment.¹¹

Here, we analyzed the 3 most common complementary studies ordered by spine surgeons after a documented facet fracture

in the CT scan. Most surgeons requested an additional exam after a CT; the crescent prevalence confirmed the degree of severity ranging from 72.5% in F1 to 96.1% in F4.

MRI Before Treatment

Cervical spine MRI is a useful tool to evaluate spinal injuries. It provides information about the status of the neural elements (such as spinal cord and nerve roots) not clearly visualized by a CT scan as well as information regarding the status of the posterior ligamentous complex without the need for a dynamic exam—this may increase the risk of an iatrogenic spinal cord injury. However, MRI is much more time-consuming than a CT scan and relies on a fully cooperative patient.¹² Intubation is common in severe trauma, and here MRI-compatible ventilators are required, which may be difficult to obtain in low-income centers that do not have full access to the necessary resources.

Requesting an MRI in an isolated and non-displaced facet fracture (such as an F1 or a F2 in a neurologically intact patient) is controversial¹³ because it may not impact the conservative management strategy. Of note, our survey did not inform surgeons of the neurological status of patients. It may have increased the chances of them requesting a complementary exam and is a limitation of our results interpretation. Neurologically intact patients may require fewer radiological exams than severely injured patients, but further studies are needed on this topic. In addition, there is a point of debate in facet dislocation: Neurosurgeons are significantly more likely than orthopedic surgeons to order an MRI before a closed or open reduction. In fact, neurosurgeons ordered an MRI in 76.7% of cases whereas orthopedic surgeons did the same in 57.5% of cases.¹⁴ Our study also reported that neurosurgeons were more likely to request an MRI than orthopedic surgeons during the assessment of facet fractures of the subaxial cervical spine.

There is some validated evidence to support that an MRI in the context of a cervical spine trauma in a non-neurologically intact patients with a F4 facet fracture—regardless of the neurological status of the patient—may lead to a change in the surgical approach (anterior versus posterior) including if a herniated disk is present.¹⁵ However, if the patient has a concomitant traumatic brain injury, then an MRI represents an additional risk despite the potential to rule out cervical injury-instability. The MRI may increase intracranial pressure for supine positioning and may increase the risk of pneumonia due to aspiration during the study.¹⁶

Vascular Study Before Treatment

A potential vertebral artery injury may occur mainly in cervical fractures involving the cervical transverse foramen, facet subluxation, and luxation as well as in upper cervical spine injuries (from the condyles to C2).¹⁷ In the subaxial cervical spine, only F2 and F3 fractures may have a fracture line involving the transverse foramen when (sub)luxation is not

present. Notably, in our survey, spine surgeons requested a vascular study before the decision of treatment in 20.1% of F2 fractures and in 65.1% of the F3 fractures; neurosurgeons requested this exam more frequently. The indication for a vascular study may impose the risk of contrast reaction and additional radiation, which should be considered especially in asymptomatic patients.

We did not assess which modality of vascular study was desirable, which may also limit our results interpretation. In fact, despite the many available modalities, the gold standard exam for vascular injuries was a digital subtraction angiography (DSA).¹⁷ However, CT angiography (CTA) while useful as a screening tool may lead to the unnecessary management of vascular injuries such as anticoagulation therapy due to a higher false positive rate caused by a lower sensitivity than the DSA.¹⁸ Finally, MRI angiography has the advantage of being a non-invasive study with an acceptable sensitivity similar to that of CTA; however, it has a higher cost and requires taking the patient to an MRI room, which may be difficult for severely injured patients.¹⁹

Dynamic Radiographs Before Treatment

Simple plain radiographs have a low sensibility to detect facet fractures versus CT scan images.²⁰ On the other hand, dynamic radiographs may play a role in the assessment of segmental motion instability. Flexion-extension radiographs of the cervical spine can detect the slippage of vertebral bodies or distancing between 2 contiguous spinous processes as well as increase kyphosis suggesting that the instability is not obvious in static exams. Their real usefulness in minor facet fractures is unclear and requires further investigation. Additionally, flexion-extension movements could not demonstrate vertebral instability in a facet fracture where a rotational component is assumed.

Differentiating between F1 and F2 facet fractures is crucial due to the possibility of the patient developing clinical manifestations of instability, chronic pain, and/or deformity. In addition, inter-observer disagreements in diagnosis exist with CT scan images.⁴ On a CT scan, some signs suggest the presence of a F2 fracture instead of a F1 fracture as the pattern of the fracture involving the transverse process or comminution.²¹ Dynamic radiographs may not help in this differentiation despite their potential to identify occult instability.

Segmental instability is considered for most F3²² and F4^{23,24} fractures. Notably, 28.4% of the surgeons of this survey requested dynamic radiographs before the decision of treatment in F3 and 16.6% in F4. In our opinion, dynamic exams may pose an additional risk of spinal cord injury for potentially or clearly unstable injuries. Besides, flexion-extension radiographs cannot demonstrate instability especially in isolated floating lateral masses without displacement. In addition, flexion-extension (dynamic) CT can be performed to diagnose pathological movement of the cervical spine in trauma patients to improve this capability to detect vertebral instability not diagnosed by static CT and MRI.²⁵

Limitations of This Survey

This study has the following limitations. First, it is based on the response rate of our survey (23.4%). Even though 231 is a reasonable sample size, it is not representative of all Latin American spine surgeons. This is a limitation inherent to every survey and may be a source of selection bias. Other limitations may be related to the heterogeneity of responses in different countries making our results difficult to generalize. In fact, there was a significant difference in participation among the countries: this can be a source of bias as countries with less financial support are likely to have a lower possibility of requesting more complementary studies. Finally, important limitations are the study design, the non-availability of clinical data when deciding if prescribing or not supplementary exams, and the diagnosis based on the classification system rather than on the examinations of illustrative cases. In addition, did not consider the neurological status of the patient and the clinical modifiers, which are essential parts of the AO Spine Classification System.

Conclusions

Spine surgeons generally requested additional radiological exams to manage cervical facet injuries. MRI was the most commonly requested additional exam after a CT scan documenting a fracture. Dynamic radiographs were commonly requested for F1 and F2 injuries whereas vascular studies were more common for F3 and F4 morphologies. Spine surgeons from private hospitals and with lower spine trauma cases/year requested MRIs and dynamic radiographs for F1 and F2 injuries more frequently than more experienced surgeons. Surgeons with fewer years of experience also requested more vascular studies in cases of F3 and F4 fractures.

Finally, neurosurgeons requested significantly more vascular studies and dynamic radiographs than orthopedic surgeons before the treatment of all facet fractures. Further studies are needed to understand the specific subgroup of patients who may need additional radiological exams for managing cervical facet fractures.

Acknowledgement

This study was organized by the AO Spine Latin America Trauma Study Group. AO Spine is a clinical division of the AO Foundation, which is an independent medically-guided not-for-profit organization. Study support was provided directly through AO Spine Latin America regarding data collection, data analysis, and proofreading. The authors would like to thank to Iaura Lobo (AO Spine) for her administrative assistance.






Declaration of Conflicting Interests

The author(s) declared no potential conflicts of interest with respect to the research, authorship, and/or publication of this article.

Funding

The author(s) received no financial support for the research, authorship, and/or publication of this article.

ORCID iD

Juan P. Cabrera, MD  <https://orcid.org/0000-0003-4685-6106>
 Ratko Yurac, MD  <https://orcid.org/0000-0003-3603-6294>
 Andrei F. Joaquim, MD, PhD  <https://orcid.org/0000-0003-2645-0483>
 Alfredo Guiroy, MD  <https://orcid.org/0000-0001-9162-6508>
 Charles A. Carazzo, MD, MSc  <https://orcid.org/0000-0001-6339-2214>

References

- Allen BL Jr, Ferguson RL, Lehmann TR, O'Brien RP. A mechanistic classification of closed, indirect fractures and dislocations of the lower cervical spine. *Spine (Phila Pa 1976)*. 1982;7(1):1-27. doi:10.1097/00007632-198200710-00001
- Vaccaro AR, Hulbert RJ, Patel AA, et al. The subaxial cervical spine injury classification system: a novel approach to recognize the importance of morphology, neurology, and integrity of the disco-ligamentous complex. *Spine (Phila Pa 1976)*. 2007;32(21):2365-2374. doi:10.1097/BRS.0b013e3181557b92
- Vaccaro AR, Koerner JD, Radcliff KE, et al. AOSpine subaxial cervical spine injury classification system. *Eur Spine J*. 2016; 25(7):2173-2184. doi:10.1007/s00586-015-3831-3
- Urrutia J, Zamora T, Yurac R, et al. An independent inter- and intraobserver agreement evaluation of the AOSpine subaxial cervical spine injury classification system. *Spine (Phila Pa 1976)*. 2017;42(5):298-303. doi:10.1097/BRS.00000000000001302
- Schnake KJ, Schroeder GD, Vaccaro AR, Oner C. AOSpine classification systems (subaxial, thoracolumbar). *J Orthop Trauma*. 2017;31(9):S14-S23. doi:10.1097/BOT.0000000000000947
- Harrop JS, Sharan AD, Vaccaro AR, Przybylski GJ. The cause of neurologic deterioration after acute cervical spinal cord injury. *Spine (Phila Pa 1976)*. 2001;26(4):340-346. doi:10.1097/00007632-200102150-00008
- Fehlings MG, Vaccaro A, Wilson JR, et al. Early versus delayed decompression for traumatic cervical spinal cord injury: results of the surgical timing in acute spinal cord injury study (STASCIS). *PLoS One*. 2012;7(2):e32037. doi:10.1371/journal.pone.0032037
- Wu X, Malhotra A, Geng B, et al. Cost-effectiveness of magnetic resonance imaging in cervical spine clearance of neurologically intact patients with blunt trauma. *Ann Emerg Med*. 2018;71(1): 64-73. doi:10.1016/j.annemergmed.2017.07.006
- Rathod T, Garje V, Marathe N, et al. Incidence and outcome analysis of vertebral artery injury in posttraumatic cervical spine. *Asian J Neurosurg*. 2020;15(3):644-647. doi:10.4103/ajns.AJNS_45_20
- Canseco JA, Schroeder GD, Patel PD, et al. Regional and experiential differences in surgeon preference for the treatment of cervical facet injuries: a case study survey with the AO spine cervical classification validation group. *Eur Spine J*. 2021;30(2):517-523. doi:10.1007/s00586-020-06535-z
- Joaquim AF, Yurac R, Valacco M, et al. Management of unilateral cervical facet joint dislocation in neurologically-intact patients: results of an AO spine latin American survey. *World Neurosurg*. 2020;S1878-8750(20):32203-32208. doi:10.1016/j.wneu.2020.10.011
- Tins BJ. Imaging investigations in spine trauma: the value of commonly used imaging modalities and emerging imaging modalities. *J Clin Orthop Trauma*. 2017;8(2):107-115. doi:10.1016/j.jcot.2017.06.012
- Botolin S, VanderHeiden TF, Moore EE, Fried H, Stahel PF. The role of pre-reduction MRI in the management of complex cervical spine fracture-dislocations: an ongoing controversy? *Patient Saf Surg*. 2017;11(1):23. doi:10.1186/s13037-017-0139-8
- Grauer JN, Vaccaro AR, Lee JY, et al. The timing and influence of MRI on the management of patients with cervical facet dislocations remains highly variable a survey of members of the spine trauma study group. *J Spinal Disord Tech*. 2009;22(2): 96-99.
- Finger G, Martins A, Cecchini DL, et al. Subaxial spine arthrodesis in patients with spine fractures and facet joint dislocations: is magnetic resonance imaging required to determine the optimal surgical approach? *Surg Neurol Int*. 2019;10:239. doi:10.25259/SNI
- Dunham CM, Brocker BP, Collier BD, Gemmel DJ. Risks associated with magnetic resonance imaging and cervical collar in comatose, blunt trauma patients with negative comprehensive cervical spine computed tomography and no apparent spinal deficit. *Crit Care*. 2008;12(4):1-13. doi:10.1186/cc6957
- Mueller CA, Peters I, Podlogar M, et al. Vertebral artery injuries following cervical spine trauma: a prospective observational study. *Eur Spine J*. 2011;20(12):2202-2209. doi:10.1007/s00586-011-1887-2
- Fourman MS, Shaw JD, Vaudreuil NJ, et al. Cervical spine fractures: who really needs CT angiography? *Spine (Phila Pa 1976)*. 2019;44(23):1661-1667. doi:10.1097/BRS.00000000000003163
- Harrigan MR, Hadley MN, Dhall SS, et al. Management of vertebral artery injuries following non-penetrating cervical trauma. *Neurosurgery*. 2013;72(suppl.2):234-243. doi:10.1227/NEU.0b013e31827765f5
- van Middendorp JJ, Cheung I, Dalzell K, et al. Detecting facet joint and lateral mass injuries of the subaxial cervical spine in major trauma patients. *Asian Spine J*. 2015;9(3):327-337. doi:10.4184/asj.2015.9.3.327
- Jenjitrant P, Beckmann NM, Cai C, Cheekatla SK, West OC. There has to be an easier way: facet fracture characteristics that reliably differentiate AOSpine F1 and F2 injuries. *Emerg Radiol*. 2019;26(4):391-399. doi:10.1007/s10140-019-01684-1
- Manoso MW, Moore TA, Agel J, Bellabarba C, Bransford RJ. Floating lateral mass fractures of the cervical spine. *Spine (Phila Pa 1976)*. 2016;41(18):1421-1427. doi:10.1097/BRS.00000000000001536

23. Schleicher P, Kobbe P, Kandziora F, et al. Treatment of injuries to the subaxial cervical spine: recommendations of the spine section of the German society for orthopaedics and trauma (DGOU). *Glob Spine J*. 2018;8(2_suppl):25S-33S. doi:10.1177/2192568217745062
24. Lins CC, Prado DT, Joaquim AF. Surgical treatment of traumatic cervical facet dislocation: anterior, posterior or combined approaches? *Arq Neuropsiquiatr*. 2016;74(9):745-749. doi:10.1590/0004-282X20160078
25. Wadhwa R, Shamieh S, Haydel J, Caldito G, Williams M, Nanda A. The role of flexion and extension computed tomography with reconstruction in clearing the cervical spine in trauma patients: a pilot study. *J Neurosurg Spine*. 2011;14(3):341-347. doi:10.3171/2010.11.SPINE09870