


# Solitary pigmented lesions in oral mucosa in Latin American children: A case series

Gina Pennacchiotti DDS, MSc<sup>1</sup> | Carlos Oviedo DDS<sup>2</sup> |  
Ana Ortega-Pinto DDS, MSc<sup>1</sup> 

<sup>1</sup>Department of Pathology and Oral Medicine, School of Dentistry, Oral Medicine Clinic, Universidad de Chile, Santiago, Chile

<sup>2</sup>Public Dental Service, Dental Center of Development Corporation, Universidad del Desarrollo, La Reina, Chile

## Correspondence

Ana Ortega-Pinto, DDS MSc, Department of Pathology and Oral Medicine, School of Dentistry, Oral Pathology, Universidad de Chile, Santiago, Chile.  
Email: aortega@odontologia.uchile.cl

## Abstract

**Background:** A variety of local and systemic processes caused exogenous and endogenous pigmentation of the oral mucosa. Solitary melanotic pigmentation is rare, hence the scarce number of studies in children and adolescents.

**Methods:** Clinical and histopathologic features of 10 Latin American children with solitary pigmented lesions of the oral mucosa were reviewed.

**Results:** The area most affected was the gingiva, followed by the palate. All lesions were flat and <1 cm in diameter. A brown color was observed in oral melanocytic macules and nevi. The exogenously pigmented lesion was bluish gray. Histopathology showed that the biopsied lesions corresponded to melanotic macules, junctional nevus, blue nevus, and exogenous pigmentation.

**Conclusion:** Solitary pigmented lesions on the oral mucosa of children, from melanin pigment or exogenous pigment, may have a similar clinical presentation, but melanotic lesions such as oral melanotic macules and nevi can be differentiated from one another only with histopathologic examination.

## KEYWORDS

melanotic macule, nevus, oral mucosa, pediatric, pigmented lesions

## 1 | INTRODUCTION

Solitary oral pigmented lesions can have an exogenous or endogenous origin. Implantation of a foreign body in the mucosa produces exogenous lesions. Melanin, hemoglobin, hemosiderin, and carotenes cause endogenous pigmented lesions.<sup>1</sup> Melanocytes in the stratum basale of the epithelium produce melanin, which is transferred to the keratinocytes in organelles called melanosomes. Nevus cells, which can be found in the skin and mucosa, also synthesize melanin. Pigmented lesions caused by an increase in melanin deposits may be brown, blue, gray, or black, depending, on the quantity and location of melanin in the tissues.<sup>2</sup>

Solitary melanocytic pigmented lesions on the oral mucosa are infrequent, representing only 0.9% of cases evaluated in oral and maxillofacial pathology services. Most affected individuals are in their 30s or 40s.<sup>3</sup> There are few studies of melanotic pigmentation of the oral mucosa of children and adolescents. In 2004, Bessa et al<sup>4</sup>

determined the prevalence of alterations in oral mucosa of children aged 0-12 in Brazil, with the melanotic macule being the third most prevalent lesion.<sup>4</sup> Shulman, in 2005, examined 10 032 children in the United States aged 2-17 to determine the prevalence of lesions. The most prevalent lesions were from lip or cheek bite (1.89%), followed by recurrent aphthous ulcerations (1.64%) and nevi (1.54%).<sup>5</sup>

This article describes the clinical and histopathologic characteristics of solitary pigmented lesions of 10 Latin American children.

## 2 | MATERIALS AND METHODS

We present 10 cases of Latin American children aged 4-12 who presented with solitary pigmented lesions of the oral mucosa to the Dental School of the Universidad de Chile or Universidad del Desarrollo. Sociodemographic data, systemic disease, medications, oral habits, previous dental treatment, and description of the pigmented

**TABLE 1** Clinical and histopathologic characteristics of cases

Patient	Sex	Age	Location	Clinical aspect	Size, mm	Diagnosis
1	Female	4	Hard palate	Flat, brown	4	Junctional nevus
2	Male	7	Mandibular gingiva	Flat, delimited, brown	3	Melanotic macule
3	Female	6	Maxillary gingiva	Flat, delimited, brown	1	Melanotic macule
4	Male	12	Maxillary gingiva	Flat, delimited, brown	2	Melanotic macule
5	Female	5	Hard palate	Flat, delimited, brown	2	Melanotic macule
6	Female	12	Retromolar zone	Flat, delimited, brown	3	Melanotic macule
7	Male	12	Inferior lip	Flat, delimited, brown	3	Melanotic macule <sup>a</sup>
8	Male	6	Mandibular gingiva	Flat, blurred limit, dark brown	8	Blue nevus
9	Female	12	Hard palate	Flat, delimited, greyish blue	4	Exogenous pigmentation
10	Male	8	Hard palate	Flat, delimited, dark brown	5	Melanotic macule or nevus <sup>a</sup>

<sup>a</sup>Clinical diagnosis, no biopsy was taken. Follow-up for two years.

oral mucosa of the patients were registered. Some of the parents asked for a histopathologic study of the lesions, whereas others declined biopsy, relying on clinical diagnosis and observation. All parents or guardians signed informed consent that the ethics committees of the faculties approved. This study meets the requirements established by the World Medical Association in the Helsinki Declaration in relation with ethical principles for medical investigation.

The children were examined every 6 months during the 2-year study period.

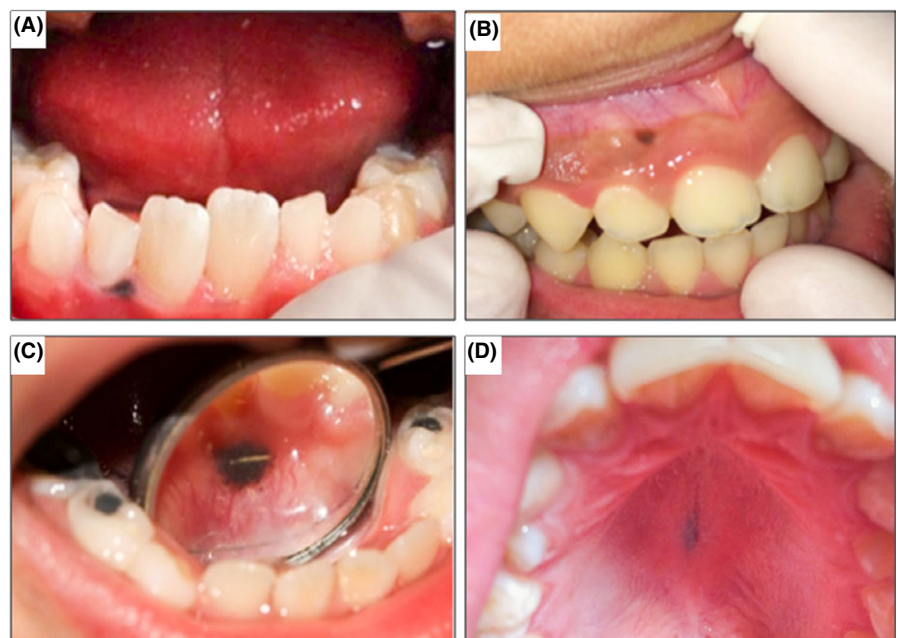
### 3 | RESULTS

Pigmented oral lesions affected girls and boys equally. The median age of presentation was 8.5 years (range 4–12 years). The area most affected was the gingiva, followed by the palate. All lesions were flat and measured <1 cm in diameter. The most extensive lesion

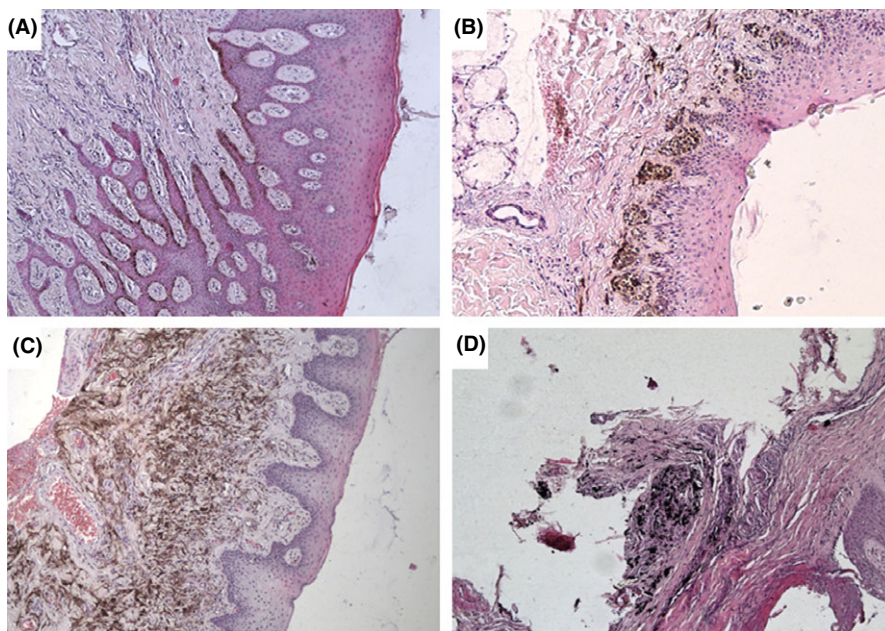
measured 0.8 cm, had diffuse borders that corresponded to a blue nevus (Table 1 and Figure 1C). Oral melanocytic macules and nevi were dark brown, and melanocytic macules were light brown (Figure 1A–C). The exogenous pigment lesion was bluish grey (Figure 1D). Histopathologic examination showed that the most frequently observed lesions were oral melanotic macules (Figure 2A) with one case each of junctional nevus (Figure 2B), blue nevus (Figure 2C), and exogenous pigmentation (Figure 2D).

### 4 | DISCUSSION

There are few reports of solitary pigmented lesions of the oral mucosa of children and adolescents, so it is difficult to determine their frequency, and there are not guidelines as to when a biopsy is indicated. According to a study by Buchner that included biopsies of oral lesions of patients of all ages, of the 89 430 biopsies that were



**FIGURE 1** Clinical photographs of oral pigmented lesions in Latin American children. A, Melanotic macule: small, well-defined, dark-brown, gingival macule. B, Melanotic macule and racial (physiological) gingival pigmentation. C, Blue nevus: dark brown pigmented macule on lingual attached gingiva with smaller pigmented satellites. D, Exogenous pigmentation: blue-gray pigmented macule on hard palate



**FIGURE 2** Histopathologic characteristics of oral pigmented lesions. A, Melanotic macule: oral mucosa with high melanin pigment in basal layer of epithelium. B, Junctional nevus: nevus cells organized in nests at the dermal-epidermal junction of the oral mucosa (Case 1). C, Blue nevus: oral mucosa with multiple elongated cells with abundant melanin pigment located in submucosal tissue (case 8). D, Exogenous pigmentation: oral mucosa showing an exogenous black material located in the fibrous connective tissue (Case 9). Original magnification  $\times 10$ . Hematoxylin and eosin stain

accessed during the 19-year period, 773 (0.83%) cases of solitary pigmented melanocytic lesions in the oral mucosa were identified, at a mean age of 43.7 (range 4-98).<sup>3</sup>

In Buchner's study, oral melanotic macules of the gingiva were most frequent. In people younger than 20, they observed only melanotic oral macules and nevi and no cases of melanoacanthomas or melanomas.<sup>3</sup> Kaugars et al<sup>6</sup> observed that pigmented lesions located on the inferior lip and gingiva presented at a lower average age than those located in other places in the oral cavity. In the work of Carlos et al<sup>7</sup>, four oral melanocytic macules were presented, two in 8-year-olds, both with lesions located on the gingiva.

With regard to oral nevi in children, we observed junctional nevi and blue nevi, these types of nevi have been reported with more frequency in young people.<sup>3,8</sup> Buchner et al<sup>3</sup>, in their 773 cases of solitary melanocytic lesions, found three cases of junctional nevus in children age 7-14. Meletti et al<sup>9</sup> reported five cases of junctional nevus out of 119 oral mucosa nevi (4.2% of the total), which presented between the ages of 7 and 52. Ferreira et al<sup>8</sup>, in their 100 cases of oral mucosa nevus reported 3 junctional nevi, with an average age of 6 years.

Blue nevi on oral mucosa seem to be more frequent than junctional nevi and have a wider age range. Buchner et al<sup>3</sup>, from a total of 773 cases of unique pigmented lesions, found that 15 (16.5%) cases corresponded to blue nevi, of which only 2 were diagnosed in patients aged 10-19. Meletti et al<sup>9</sup> reported 10 cases from a total of 119 cases; none of these cases were observed in people younger than 29. Ferreira et al<sup>8</sup> found 23 cases of common blue nevus out of a total of 100 nevus of oral mucosa, of which only 1 case was aged 10-19.

Other melanocytic lesions in the oral mucosa of children, which are extremely uncommon, are melanoacanthomas, congenital nevi, and melanomas.<sup>7,10,11</sup> The melanoacanthoma of a 7-year-old boy that Carlos-Bregni reported and the melanoma of a 3-month-old

child that Owens described were pigmented lesions <1 cm in diameter with clinical characteristics similar to those of the lesions observed in the children in our report.<sup>7,11</sup> The melanoma in the infant was not aggressive. The congenital nevus that Maragon reported was an extensive lesion approximately 5 by 4 cm made up of multiple papules. Some papules had a color similar to that of normal mucosa, and others had scattered brown to black areas. There were no major clinical changes in 11 years of follow-up.<sup>10</sup>

Another oral pigmented lesion in children is the melanotic neuroectodermal tumor of infancy (MNTI), an uncommon neoplasm that normally affects children during the first months of life. MNTI can present as bluish-black masses of fast growth usually located in the anterior region of the maxilla and can be aggressive.<sup>12</sup>

Exogenous pigmentation is one of the most common causes of intraoral pigmentation. It clinically presents as a localized flat lesion, grayish-blue in color (Figure 1D). In some cases, especially when there are large amalgam particles, radiopaque granules can be seen on a radiograph. Graphite can be introduced in the oral mucosa through an accidental tattoo caused by a pencil. This lesion occurs more frequently in the anterior palate than in other locations in young children.<sup>13</sup>

With such limited information in children, there are no guidelines to determine when a biopsy is indicated. Criteria for biopsy of a solitary pigmented lesion on the oral mucosa are different from those for a lesion on the skin. Analyzing asymmetry, borders, color, and diameter is useful to determine whether a skin lesion should be biopsied, but on mucosa these criteria would identify only an advanced malignant lesion.<sup>2</sup> For solitary oral pigmented lesions that cannot be explained by exogenous pigmentation, biopsy is necessary.<sup>1</sup> For children and adolescents with solitary pigmented lesions on the oral mucosa, there are no specific criteria to indicate the need for biopsy. Although oral melanomas in children are

uncommon, serial clinical observation or biopsy would be advisable until there is more information reported on pigmented oral lesions in the first decades of life.

## 5 | CONCLUSION

All the pigmented lesions observed in the oral mucosa of these children were flat, <9 mm in diameter, brown or grayish-blue, and asymptomatic. The limits were well demarcated in most, but the blue nevus had blurred borders. In all cases, the histopathologic diagnosis was a benign lesion that could correspond to a melanotic macule, junctional nevus, blue nevus, or exogenous pigmentation.

The prevalence of pigmented oral lesions in adults is different from in children. Studies conducted in adults have limited applicability in children. Further studies of the frequency, types of lesions, and clinical features distinguishing benign from malignant lesions are needed.

## ACKNOWLEDGMENTS

We are grateful to the members of the families for their participation in the study. We thank Andrea Maturana for her assistance with the biopsies.

## ORCID

Ana Ortega-Pinto  <http://orcid.org/0000-0002-8405-799X>

## REFERENCES

1. Kauzman A, Pavone M, Blanas N, Bradley G. Pigmented lesions of the oral cavity: review, differential diagnosis, and case presentations. *J Can Dent Assoc.* 2004;70:682-683.
2. Elisen D. Disorders of pigmentation in the oral cavity. *Clin Dermatol.* 2000;18:579-587.
3. Buchner A, Merrell PW, Carpenter WM. Relative frequency of solitary melanocytic lesions of the oral mucosa. *J Oral Pathol Med.* 2004;33:550-557.
4. Bessa CFN, Santos PJB, Aguiar MCF, do Carmo MAV. Prevalence of oral mucosal alterations in children from 0 to 12 years old. *J Oral Pathol Med.* 2004;33:17-22.
5. Shulman JD. Prevalence of oral mucosal lesions in children and youths in the USA. *Int J Pediatr Dent.* 2005;15:89-97.
6. Kaugars GE, Heise AP, Riley WT, Avvey LM, Svirsky JA. Oral melanotic macules: a review of 353 cases. *Oral Surg Oral Med Oral Pathol.* 1993;76:59-61.
7. Carlos-Bregni R, Contreras E, Netto AC, et al. Oral melanoacanthoma and oral melanotic macule: a report of 8 cases, review of the literature, and immunohistochemical analysis. *Med Oral Patol Oral Cir Bucal.* 2007;12:E374-E379.
8. Ferreira L, Jham B, Assi R, Readinger A, Kessler HP. Oral melanocytic nevi: a clinicopathologic study of 100 cases. *Oral Surg Oral Med Oral Pathol Oral Radiol.* 2015;120:358-367.
9. Meleti M, Mooi W, Casparie M, Van der Waal I. Melanocytic nevi of the oral mucosa—no evidence of increased risk for oral malignant melanoma: an analysis of 119 cases. *Oral Oncol.* 2007;43:976-981.
10. Marangon Júnior H, Souza PE, Soares RV, de Andrade BA, de Almeida OP, Horta MC. Oral congenital melanocytic nevus: a rare case report and review of the literature. *Head Neck Pathol.* 2015;9:481-487.
11. Owens JM, Gomez JA, Byers RM. Malignant melanoma in the palate of a 3-month-old child. *Head Neck.* 2002;24:91-94.
12. Magliocca KR, Pfeifle RM, Bhattacharyya I, Cohen DM. Melanotic neuroectodermal tumor of infancy. *Pediatr Dermatol.* 2012;29:633-636.
13. Owens BM, Johnson WW, Schuman NJ. Oral amalgam pigmentations (tattoos): a retrospective study. *Quintessence Int.* 1992;23:805-810.

**How to cite this article:** Pennacchiotti G, Oviedo C, Ortega-Pinto A. Solitary pigmented lesions in oral mucosa in Latin American children: Case series report. *Pediatr Dermatol.* 2018;35:374–377. <https://doi.org/10.1111/pde.13465>