



Hantavirus in humans: a review of clinical aspects and management

Pablo A Vial, Marcela Ferrés, Cecilia Vial, Jonas Klingström, Clas Ahlm, René López, Nicole Le Corre, Gregory J Mertz

Hantavirus infections are part of the broad group of viral haemorrhagic fevers. They are also recognised as a distinct model of an emergent zoonotic infection with a global distribution. Many factors influence their epidemiology and transmission, such as climate, environment, social development, ecology of rodent hosts, and human behaviour in endemic regions. Transmission to humans occurs by exposure to infected rodents in endemic areas; however, Andes hantavirus is unique in that it can be transmitted from person to person. As hantaviruses target endothelial cells, they can affect diverse organ systems; increased vascular permeability is central to pathogenesis. The main clinical syndromes associated with hantaviruses are haemorrhagic fever with renal syndrome (HFRS), which is endemic in Europe and Asia, and hantavirus cardiopulmonary syndrome (HCPS), which is endemic in the Americas. HCPS and HFRS are separate clinical entities, but they share several features and have many overlapping symptoms, signs, and pathogenic alterations. For HCPS in particular, clinical outcomes are highly associated with early clinical suspicion, access to rapid diagnostic testing or algorithms for presumptive diagnosis, and prompt transfer to a facility with critical care units. No specific effective antiviral treatment is available.

Introduction

Hantaviruses are zoonotic viruses with a nearly global distribution. The viruses cause two severe diseases in humans: haemorrhagic fever with renal syndrome (HFRS) in Europe and Asia, and hantavirus cardiopulmonary syndrome (HCPS), also called hantavirus pulmonary syndrome, in the Americas. Although HFRS and HCPS are recognised as distinct clinical entities, there are overlapping symptoms, signs, and pathogenic alterations.

Hantaan virus (HTNV) was discovered in 1976,^{1,2} and then several other hantaviruses have been identified throughout Europe and Asia. In 1993, a previously unrecognised syndrome (HCPS) characterised by respiratory failure and cardiogenic shock was reported in the southwest of the USA, leading to the discovery of a genetically distinct hantavirus later named Sin Nombre virus (SNV).³ Since then, many HCPS-causing hantaviruses have been identified in the Americas.⁴ Novel hantavirus species have also been reported in Africa, but evidence of human infection is limited to seroprevalence studies and case reports.⁵

Hantaviruses and their hosts

Hantaviruses belong to the *Orthohantavirus* genus, family *Hantaviridae*, order *Bunyavirales*.⁶ Viral particles are enveloped, 80–120 nm in diameter, and have a negative strand RNA genome with three segments: small (S), medium (M), and large (L). The S segment encodes the nucleocapsid protein, the M segment encodes the envelope glycoproteins (Gn and Gc), and the L segment encodes the viral RNA-dependent RNA polymerase.^{6,7}

Rodents are the main natural hosts for HFRS-causing and HCPS-causing hantaviruses, although bats, moles, shrews, reptiles, and fish have also been shown to carry hantaviruses.^{4,6} Natural hosts are believed to be

persistently infected with little biological effect. Rodents excrete hantaviruses in saliva, urine, and faeces, and humans are infected when inhaling the secreted viruses, or rarely by rodent bites (figure 1). Dynamics of rodent populations and other factors such as rainfall, temperature, land use and habitat changes, social development, and human behaviour influence the interaction between the rodent hosts and humans.^{4,7–9}

Data are insufficient on how long hantaviruses remain viable in the environment. Puumala virus (PUUV) remained infectious for up to 15 days in bank voles' bedding, and remained viable at room temperature after 5 days in a wet environment, and 24 h when dry.¹⁰ Similarly, HTNV survived in wet conditions for 8 days at 20°C, and 9 days at 37°C.¹¹

Endothelial cells of capillaries and small vessels are the principal targets of hantaviruses, and increased vascular permeability is central to pathogenesis.⁴ Increased permeability does not appear to be caused by a lytic effect of the virus, but rather by functional changes of the endothelial barrier by mechanisms that remain poorly understood. It could be triggered by binding of the virus to cell receptors that regulate endothelial permeability, increased innate immune responses, and immunopathogenic mechanisms, including inflammatory responses.^{12–14}

In HFRS, endothelial activation leads to platelet activation and altered coagulation.^{15,16} Endothelial cells in the lungs, kidneys, heart, liver, and spleen are infected and macrophages, mononuclear blood cells, dendritic cells, and respiratory and tubular epithelium can also be infected. According to histopathological studies, HFRS-causing hantaviruses primarily affect renal medulla capillaries, whereas HCPS-causing hantaviruses mainly affect pulmonary capillaries.¹³ However, the differences in clinical expression, severity, specific organ dysfunction, and the process behind the development of HFRS and HCPS remain mostly unexplained.

Lancet Infect Dis 2023

Published Online

April 24, 2023

[https://doi.org/10.1016/S1473-3099\(23\)00128-7](https://doi.org/10.1016/S1473-3099(23)00128-7)

S1473-3099(23)00128-7

Programa Hantavirus y Zoonosis, Instituto de Ciencias e Innovación en Medicina

(Prof P A Vial MD, C Vial PhD), Facultad de Medicina

(R López MD), Clínica Alemana

Universidad del Desarrollo,

Santiago, Chile; Departamento

de Pediatría Clínica Alemana de

Santiago, Santiago, Chile

(P A Vial); Department of

Pediatric Infectious Disease

and Immunology, Infectious

Disease and Molecular Virology

Laboratory, Facultad de

Medicina, Pontificia

Universidad Católica de Chile,

Santiago, Chile

(Prof M Ferrés MD,

N Le Corre MD); Division of

Molecular Medicine and

Virology, Department of

Biomedical and Clinical

Sciences, Linköping University,

Linköping, Sweden

(Prof J Klingström PhD); Center

for Infectious Medicine,

Department of Medicine

Huddinge, Karolinska

Institutet, Stockholm, Sweden

(J Klingström); Department of

Clinical Microbiology, Umeå

University, Umeå, Sweden

(Prof C Ahlm MD);

Departamento de Paciente

Crítico Clínica Alemana,

Santiago, Chile (R López);

Department of Internal

Medicine, UNM Health Sciences

Center, University of New

Mexico, Albuquerque, NM, USA

(Prof G J Mertz MD)

Correspondence to:

Dr Pablo A Vial, Programa

Hantavirus y Zoonosis, Instituto

de Ciencias e Innovación en

Medicina, Facultad de Medicina,

Clínica Alemana Universidad del

Desarrollo, Santiago, 7610658,

Chile

pvial@udd.cl

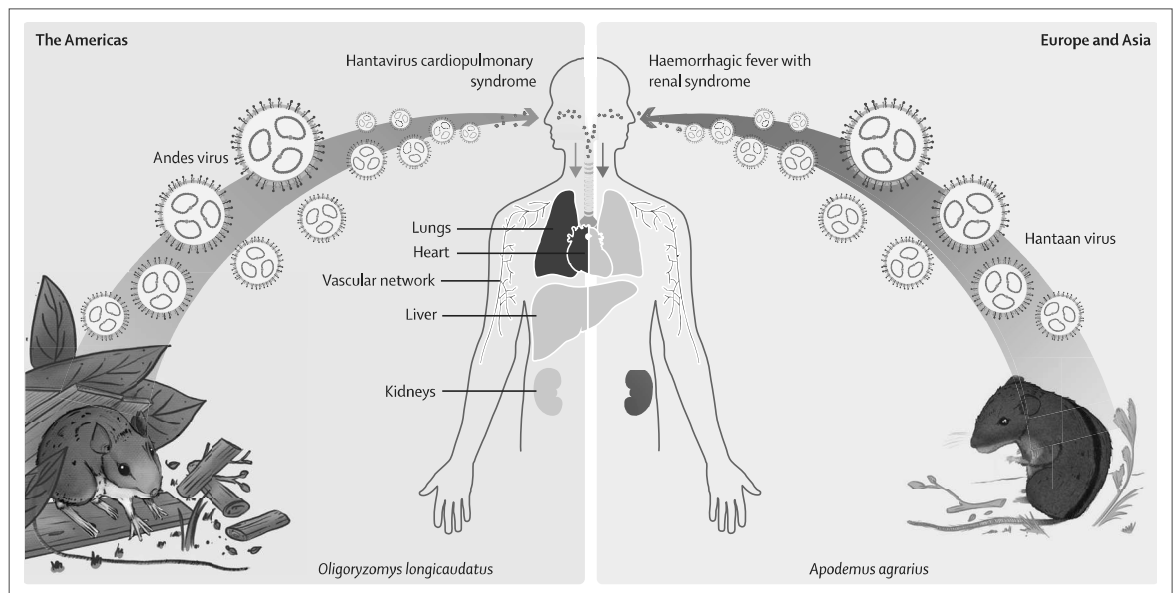


Figure 1: Hantavirus transmission from rodents to humans

Transmission mainly occurs via inhalation of aerosolised viral particles shed in rodent urine, faeces, and saliva. Organ and organ system involvement differs in magnitude according to the infecting virus. Andes virus, Hantaan virus, and their rodent host species shown in the figure are representative of pathogenic hantaviruses and rodent hosts present throughout the Americas, Europe, and Asia.

Hantavirus in Europe and Asia

HFRS-causing hantaviruses include HTNV, Dobrava virus (DOBV), PUUV, and Seoul virus (SEOV).⁴ Tula virus has also been shown to cause disease in a few cases.^{17,18} PUUV infection was originally named nephropathia epidemica, and the term is still in use. The distribution of these viruses overlaps with the geographical distribution of their rodent reservoirs. We have listed the rodents associated with hantaviruses pathogenic in humans in Europe and Asia (table).^{4,8,29,30} HFRS cases due to SEOV have been reported worldwide.³¹ Most SEOV infections in humans, including those acquired from laboratory or pet rats, appear to be asymptomatic or cause a mild illness that remains undiagnosed.^{32,33}

HFRS and HCPS are reportable diseases in most countries, but reports largely reflect hospital admissions. The overall level of infection and the clinical presentation, if any, is difficult to assess as many infections are not identified. From serosurveillance studies in Finland, only around 15% of infected people are diagnosed and reported.¹⁹ Seropositive individuals have been identified in areas without known pathogenic hantaviruses,^{34,35} meaning these individuals might have been infected during travel, or by unrecognised local viruses. Tracing the place of infection can sometimes be difficult, as the incubation period can be up to 6 weeks.³⁶ There is no evidence for human-to-human transmission of HFRS-causing hantaviruses, although blood products drawn from infected individuals, or blood transmission during medical interventions are a possible source of infection.³⁷ No HCPS-causing hantavirus circulates in Europe and

Asia, but cases have been diagnosed in travellers returning from the Americas.³⁸

HTNV is responsible for most cases of hantavirus in China and South Korea, where case numbers vary with natural cycles, and where SEOV also circulates. A mean of 12 800 HFRS cases (median 11 063; range 8853–25 041) per year was reported in China from 2004 to 2016, with a case fatality rate (CFR) of 1.3% and a decline in incidence over time.³⁹ South Korea has reported 300–600 cases per year for the past 20 years (figure 2), and the CFR has decreased from 5% to 7% in the 1950s, to 1% from 2011 to 2016.^{40,42} The proportion of cases caused by SEOV in these two countries is unclear.

In the European Union, where a mean of 3100 HFRS cases (median 2897; range 1831–4249) are reported per year: Finland reported 43%, Germany 30%, and Sweden 6% of all cases.⁴³ CFR is reported to be 0.1% in Finland,¹⁹ less than 0.03% in Germany,⁴⁴ and 0.4% in Sweden,⁴⁵ and in the Balkans and southeast Europe, most cases are caused by DOBV, a more severe form of HFRS with a CFR from 10% to 12%, although genotypes with varying virulence have been recognised.²⁰ DOBV has also been reported in central Europe, including in Germany, Poland, Lithuania, and Czech Republic. In Russia, PUUV, two species of DOBV (Sochi virus [SOCV] and Kurkino virus), HTNV, Amur virus, and SEOV exist. Approximately 7300 HFRS cases per year are reported in Russia (figure 2), with an overall CFR of 0.4%.^{21,22} PUUV is responsible for almost all HFRS cases diagnosed in western Russia.

Most HFRS cases occur globally in rural settings (with the exception of SEOV that is mainly transmitted in urban settings) in farmers, military troops, and other

people who spend extended time outdoors. Smoking was reported as a risk factor for contracting PUUV infection^{46,47} and for more severe disease.⁴⁸ The male-to-female ratio for HFRS cases is 2·6:1. In contrast to HFRS cases, SEOV cases are mainly seen in urban settings, where wild rats are prevalent.

Hantavirus in the Americas

Overall, 300 cases of HCPS are diagnosed per year in the Americas (figure 2), mainly in Argentina, Brazil, and Chile. HCPS is acquired in rural settings by residents (80%) or visitors (20%) of endemic areas. Overall, the median age for people with HCPS is 34 years (range 0–86 years), and 70–80% of cases occur in men. Risk factors include forestry or agricultural work, weeding, construction, demolition, cleaning previously unused homes, and actions that raise dust in cellars, storage areas, or stables.^{8,23,49–51} The most severe forms of HCPS are associated with SNV, ANDV, Araraquara virus, and Juquitiba virus, all with CFRs between 30% and 45%. Choclo virus (CHOV) and Laguna Negra virus (LANV) have a CFR between 12% and 15% (table).^{8,24} In addition to CHOV in Panama, there is serological evidence of hantavirus infection in rodents and humans in other Central American and Caribbean countries, but descriptions of the clinical course are scarce.^{9,52,53}

Of note is an inverse correlation of seroprevalence rates and disease severity in humans. In the USA, Chile, and Argentina where the disease is severe, seroprevalence is low (0·1–2·2%).^{54,55} By contrast, in Paraguay and Panama, where HCPS is milder, 17–40%⁵⁶ and 33%,⁵⁷ respectively are seropositive. Thus, some populations have substantially higher exposure and infection rates and a lower susceptibility to clinical disease—an occurrence that could be related to genetic selection of the population, or more transmissible and less pathogenic viruses.

Person-to-person transmission of ANDV has been documented in Argentina and Chile.^{58–63} In 2018–19, a person-to-person transmission outbreak affected 34 patients in Argentina, 11 of whom died.⁵⁹ A prospective study in Chile followed 476 household contacts of 76 confirmed ANDV cases for 5 weeks, and found 16 additional patients with a secondary attack rate of 3·4%. The risk of infection was 17·6% among sex partners of an index case, compared with 1·2% for other household contacts.⁵⁸ Rare nosocomial transmission has also been reported.^{62,63} Based on these reports, risk factors for person-to-person transmission could include being a sexual partner, tongue kissing, and sleeping in the same room largely just before or during the febrile prodrome. In addition, attending a social gathering with a symptomatic person was identified as a risk factor in the 2018–19 Argentina outbreak.⁵⁹ ANDV has been detected in saliva from rodents and humans,^{64,65} and is more resistant to inactivation by saliva than PUUV or HTNV.⁶⁶ Ethnicity has been shown to affect the clinical course of ANDV and

	Rodent host	Syndrome	Case fatality rate (%)	Country
The Americas				
Sin Nombre virus	<i>Peromyscus maniculatus</i>	HCPS	35%	USA, Canada
Andes virus	<i>Oligoryzomys longicaudatus</i>	HCPS	21·4–35·9%	Argentina, Chile
Araraquara virus	<i>Bolomys lasiurus</i>	HCPS	44·5%	Brazil
Choclo virus	<i>Oligoryzomys fulvescens</i>	Fever, HCPS	12–15%	Panama
Laguna Negra virus	<i>Calomys laucha</i> , <i>Calomys callosus</i>	Fever, HCPS	11·7%	Paraguay, Argentina, Bolivia, Peru
Juquitiba virus	<i>Oligoryzomys nigripes</i>	HCPS	32·5%	Brazil
Europe and Asia				
Hantaan virus	<i>Apodemus agrarius</i>	HFRS	1%	China
Puumala virus	<i>Myodes glareolus</i>	HFRS (NE)	0·1–0·4%	Finland, Sweden, Belgium, Germany, France, Russia, northeast Europe
Dobrava virus	<i>Apodemus flavicollis</i> , <i>Apodemus ponticus</i>	HFRS	9·8–12·0%	Balkans, southeast Europe
Seoul virus	<i>Rattus norvegicus</i>	HFRS	<1%	Worldwide
Tula virus	<i>Microtus arvalis</i>	HFRS	..	Russia, Europe
All information was obtained from several sources. ^{8,19–26} HCPS=hantavirus cardiopulmonary syndrome. HFRS=haemorrhagic fever with renal syndrome. NE=nephropathia epidemica.				
Table: Common or important hantaviruses causing disease in the Americas, and Europe and Asia				

LANV infection,^{56,67} so human genetic composition can influence the severity of hantavirus infections.^{7,68}

Based on two reports in which infection was known to have been acquired during brief exposures in endemic areas, such as 2–3 day visits to Curry Village in the Yosemite National Park (CA, USA) in 2012, and short visits to endemic areas in Chile, the incubation for SNV and ANDV is long, ranging between 7 days and 49 days, with a median of 30 days and 18 days,^{69,70} respectively. For person-to-person transmission, estimates of incubation periods range between 9 days and 40 days, with a median of 19 days⁵⁸ and 23 days,⁵⁹ respectively.

HCPS cases occur mainly in spring and summer; however, the incidence and locations where rodent populations surge and outbreaks occur vary yearly. In Chile, abrupt, localised increases in *Oligoryzomys longicaudatus* populations, known as ratadas, follow blooming and seeding of bamboo species, leading to increased ANDV infections in rodents and humans.⁷¹

Clinical presentation

HCPS and HFRS are separate entities, but the syndromes share several features (figures 1, 3). Firstly, both are characterised by strong inflammation, affect the vascular endothelial cells, and behave like a systemic disease. Secondly, both HCPS and HFRS can lead to renal failure. Finally, virtually all patients with HCPS and more than half of patients with HFRS have respiratory symptoms, such as hypoxia, and radiological findings on chest x-rays or CT scans.^{29,49,72,73}

For HFRS, increased vascular permeability, coagulation dysregulation, and acute kidney injury are typical features. The infection has classically been divided into

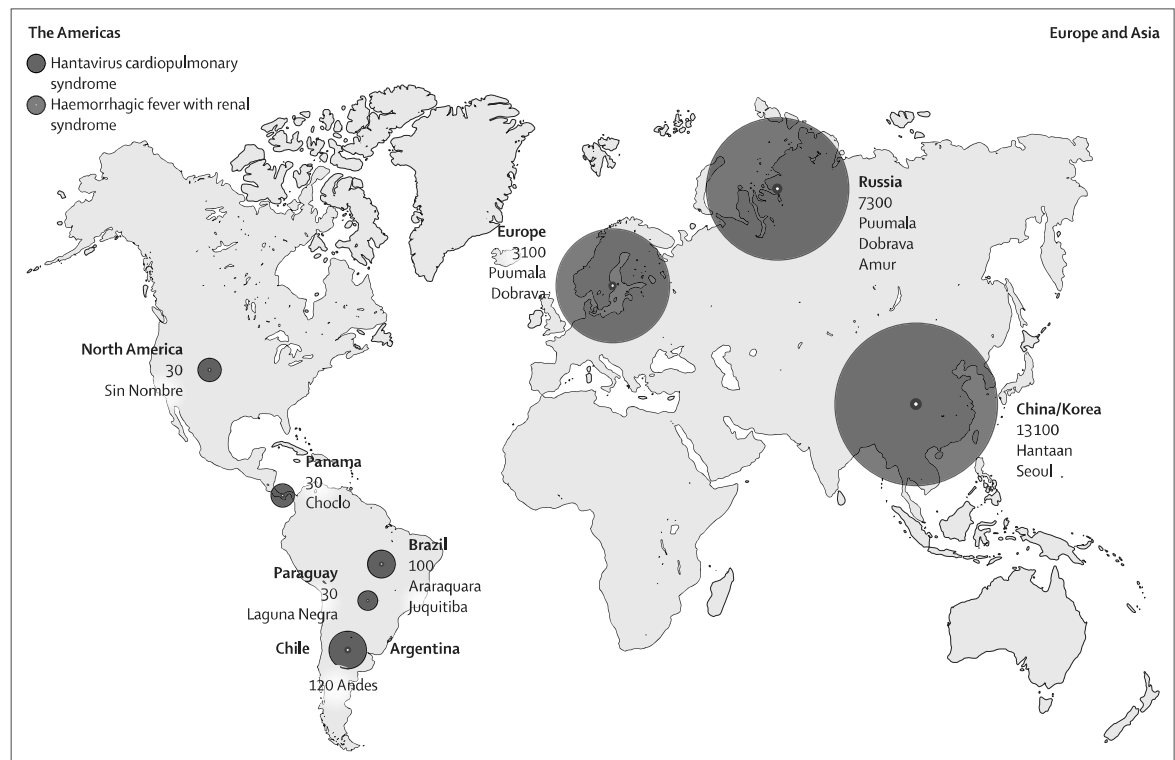


Figure 2: Mean annual number of reported hantavirus cases in different regions and countries (2000–20)
 Unrecognised cases exceed reported cases for Puumala, Seoul, and Chodo virus.^{8,73,78,39–41}

five stages (febrile, hypotensive, oliguric, diuretic, and convalescent).^{16,74,75} However, the course and severity of infection varies among individuals and hantavirus type; for example, PUUV, HTNV, and SEOV tend to cause milder symptoms than DOBV does.¹⁶ In milder cases, the clinical phases might be less identifiable. Among confirmed HFRS cases in Europe, between 30% and 50% are hospitalised, often due to severe symptoms or suspicion of bacterial infection.^{19,76}

After an incubation period of 2–6 weeks, prominent features include acute onset of high fever with headache, nausea, myalgia, and abdominal and back pain. Due to vascular leakage, hypotension is frequent during this early acute phase.¹⁶

The febrile phase lasts approximately 7 days and is accompanied by coagulation abnormalities, thrombocytopenia, and haemorrhagic diatheses.^{4,16} Bleeding is more frequent in severe HFRS (caused by HTNV and DOBV) and can include petechiae in skin or mucosa, epistaxis, menorrhagia, metrorrhagia, and gastrointestinal bleeding, although fatal bleeding is rare. In PUUV, a third of patients have mild haemorrhages.^{77,78} An oliguric phase occurs in half of HFRS cases and can be associated with hypertension, complications of renal insufficiency, and pulmonary oedema. Ocular symptoms, mostly blurred vision caused by a thickening of the lens leading to transient myopia, is found in up to 70% of patients infected with PUUV.

Typical laboratory findings include proteinuria, haematuria, decreased plasma albumin concentration and elevated haemoglobin concentration due to plasma leakage, and thrombocytopenia in the early stage. C-reactive protein, interleukin-6, and other markers of inflammation are also elevated. Markers for acute kidney injury and increased serum creatinine and urea concentrations can be observed 5–9 days after disease onset, during the oliguric phase.⁷⁹ Elevated liver transaminases, lactate dehydrogenase, and leukocyte counts are frequent.⁷⁹ The severity of thrombocytopenia is associated with longer hospital stays and higher creatinine concentrations.^{25,79–82} Patients infected with DOBV have a higher proportion of acute renal failure, visual disturbances, severe thrombocytopenia, and other abnormal laboratory findings than do patients infected with PUUV.⁷⁴

Cardiopulmonary involvement with respiratory failure and shock might also occur in HFRS.^{29,72,73} In a German study, electrocardiogram (ECG) abnormalities were detected in 18%, and relative bradycardia in 80%, of patients infected with PUUV.⁸² In the Balkans, more than half of patients with PUUV and DOBV showed ECG abnormalities and half had pathological pulmonary x-rays with interstitial infiltrates and pleural effusions.²⁵ Patients with HFRS mostly die from shock, complications of renal insufficiency, and multiorgan failure.²² Findings at autopsy can include microthrombi, interstitial oedema, and perivascular haemorrhage, especially in the kidneys

and lungs.^{22,83} Kidney biopsies from patients with HFRS show interstitial haemorrhage, microvascular inflammation including the presence of T cells and macrophages, and peritubular capillaritis.²⁹

HCPS-causing hantaviruses mainly target the respiratory and cardiovascular systems (figure 1). HCPS begins with a febrile prodrome: myalgias, headaches, chills, abdominal pain, vomiting, diarrhoea, arthralgia, conjunctival injection, and retro-ocular pain that lasts 2–7 days.^{8,49,50,84} Respiratory symptoms such as nasal congestion and odynophagia are infrequent, and abdominal pain can be intense and confused with acute abdomen. Patients infected with ANDV might also have petechiae on the axilla and extremities. The febrile prodrome is followed by the cardiopulmonary phase with sudden onset of cough, dyspnoea, tachycardia, and hypotension. These symptoms reflect increased vascular permeability, that in a period of hours leads to non-cardiogenic pulmonary oedema, respiratory failure, and often cardiogenic shock.^{8,41,49} However, some patients only develop prodromal phase symptoms and do not progress to the cardiopulmonary phase.^{8,49} More than half of SNV and ANDV infections are severe, whereas CHOV is associated with a milder form for which less than 10% of patients develop respiratory failure, and shock is rare.^{26,41,57} The cardiopulmonary phase lasts 2–4 days, with most deaths occurring within the first 24 h after hospital admission.⁴ In surviving patients, the deregulation of the endothelial cell barrier is reversed quickly.

Thrombocytopenia is observed early on, even before the onset of the cardiopulmonary phase. A prognostic role for thrombocytopenia in HFRS and HCPS has been described in relation to severity of inflammation, and development of severe acute kidney injury.^{79–81} In the cardiopulmonary phase, immunoblasts are usually present in the blood smear with leukocytosis without toxic degeneration, and a possible increase of haematocrit and haemoglobin. Other frequent findings are mild elevation of plasma creatinine and liver enzymes, increased lactate dehydrogenase, hyponatraemia, and proteinuria. Chest x-rays are usually normal during the prodrome, but bilateral infiltrates develop rapidly with a mixed interstitial and alveolar pattern, and pleural effusions in the cardiopulmonary phase.^{50,85} The usual findings in lung CT scans are marked septa, ground-glass opacities, and pleural effusions (figure 4).

Differential diagnosis

HFRS and HCPS must be differentiated, especially in the prodromal phase, with other febrile illnesses present in the geographical area. These include leptospirosis, atypical pneumonia with bilateral infiltrates, sepsis with acute respiratory distress syndrome and endocarditis with pulmonary oedema, and influenza. In western USA, pneumonic plague should also be considered.^{49,86}

Fever and thrombocytopenia can be caused by a variety of infections such as dengue virus, severe fever with

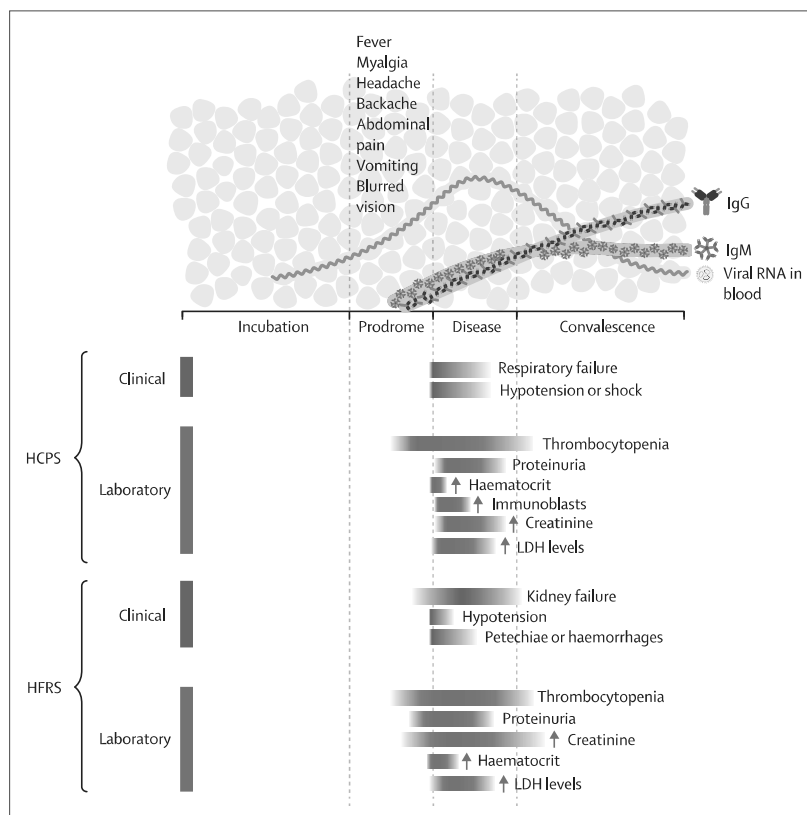


Figure 3: Main clinical and laboratory findings of HFRS and HCPS

HCPS=hantavirus cardiopulmonary syndrome. HFRS=haemorrhagic fever with renal syndrome. Ig=immunoglobulin. LDH=lactate dehydrogenase.

thrombocytopenia syndrome, Crimean–Congo haemorrhagic fever, other arboviral infections, septicaemia, and rickettsiosis.^{49,86,87} Hantavirus infections can mimic an acute abdomen or other febrile gastrointestinal diseases such as typhoid fever. In pregnant women, the abdominal pain, urinary complaints, hypertension, and low platelet count that can be present in hantavirus infections must be differentiated from haemolysis, elevated liver enzymes, and low platelets syndrome (known as HELLP), and other complications of pregnancy.⁸⁸

Hantavirus in children

The clinical course of HFRS and HCPS for children seems to be similar to the course for adults.^{89–93} Abdominal pain and vomiting are common in children with a PUUV infection, but otherwise the clinical course appears similar to or milder than in adults.^{89,90,94,95} SOCV (a DOBV genotype in Russia) shows similar clinical severity and key laboratory findings among children and adults,⁹¹ but respiratory involvement is less frequently described in children than adults.⁸⁹

The proportion of cases in children varies by region. For HFRS, children and adolescents represent 1.7% of the cases in China, 6.0% in Finland,

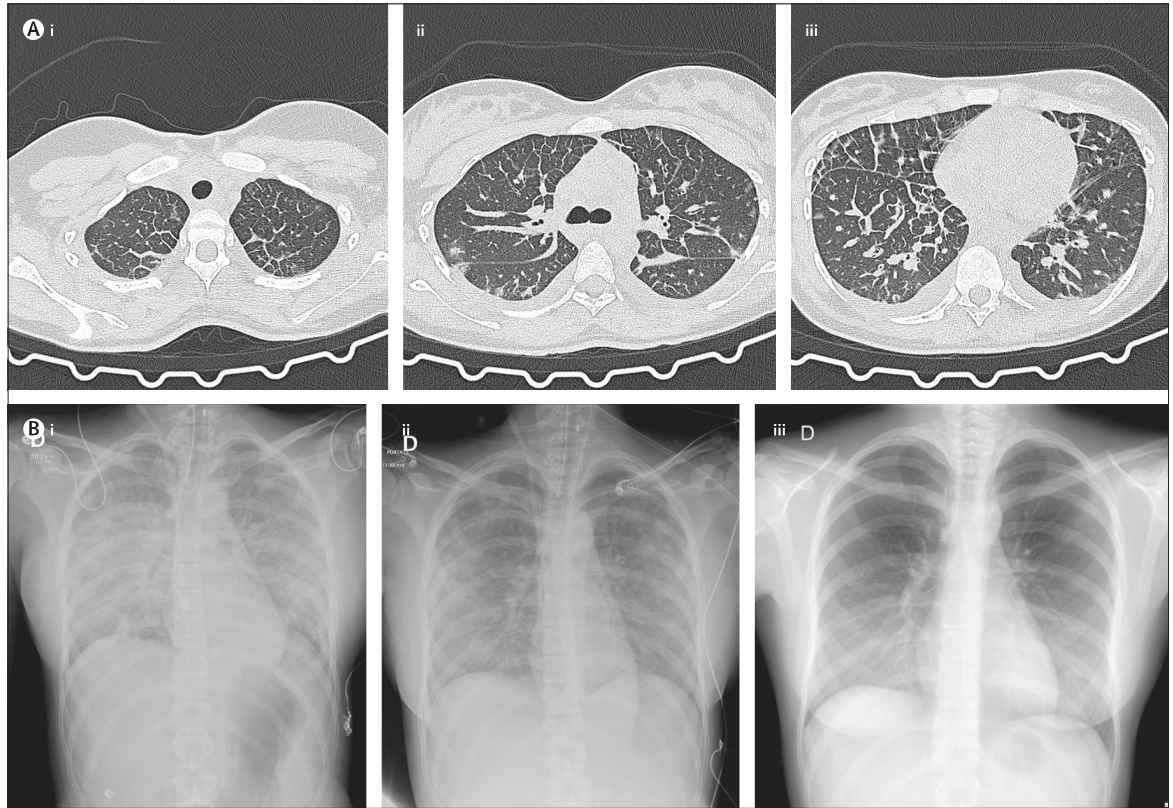


Figure 4: Chest images during the clinical course of hantavirus cardiopulmonary syndrome

(A) Representative CT scan of the chest, obtained at hospital admission in a patient with hantavirus cardiopulmonary syndrome in the cardiopulmonary phase. (Ai) Apical level, (Aii) carinal level, and (Aiii) basal level. The usual findings are marked bilateral septal thickening, and ground-glass opacities and pleural effusions. (B) Typical evolution of pulmonary opacities in chest x-ray images at different clinical time courses: (Bi) the acute phase starting mechanical ventilation, (Bii) weaning off mechanical ventilation, and (Biii) when extubated.

9.7% in Russia, and 6.9% in Germany. In 2019, the incidence in Europe was less than 0.5 cases per 100 000 in children aged 14 years or younger, representing 1.3% of all cases in Europe.^{19,43,96} For HCPS, 18.6% of the cases in Chile, 8% in the USA, 10% in Brazil, and 9% in Argentina occur in children younger than 16 years.^{92,97–99} HCPS caused by ANDV occurs in children aged younger than 10 years and in adolescents,^{93,97} whereas SNV infection in children is largely limited to adolescents.^{93,98,100} Why the prevalence of HFRS and HCPS is lower in children remains unclear, but it might be due in part to fewer high-risk activities such as working in agriculture and forestry. The gender distribution in children (1:1) is different than in adults (4:1 male:female).^{92,93} The prodromal and cardiopulmonary phases, and laboratory findings in children are similar to those in adults.^{27,92,93,100}

Pregnancy infection and outcome in newborn babies

The severity of PUUV, DOBV, and ANDV infections is similar in pregnant and non-pregnant women,^{101,102} but HTNV infections can be more severe, especially in the third trimester.^{88,103} Severe HFRS and HCPS can lead to

obstetric or fetal complications.^{101,102} Miscarriage or preterm labour (before 37 weeks) appears to be due to maternal infection (eg, hypoxaemia and hypotension), rather than fetal infection.^{101,104} Intrauterine transmission is very rare and has not been reported for SNV, ANDV, PUUV, DOBV, or SEOV. A few cases of suspected intrauterine transmission have been reported for HTNV, but only one case was confirmed by the presence of immunoglobulin M (IgM) in fetal cord blood and pathological findings at autopsy.^{101,105} In 2020, two cases of ANDV infection in breastfeeding mothers with transmission to their newborn babies were reported.^{106,107} In one case, viral RNA was detected in the mother's breastmilk,¹⁰⁷ as previously reported for SNV.¹⁰⁸

Possible complications and sequelae after HFRS and HCPS

Systemic and organ-related complications and sequelae might occur depending on the type of hantavirus syndrome, causative virus, and severity of the acute infection. Fatigue, impaired kidney and lung function, and hypertonia have been reported after HFRS,^{73,109,110} but the increased risk for hypertonia was not detected

10 years after HFRS.¹¹¹ Although hypertension and proteinuria are common at follow-up, kidney function seems to be restored after HFRS.^{79,112} Up to 80% of patients with PUUV might have hormonal dysfunction at follow-up.¹¹³ Like SARS-CoV-2, hantavirus infections might increase the risk for thromboembolic complications such as stroke and myocardial infarction.¹¹⁴ Information on long-term sequelae in HCPS is insufficient, but transient convalescent pulmonary dysfunction, potential chronic renal sequelae, retinal haemorrhage, optic neuritis, and sensorineural hypacusis have all been reported.^{115–117} Long-term complications of SNV or ANDV infection can be difficult to differentiate from effects of long-term critical care hospitalisation and extracorporeal membrane oxygenation (ECMO).

Hantavirus diagnosis

Hantavirus infection should be considered in patients who reside in or have recent (5–50 days before) travel history to an endemic region, presenting with either persistent fever (>48 h), headache, myalgia, gastrointestinal manifestations (abdominal pain, vomiting, and diarrhoea), and a marked decrease in platelet count, or in the case of more advanced illness, cough, dyspnoea, hypoxia and bilateral pulmonary infiltrates, or acute renal dysfunction. In ANDV endemic regions, close contact with an infected patient in the previous 40 days, in particular sexual contact or sleeping in the same room, should also be considered a risk factor.^{76,49,58} Detection of proteinuria and haematuria with urine dipstick analysis supports the clinical suspicion of HFRS, although serology is the most widely used diagnostic test. IgM antibodies directed against hantavirus nucleocapsid protein are often present at onset of the febrile prodrome, and IgG antibodies directed against nucleocapsid proteins are usually present by the end of the febrile prodrome.^{118–120} The serological standard method for confirmation is enzyme-linked immunosorbent assay (EIA). Immunochromatographic IgM assays prepared with nucleocapsid protein have been used for diagnosis of HFRS caused by PUUV, HTNV, and DOBV (in one virus or combined formats), with assay performance greater than 90% compared with EIA IgM assays. The immunochromatographic IgM test for PUUV has also been used to test for SNV and ANDV, although immunochromatographic tests should be confirmed with specific EIA to minimise the false positive results.¹²¹ IgG EIA tests are used alongside IgM EIA tests for acute diagnosis, and for seroprevalence studies. Neutralising antibody assays are mainly used to study natural immunity or evaluate candidate vaccines and monoclonal antibodies.¹²²

RT-qPCR, usually designed to detect the S segment, is sensitive and specific.^{123–125} Viral loads are higher in buffy coat than in plasma, and RT-qPCR can detect ANDV

RNA for up to 2 weeks before symptom onset and detection of antibodies, and for weeks after resolution of symptoms (figure 3).^{58,124} Similar molecular tests have been developed in the USA, Panama, and Brazil for local strains. RT-qPCR assays are also used for the diagnosis of DOBV and PUUV in the early phase of infection, even when specific antibodies are not present.¹²⁵ An RT-qPCR for a consensus region of PUUV's nucleocapsid protein from different geographical locations in Sweden showed a 98.7% sensitivity, and 100% specificity in the diagnosis of confirmed patients within the first 8 days of symptoms. It also established the diagnosis in 9.6% of patients who were negative for specific PUUV antibodies early in the disease.¹²⁵ A nested RT-PCR for the L segment has been developed for diagnosis of early phase HFRS in serum and urine; the virus was detected earlier in urine than in serum, and was detected in both fluids for up to 1 month after initial symptoms.¹²⁶ Next-generation sequencing has been used to study viral genomic epidemiology, including suspected person-to-person transmission.⁵⁹

Treatment and supportive care

There is no specific effective antiviral or immunomodulatory treatment available; treatment of patients admitted to hospital is supportive. Intravenous ribavirin reduced mortality in one controlled trial for HFRS in China,¹²⁷ but these trials are insufficient. Ribavirin was ineffective against HFRS caused by PUUV,¹²⁸ and a small, placebo-controlled trial that used intravenous ribavirin for HCPS (in the cardiopulmonary phase) in North America suggested no survival benefit.¹²⁹ Similarly, high-dose intravenous methylprednisolone was ineffective in a controlled trial for HCPS (in the cardiopulmonary phase) in Chile.¹³⁰

Management strategies of HFRS include careful monitoring of clinical signs, fluid and electrolyte balance, blood pressure, and urine production. Treatments include analgesic drugs, intravenous fluid against hypotension, oxygenation against hypoxia, and correction of electrolyte imbalances. Dialysis is required in 15% of patients with DOBV, but in less than 5% of patients with PUUV.⁷⁹ Mechanical ventilation and renal replacement therapy might be necessary in severe cases with acute respiratory distress syndrome and overt kidney failure.⁷² Patients with hypotension and shock receive vasoactive drugs together with fluid.

Favipiravir was effective in ANDV and SNV animal models when given before onset of viraemia,¹³¹ and icatibant acetate, a bradykinin receptor antagonist, has been used in several patients with severe HFRS.¹³² Notably, an association has been shown between low concentrations of specific antibodies in serum during the acute phase, and severe or fatal outcomes in patients infected with PUUV, ANDV, or SNV.^{133,134} In an open study in Chile, mortality in patients infected with ANDV treated with convalescent plasma was lower than in

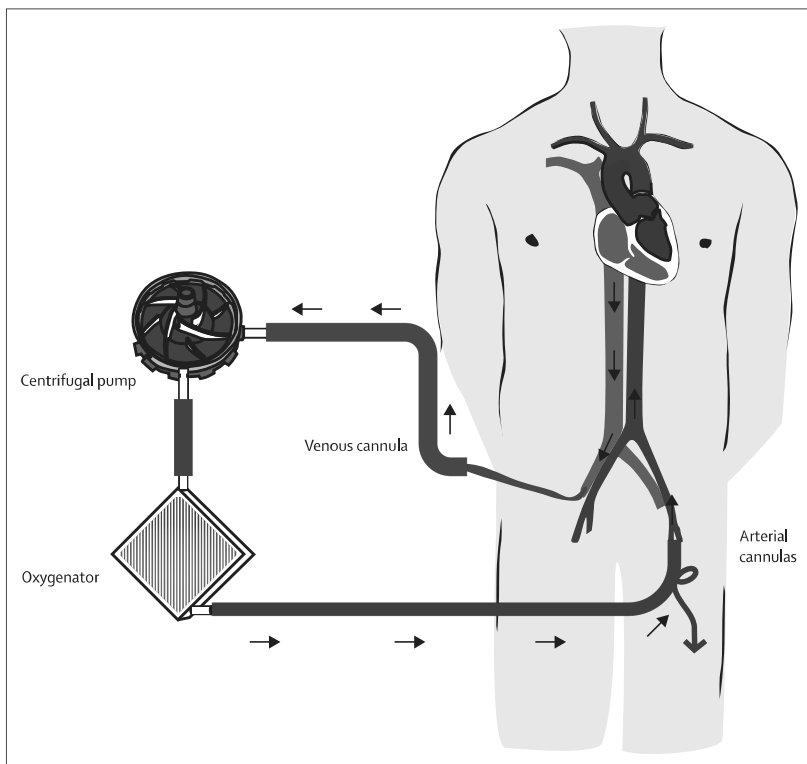


Figure 5: Peripherally inserted venoarterial extracorporeal membrane oxygenation configuration
A centrifugal pump drains deoxygenated blood from the right atrium via the femoral vein, blood is oxygenated by a membrane, and finally the oxygenated blood returns to the external iliac artery via the common femoral artery. A distal perfusion cannula supplies blood flow to the leg and prevents ischaemia.

non-randomised comparison groups,¹³⁵ and candidate monoclonal antibodies have shown promising results in neutralising different hantavirus strains *in vitro*, and protecting against hantavirus infection in animal models.^{136–138}

Given the scarcity of specific therapies, advanced supportive care is the cornerstone of treatment for HCPS. Patients with suspected, presumptive, or confirmed HCPS should be transferred to a health-care centre with critical care units and access to ECMO.^{139,140} An international listing of ECMO centres with emergency contacts is available.¹⁴¹

Patients with HCPS are rarely admitted to the hospital before onset of the cardiopulmonary phase, and can progress to shock and death before antibody results or PCR results are available. Therefore, most decisions regarding transfer to a centre with ECMO capability, and establishment of vascular access for ECMO, must be made on the basis of clinical suspicion and results of routine laboratory tests. In the cardiopulmonary phase, a presumptive diagnosis can be established with blood count or peripheral smear criteria, for which the presence of at least four out of five criteria (thrombocytopenia, left shift in the granulocytic lineage, absence of toxic granulation in the myeloid series, haemoconcentration, and an immunoblast population

greater than 10% of the total leukocyte population) has a sensitivity of 96%, and a specificity of 99%.¹⁴² Common laboratory assays can also identify patients at increased risk of severe disease. A platelet count greater than 115 000 platelets per μL at admission has been associated with a lower risk of progression to severe HCPS, whereas a platelet count lower than 40 000 platelets per μL has been associated with increased mortality.¹⁴³ Similarly, positive quantitative proteinuria at hospital admission has been linked to mortality.¹⁴⁴

When the clinical or laboratory signs of circulatory shock begin, appropriate monitoring allows for the implementation of advanced organ support. Patients with HCPS might change from room air oxygen to invasive mechanical ventilation, and from normal haemodynamics to refractory shock within hours.¹⁴⁰ Some patients progress to cardiogenic shock despite inotropic drugs, and might not reach respiratory stabilisation despite invasive mechanical ventilation, so ECMO should be considered.¹³⁹

The pathophysiology of HCPS is characterised by a pulmonary capillary leak with non-cardiac pulmonary oedema, and low preload, progressive hypovolaemia, cardiac index impairment, and high systemic vascular resistance index in severe disease.^{145,146} When clinical hypoperfusion (mottling and slow capillary refill time) or hyperlactataemia is present, haemodynamic monitoring of cardiac index and inotropic drugs titration should be started promptly. Cardiac index can be monitored by thermodilution-based techniques, including transpulmonary thermodilution or pulmonary artery catheterisation. Serial cardiac index monitoring by echocardiography is a less invasive option that is used in centres where trained staff are continuously available to assess changes.

Volume resuscitation should be avoided, as it can exacerbate pulmonary oedema and increase mortality.¹⁴⁷ Inotropic drugs are the main strategy for improving cardiac index, and although oxygen and ventilatory support should be considered, intubation should be delayed when feasible until vascular access for ECMO has been established.¹³⁹ When shock is refractory to inotropic drug support (dobutamine or epinephrine), or respiratory support does not provide adequate gas exchange, early connection to venoarterial ECMO should be considered (figure 5).

Clinical experience with venoarterial ECMO for severe HCPS is substantial (figure 5).^{139,148,149} A study by Wernly and colleagues reported 80% survival in 25 patients treated with veno-arterial ECMO.¹³⁹ These patients initially had insertion of vascular sheaths based on a presumptive or definitive diagnosis of HCPS (rather than criteria for immediate initiation of ECMO), followed by a delay of intubation until it could be performed almost concurrently with placement of vascular access.¹³⁹ Tailored high-volume haemofiltration was used before ECMO in five patients, thereby avoiding ECMO in three patients.¹⁵⁰

Conclusions and future perspectives

Clinical outcomes of severe hantavirus infections are dependent on clinical suspicion, rapid diagnostic tests or algorithms for presumptive diagnosis, and prompt transfer to a facility with critical care units, including units with access to ECMO for HCPS. Development of readily available pan-hantavirus serological and RT-qPCR tests is needed. As reviewed in 2019, no treatment or vaccines are approved for use in Europe and the Americas.¹⁵¹ Randomised clinical trials are warranted to evaluate the efficacy of candidate antivirals, neutralising antibodies, and drugs such as icatibant.¹⁵¹ Although inactivated HTNV and SEOV vaccines are used in Asia, and case numbers decreased following implementation,^{152,153} clear evidence of vaccine efficacy is absent. Safe, effective vaccines are needed, especially in the Americas, where deadly hantaviruses circulate. The Yosemite outbreak in California, USA, and the large person-to-person outbreak in Argentina highlight the need for protocols for early diagnosis and treatment of exposed individuals.^{59,70} Evaluation of early post-exposure treatment with favipiravir (before viraemia), ribavirin (with viraemia), or neutralising antibodies might be considered for close household contacts of ANDV cases, those exposed after high-risk laboratory accidents, or in super-spreader events. Finally, additional research is needed to identify long-term sequelae.

Contributors

PAV and RL searched the literature. All authors reviewed the literature, wrote and reviewed the original draft, and contributed equally. PAV, RL and GJM designed the figures. PAV and GJM edited the manuscript. CV and NLC managed the references.

Declaration of interests

We declare no competing interests.

Acknowledgments

Grants have financed studies of HFRS and HCPS by the authors in Europe and the Americas, and supported researchers protected time for data analysis and writing: NIH U01 AI045452 (PAV, GJM, MF, CV), Fondecyt 1201240 (CV, PAV, MF, JK), Fondecyt 1211825 (MF, NLC, CV), ATE220061 (CV, MF, PAV), and The Center for Medical Innovation 20200141 (JK). We would like to thank Felipe Serrano for scientific illustrations (figures 1, 4) and Marilaura Nuñez for assistance in conducting publications search.

Editorial note: The Lancet Group takes a neutral position with respect to territorial claims in published maps and institutional affiliations.

References

- Lee HW, Lee PW, Johnson KM. Isolation of the etiologic agent of Korean hemorrhagic fever. *J Infect Dis* 1978; **137**: 298–308.
- Lee HW, Vaheri A, Schmaljohn CS. Discovery of hantaviruses and of the *Hantavirus* genus: personal and historical perspectives of the presidents of the international society of hantaviruses. *Virus Res* 2014; **187**: 2–5.
- Ksiazek TG, Peters CJ, Rollin PE, et al. Identification of a new north American hantavirus that causes acute pulmonary insufficiency. *Am J Trop Med Hyg* 1995; **52**: 117–23.
- Avšič-Županc T, Saksida A, Korva M. Hantavirus infections. *Clin Microbiol Infect* 2019; **21S**: e6–16.
- Witkowski PT, Klempa B, Ithete NL, et al. Hantaviruses in Africa. *Virus Res* 2014; **187**: 34–42.
- Laenen L, Vergote V, Calisher CH, et al. Current classification and future perspectives. *Viruses* 2019; **11**: 788.
- Vaheri A, Strandin T, Hepojoki J, et al. Uncovering the mysteries of hantavirus infections. *Nat Rev Microbiol* 2013; **11**: 539–50.
- Jonsson CB, Figueiredo LTM, Vapalahti O. A global perspective on hantavirus ecology, epidemiology, and disease. *Clin Microbiol Rev* 2010; **23**: 412–41.
- Douglas KO, Payne K, Sabino-Santos G Jr, Agard J. Influence of climatic factors on human hantavirus infections in Latin America and the Caribbean: a systematic review. *Pathogens* 2021; **11**: 15.
- Kallio ER, Klingström J, Gustafsson E, et al. Prolonged survival of Puumala hantavirus outside the host: evidence for indirect transmission via the environment. *J Gen Virol* 2006; **87**: 2127–34.
- Hardestam J, Simon M, Hedlund KO, Vaheri A, Klingström J, Lundkvist A. Ex vivo stability of the rodent-borne Hantaan virus in comparison to that of arthropod-borne members of the *Bunyviridae* family. *Appl Environ Microbiol* 2007; **73**: 2547–51.
- Klingström J, Smed-Sörensen A, Maleki KT, et al. Innate and adaptive immune responses against human Puumala virus infection: immunopathogenesis and suggestions for novel treatment strategies for severe hantavirus-associated syndromes. *J Intern Med* 2019; **285**: 510–23.
- Noack D, Goeijenbier M, Reusken CBEM, Koopmans MPG, Rockx BHG. Orthohantavirus pathogenesis and cell tropism. *Front Cell Infect Microbiol* 2020; **10**: 399.
- Mackow ER, Gavrillovskaia IN. Hantavirus regulation of endothelial cell functions. *Thromb Haemost* 2009; **102**: 1030–41.
- Koskela S, Mäkelä S, Strandin T, et al. Coagulopathy in acute Puumala hantavirus infection. *Viruses* 2021; **13**: 1553.
- Jiang H, Du H, Wang LM, Wang PZ, Bai XF. Hemorrhagic fever with renal syndrome: pathogenesis and clinical picture. *Front Cell Infect Microbiol* 2016; **6**: 1.
- Reynes JM, Carli D, Boukezia N, Debruyne M, Herti S. Tula hantavirus infection in a hospitalised patient, France, June 2015. *Euro Surveill* 2015; published online Dec 17. <https://doi.org/10.2807/1560-7917.es.2015.20.50.30095>.
- Hofmann J, Kramer S, Herrlinger KR, et al. Tula virus as causative agent of hantavirus disease in immunocompetent person, Germany. *Emerg Infect Dis* 2021; **27**: 1234–37.
- Makary P, Kanerva M, Ölgren J, Virtanen MJ, Vapalahti O, Lyytikäinen O. Disease burden of Puumala virus infections, 1995–2008. *Epidemiol Infect* 2010; **138**: 1484–92.
- Papa A. Dobrava-Belgrade virus: phylogeny, epidemiology, disease. *Antiviral Res* 2012; **95**: 104–17.
- Tkachenko EA, Ishmukhametov AA, Dzagurova TK, et al. Hemorrhagic fever with renal syndrome, Russia. *Emerg Infect Dis* 2019; **25**: 2325–28.
- Malinin OV, Kiryanov NA. Fatal cases of hemorrhagic fever with renal syndrome in Udmurtia, Russia, 2010 to 2019. *Eur J Clin Microbiol Infect Dis* 2022; **41**: 1059–64.
- Figueiredo LTM, Souza WM de, Ferrés M, Enria DA. Hantaviruses and cardiopulmonary syndrome in South America. *Virus Res* 2014; **187**: 43–54.
- Armien B, Pascale JM, Muñoz C, et al. Hantavirus fever without pulmonary syndrome in Panama. *Am J Trop Med Hyg* 2013; **89**: 489–94.
- Avšič Županc T, Korva M, Markotić A. HFRS and hantaviruses in the Balkans/southeast Europe. *Virus Res* 2014; **187**: 27–33.
- Alonso DO, Iglesias A, Coelho R, et al. Epidemiological description, case-fatality rate, and trends of hantavirus pulmonary syndrome: 9 years of surveillance in Argentina. *J Med Virol* 2019; **91**: 1173–81.
- Ramos MM, Overturf GD, Crowley MR, Rosenberg RB, Hjelle B. Infection with Sin Nombre hantavirus: clinical presentation and outcome in children and adolescents. *Pediatrics* 2001; **108**: E27.
- Centers for Disease Control and Prevention. Reported cases of hantavirus disease. <https://www.cdc.gov/hantavirus/surveillance/> (accessed Aug 10, 2022).
- Koehler FC, Di Cristanziano V, Späth MR, et al. The kidney in hantavirus infection-epidemiology, virology, pathophysiology, clinical presentation, diagnosis and management. *Clin Kidney J* 2022; **15**: 1231–52.
- Zeier M, Handermann M, Bahr U, et al. New ecological aspects of hantavirus infection: a change of a paradigm and a challenge of prevention—a review. *Virus Genes* 2005; **30**: 157–80.

- 31 Jameson LJ, Logue CH, Atkinson B, et al. The continued emergence of hantaviruses: isolation of a Seoul virus implicated in human disease, United Kingdom, October 2012. *Euro Surveill* 2013; **18**: 4–7.
- 32 Jameson LJ, Taori SK, Atkinson B, et al. Pet rats as a source of hantavirus in England and Wales, 2013. *Euro Surveill* 2013; **18**: 20415.
- 33 Clement J, LeDuc JW, Lloyd G, et al. Wild rats, laboratory rats, pet rats: global Seoul hantavirus disease revisited. *Viruses* 2019; **11**: 652.
- 34 Witkowski PT, Leendertz SAJ, Auste B, et al. Human seroprevalence indicating hantavirus infections in tropical rainforests of Côte d'Ivoire and Democratic Republic of Congo. *Front Microbiol* 2015; **6**: 518.
- 35 Engler O, Klingström J, Aliyev E, et al. Seroprevalence of hantavirus infections in Switzerland in 2009: difficulties in determining prevalence in a country with low endemicity. *Euro Surveill* 2013; **18**: 20660.
- 36 Kramski M, Achazi K, Klempa B, Krüger DH. Nephropathia epidemica with a 6-week incubation period after occupational exposure to Puumala hantavirus. *J Clin Virol* 2009; **44**: 99–101.
- 37 Sinisalo M, Vapalahti O, Ekblom-Kullberg S, et al. Headache and low platelets in a patient with acute leukemia. *J Clin Virol* 2010; **48**: 159–61.
- 38 Kuenzli AB, Marschall J, Schefold JC, et al. Hantavirus cardiopulmonary syndrome due to imported Andes hantavirus infection in Switzerland: a multidisciplinary challenge, two cases and a literature review. *Clin Infect Dis* 2018; **67**: 1788–95.
- 39 Wang Q, Yue M, Yao P, et al. Epidemic trend and molecular evolution of HV family in the main hantavirus epidemic areas from 2004 to 2016, in P.R. China. *Front Cell Infect Microbiol* 2021; **10**: 584814.
- 40 Park Y. Epidemiologic study on changes in occurrence of hemorrhagic fever with renal syndrome in Republic of Korea for 17 years according to age group: 2001–2017. *BMC Infect Dis* 2019; **19**: 153.
- 41 MacNeil A, Ksiazek TG, Rollin PE. Hantavirus pulmonary syndrome, USA, 1993–2009. *Emerg Infect Dis* 2011; **17**: 1195–201.
- 42 Noh JY, Jung J, Song JW. Hemorrhagic fever with renal syndrome. *Infect Chemother* 2019; **51**: 405–13.
- 43 European Centre for Disease Prevention and Control. Hantavirus infection annual epidemiological report for 2019. European Centre for Disease Prevention and Control. 2021. <https://www.ecdc.europa.eu/sites/default/files/documents/AER-hantavirus-2019.pdf> (accessed Feb 10, 2023).
- 44 Krautkrämer E, Krüger DH, Zeier M. Recent outbreaks of hantavirus disease in Germany and in the United States. *Kidney Int* 2012; **82**: 1243–45.
- 45 Hjertqvist M, Klein SL, Ahlm C, Klingström J. Mortality rate patterns for hemorrhagic fever with renal syndrome caused by Puumala virus. *Emerg Infect Dis* 2010; **16**: 1584–86.
- 46 Bergstedt Oscarsson K, Brorstad A, Baudin M, et al. Human Puumala hantavirus infection in northern Sweden; increased seroprevalence and association to risk and health factors. *BMC Infect Dis* 2016; **16**: 566.
- 47 Gherasim A, Hjertqvist M, Lundkvist Å, et al. Risk factors and potential preventive measures for nephropatia epidemica in Sweden 2011–2012: a case-control study. *Infect Ecol Epidemiol* 2015; **5**: 27698.
- 48 Tervo L, Mäkelä S, Syrjänen J, et al. Smoking is associated with aggravated kidney injury in Puumala hantavirus-induced haemorrhagic fever with renal syndrome. *Nephrol Dial Transplant* 2015; **30**: 1693–98.
- 49 Riquelme R, Rioseco ML, Bastidas L, et al. Hantavirus pulmonary syndrome, southern Chile, 1995–2012. *Emerg Infect Dis* 2015; **21**: 562–68.
- 50 Castillo C, Naranjo J, Sepúlveda A, Ossa G, Levy H. Hantavirus pulmonary syndrome due to Andes virus in Temuco, Chile: clinical experience with 16 adults. *Chest* 2001; **120**: 548–54.
- 51 Watson DC, Sargianou M, Papa A, Chra P, Starakis I, Panos G. Epidemiology of hantavirus infections in humans: a comprehensive, global overview. *Crit Rev Microbiol* 2014; **40**: 261–72.
- 52 Kumar A, Krishnamurthy K, Nielsen AL. Hantavirus infection among children hospitalized for febrile illness suspected to be dengue in Barbados. *J Infect Public Health* 2016; **9**: 81–87.
- 53 Montoya-Ruiz C, Diaz FJ, Rodas JD. Recent evidence of hantavirus circulation in the American tropic. *Viruses* 2014; **6**: 1274–93.
- 54 Ministry of Health, Government of Chile. National Health Status Survey Chile 2003. Communicable diseases: prevalence of viral hepatitis, hantavirus, and papilloma virus. National Health Status Survey Chile 2003. 2005. <http://epi.minsal.cl/wp-content/uploads/2016/03/InformeFinalENS2003.vet.pdf> (accessed Feb 15, 2023).
- 55 Macneil A, Nichol ST, Spiropoulou CF. Hantavirus pulmonary syndrome. *Virus Res* 2011; **162**: 138–47.
- 56 Ferrer JF, Hjelle B, Jonsson CB, et al. High prevalence of hantavirus infection in Indian communities of the Paraguayan and Argentinean Gran Chaco. *Am J Trop Med Hyg* 1998; **59**: 438–44.
- 57 Armien B, Pascale J, Munoz C, et al. Incidence rate for hantavirus infections without pulmonary syndrome, Panama. *Emerg Infect Dis* 2011; **17**: 1936–39.
- 58 Ferres M, Vial P, Marco C, et al. Prospective evaluation of household contacts of persons with hantavirus cardiopulmonary syndrome in Chile. *J Infect Dis* 2007; **195**: 1563–71.
- 59 Martínez VP, Di Paola N, Alonso DO, et al. 'Super-spreaders' and person-to-person transmission of Andes virus in Argentina. *N Engl J Med* 2020; **383**: 2230–41.
- 60 Enría D, Padula P, Segura EL, et al. Hantavirus pulmonary syndrome in Argentina. Possibility of person to person transmission. *Medicina* 1996; **56**: 709–11.
- 61 Pinna DM, Martínez VP, Bellomo CM, López C, Padula P. [New epidemiologic and molecular evidence of person to person transmission of hantavirus Andes Sout]. *Medicina* 2004; **64**: 43–46.
- 62 Martínez-Valdebenito C, Calvo M, Vial C, et al. Person-to-person household and nosocomial transmission of Andes hantavirus, southern Chile, 2011. *Emerg Infect Dis* 2014; **20**: 1629–36.
- 63 Padula PJ, Edelstein A, Miguel SD, López NM, Rossi CM, Rabinovich RD. Hantavirus pulmonary syndrome outbreak in Argentina: molecular evidence for person-to-person transmission of Andes virus. *Virology* 1998; **241**: 323–30.
- 64 Padula P, Figueroa R, Navarrete M, et al. Transmission study of Andes hantavirus infection in wild sigmodontine rodents. *J Virol* 2004; **78**: 11972–79.
- 65 Pizarro E, Navarrete M, Mendez C, et al. Immunocytochemical and ultrastructural evidence supporting that Andes hantavirus (ANDV) is transmitted person-to-person through the respiratory and/or salivary pathways. *Front Microbiol* 2020; **10**: 2992.
- 66 Hardestam J, Lundkvist A, Klingström J. Sensitivity of Andes hantavirus to antiviral effect of human saliva. *Emerg Infect Dis* 2009; **15**: 1140–42.
- 67 Vial C C, Valdivieso R F, Cuiza A V, et al. Sociodemographic risk factors of hantavirus cardiopulmonary syndrome. *Rev Chilena Infectol* 2019; **36**: 428–32 (in Spanish).
- 68 Martínez-Valdebenito C, Angulo J, Le Corre N, et al. A single-nucleotide polymorphism of $\alpha\beta$ integrin is associated with the Andes virus infection susceptibility. *Viruses* 2019; **11**: 169.
- 69 Vial PA, Valdivieso F, Mertz G, et al. Incubation period of hantavirus cardiopulmonary syndrome. *Emerg Infect Dis* 2006; **12**: 1271–73.
- 70 Núñez JJ, Fritz CL, Knust B, et al. Hantavirus infections among overnight visitors to Yosemite national park, California, USA, 2012. *Emerg Infect Dis* 2014; **20**: 386–93.
- 71 Jaksic FM, Lima M. Myths and facts on ratadas: bamboo blooms, rainfall peaks and rodent outbreaks in South America. *Austral Ecol* 2003; **28**: 237–51.
- 72 Du H, Li J, Jiang W, et al. Clinical study of critical patients with hemorrhagic fever with renal syndrome complicated by acute respiratory distress syndrome. *PLoS One* 2014; **9**: e89740.
- 73 Rasmuson J, Lindqvist P, Sörensen K, Hedström M, Blomberg A, Ahlm C. Cardiopulmonary involvement in Puumala hantavirus infection. *BMC Infect Dis* 2013; **13**: 501.
- 74 Markotić A, Nichol ST, Kuzman I, et al. Characteristics of Puumala and Dobrava infections in Croatia. *J Med Virol* 2002; **66**: 542–51.
- 75 Vapalahti O, Mustonen J, Lundkvist Å, Henttonen H, Plyusnin A, Vaheri A. Hantavirus Infections in Europe. *Lancet Infect Dis* 2003; **3**: 653–61.
- 76 Pettersson L, Boman J, Juto P, Evander M, Ahlm C. Outbreak of Puumala virus infection, Sweden. *Emerg Infect Dis* 2008; **14**: 808–10.

- 77 Settergren B, Juto P, Trollfors B, Wadell G, Norrby SR. Clinical characteristics of nephropathia epidemica in Sweden: prospective study of 74 cases. *Rev Infect Dis* 1989; **11**: 921–27.
- 78 Sundberg E, Hultdin J, Nilsson S, Ahlm C. Evidence of disseminated intravascular coagulation in a hemorrhagic fever with renal syndrome-scoring models and severe illness. *PLoS One* 2011; **6**: e21134.
- 79 Latus J, Schwab M, Tacconelli E, et al. Acute kidney injury and tools for risk-stratification in 456 patients with hantavirus-induced nephropathia epidemica. *Nephrol Dial Transplant* 2015; **30**: 245–51.
- 80 Outinen TK, Laine OK, Mäkelä S, et al. Thrombocytopenia associates with the severity of inflammation and variables reflecting capillary leakage in Puumala Hantavirus infection, an analysis of 546 Finnish patients. *Infect Dis* 2016; **48**: 682–87.
- 81 Wang M, Wang J, Wang T, Li J, Hui L, Ha X. Thrombocytopenia as a predictor of severe acute kidney injury in patients with Hantaan virus infections. *PLoS One* 2013; **8**: e53236.
- 82 Kitterer D, Greulich S, Grün S, et al. Electrocardiographic abnormalities and relative bradycardia in patients with hantavirus-induced nephropathia epidemica. *Eur J Intern Med* 2016; **33**: 67–73.
- 78 Sironen T, Sane J, Lokki M-L, et al. Fatal Puumala hantavirus disease: involvement of complement activation and vascular leakage in the pathobiology. *Open Forum Infect Dis* 2017; **4**: ofx229.
- 84 Centers for Disease Control and Prevention. Outbreak of acute illness—southwestern USA, 1993. *MMWR Morb Mortal Wkly Rep* 1993; **42**: 421–24.
- 85 Ketai LH, Williamson MR, Telepak RJ, et al. Hantavirus pulmonary syndrome: radiographic findings in 16 patients. *Radiology* 1994; **191**: 665–68.
- 86 Mattar S, Guzmán C, Figueiredo LT. Diagnosis of hantavirus infection in humans. *Expert Rev Anti Infect Ther* 2015; **13**: 939–46.
- 87 Lee HW, van der Groen G. Hemorrhagic fever with renal syndrome. *Prog Med Virol* 1989; **36**: 62–102.
- 88 Ren D, Fu S, Yan T, et al. The clinical characteristics and outcomes of hemorrhagic fever with renal syndrome in pregnancy. *Front Med* 2022; **9**: 839224.
- 89 Acham-Roschitz B, Aberle SW, Pirker N, et al. Nephropathia epidemica (Puumala virus infection) in Austrian children. *Pediatr Infect Dis J* 2010; **29**: 874–76.
- 90 Echterdiek F, Kitterer D, Alischer MD, et al. Clinical course of hantavirus-induced nephropathia epidemica in children compared to adults in Germany—analysis of 317 patients. *Pediatr Nephrol* 2019; **34**: 1247–52.
- 91 Dzagurova TK, Tkachenko EA, Ishmukhametov AA, Balovneva MV, Klempa B, Kruger DH. Severe hantavirus disease in children. *J Clin Virol* 2018; **101**: 66–68.
- 92 Terças-Trettel ACP, Melo AVG de, Bonilha SMF, et al. Hantavirus pulmonary syndrome in children: case report and case series from an endemic area of Brazil. *Rev Inst Med Trop Sao Paulo* 2019; **61**: e65.
- 93 Ferrés GM, Sandoval CC, Delgado BI, Sotomayor PV, Olea NA, Vial CPA. Hantaviriosis: caracterización clínica-epidemiológica de pacientes pediátricos en Chile. *Rev Chilena Infectol* 2010; **27**: 52–59.
- 94 Dusek J, Pejcoch M, Kolsky A, et al. Mild course of Puumala nephropathy in children in an area with sporadic occurrence Hantavirus infection. *Pediatr Nephrol* 2006; **21**: 1889–92.
- 95 van der Werff ten Bosch J, Heyman P, Potters D, Peeters S, Cochez C, Piérard D. Hantavirus Puumala infection as a cause of fever of unknown origin in a child. *Acta Paediatr* 2004; **93**: 1120–22.
- 96 Shang C, Sun Y, Yin Q, et al. Hemorrhagic fever with renal syndrome—Liaoning Province, China, 1999–2018. *China CDC Wkly* 2020; **2**: 350–54.
- 97 Pini NC, Resa A, del Jesús Laime G, et al. Hantavirus infection in children in Argentina. *Emerg Infect Dis* 1998; **4**: 85–87.
- 98 Overturf GD. Clinical Sin Nombre hantaviral infections in children. *Pediatr Infect Dis J* 2005; **24**: 373–74.
- 99 Reyes Zaldívar F, Ferrés Garrido M. Hantavirus: description of two decades of endemicity and its lethality. *Ars Med* 2019; **44**: 30–39.
- 100 Centers for Disease Control and Prevention. Hantavirus pulmonary syndrome in five pediatric patients—four states, 2009. *MMWR Morb Mortal Wkly Rep* 2009; **58**: 1409–12.
- 101 Howard MJ, Doyle TJ, Koster FT, et al. Hantavirus pulmonary syndrome in pregnancy. *Clin Infect Dis* 1999; **29**: 1538–44.
- 102 Hofmann J, Führer A, Bolz M, et al. Hantavirus infections by Puumala or Dobrava-Belgrade virus in pregnant women. *J Clin Virol* 2012; **55**: 266–69.
- 103 Ji F, Zhao W, Liu H, et al. Hemorrhagic fever with renal syndrome caused by Hantaan virus infection in four pregnant Chinese women. *J Med Virol* 2017; **89**: 1865–70.
- 104 Kim B-N, Choi B-D. Hemorrhagic fever with renal syndrome complicated with pregnancy: a case report. *Korean J Intern Med* 2006; **21**: 150–53.
- 105 Lee HW. Hemorrhagic fever with renal syndrome in Korea. *Rev Infect Dis* 1989; **11**: S846–76.
- 106 Bellomo C, Alonso D, Coelho R, Iglesias A, Periolo N, Martínez VP. A newborn infected by Andes virus suggests novel routes of hantavirus transmission: a case report. *Clin Microbiol Infect* 2020; **26**: 130–31.
- 107 Ferrés M, Martínez-Valdebenito C, Angulo J, et al. Mother-to-child transmission of Andes virus through breast milk, Chile. *Emerg Infect Dis* 2020; **26**: 1885–88.
- 108 Pai RK, Bharadwaj M, Levy H, et al. Absence of infection in a neonate after possible exposure to Sin Nombre hantavirus in breast milk. *Clin Infect Dis* 1999; **29**: 1577–79.
- 109 Mäkelä S, Ala-Houhala I, Mustonen J, et al. Renal function and blood pressure five years after Puumala virus-induced nephropathy. *Kidney Int* 2000; **58**: 1711–18.
- 110 Furberg M, Anticona C, Schumann B. Post-infectious fatigue following Puumala virus infection. *Infect Dis* 2019; **51**: 519–26.
- 111 Miettinen MH, Mäkelä SM, Ala-Houhala IO, et al. Ten-year prognosis of Puumala hantavirus-induced acute interstitial nephritis. *Kidney Int* 2006; **69**: 2043–48.
- 112 Braun N, Haap M, Overkamp D, et al. Characterization and outcome following Puumala virus infection: a retrospective analysis of 75 cases. *Nephrol Dial Transplant* 2010; **25**: 2997–3003.
- 113 Mustonen J, Vaheri A, Pörsti I, Mäkelä S. Long-term consequences of Puumala hantavirus infection. *Viruses* 2022; **14**: 598.
- 114 Connolly-Andersen A-M, Hammargren E, Whitaker H, et al. Increased risk of acute myocardial infarction and stroke during hemorrhagic fever with renal syndrome: a self-controlled case series study. *Circulation* 2014; **129**: 1295–302.
- 115 Sotomayor PV, Olea NAM, Labraña AM, et al. Diagnóstico y manejo del síndrome cardiopulmonar por hantavirus: Chile-2007. *Rev Chil Infect* 2009; **26**: 68–86.
- 116 Pergam SA, Schmidt DW, Nofchissey RA, Hunt WC, Harford AH, Goade DE. Potential renal sequelae in survivors of hantavirus cardiopulmonary syndrome. *Am J Trop Med Hyg* 2009; **80**: 279–85.
- 117 Gracia F, Armien B, Simpson SQ, et al. Convallescent pulmonary dysfunction following hantavirus pulmonary syndrome in Panama and the USA. *Lung* 2010; **188**: 387–91.
- 118 Padula PJ, Colavecchia SB, Martínez VP, et al. Genetic diversity, distribution, and serological features of hantavirus infection in five countries in South America. *J Clin Microbiol* 2000; **38**: 3029–35.
- 119 MacNeil A, Comer JA, Ksiazek TG, Rollin PE. Sin Nombre virus-specific immunoglobulin M and G kinetics in hantavirus pulmonary syndrome and the role played by serologic responses in predicting disease outcome. *J Infect Dis* 2010; **202**: 242–46.
- 120 Schmidt J, Meisel H, Capria SG, et al. Serological assays for the detection of human Andes hantavirus infections based on its yeast-expressed nucleocapsid protein. *Intervirology* 2006; **49**: 173–84.
- 121 Hujakka H, Koistinen V, Kuronen I, et al. Diagnostic rapid tests for acute hantavirus infections: specific tests for Hantaan, Dobrava and Puumala viruses versus a hantavirus combination test. *J Virol Methods* 2003; **108**: 117–22.
- 122 Vial C, Whitaker A, Wilhelm J, et al. Comparison of VSV pseudovirus and focus reduction neutralization assays for measurement of anti-Andes orthohantavirus neutralizing antibodies in patient samples. *Front Cell Infect Microbiol* 2020; **10**: 444.
- 123 Evander M, Eriksson I, Pettersson L, et al. Puumala hantavirus viremia diagnosed by real-time reverse transcriptase PCR using samples from patients with hemorrhagic fever and renal syndrome. *J Clin Microbiol* 2007; **45**: 2491–97.
- 124 Vial C, Martínez-Valdebenito C, Rios S, et al. Molecular method for the detection of Andes hantavirus infection: validation for clinical diagnostics. *Diagn Microbiol Infect Dis* 2016; **84**: 36–39.

- 125 Lagerqvist N, Hagström Å, Lundahl M, et al. Molecular diagnosis of hemorrhagic fever with renal syndrome caused by Puumala virus. *J Clin Microbiol* 2016; **54**: 1335–39.
- 126 Seo J-W, Kim DY, Kim C-M, et al. Utility of nested reverse-transcriptase polymerase chain reaction of clinical specimens for early diagnosis of hemorrhagic fever with renal syndrome. *Am J Trop Med Hyg* 2021; **105**: 1285–89.
- 127 Huggins JW, Hsiang CM, Cosgriff TM, et al. Prospective, double-blind, concurrent, placebo-controlled clinical trial of intravenous ribavirin therapy of hemorrhagic fever with renal syndrome. *J Infect Dis* 1991; **164**: 1119–27.
- 128 Malinin OV, Platonov AE. Insufficient efficacy and safety of intravenous ribavirin in treatment of haemorrhagic fever with renal syndrome caused by Puumala virus. *Infect Dis* 2017; **49**: 514–20.
- 129 Mertz GJ, Miedzinski L, Goade D, et al. Placebo-controlled, double-blind trial of intravenous ribavirin for the treatment of hantavirus cardiopulmonary syndrome in North America. *Clin Infect Dis* 2004; **39**: 1307–13.
- 130 Vial PA, Valdivieso F, Ferres M, et al. High-dose intravenous methylprednisolone for hantavirus cardiopulmonary syndrome in Chile: a double-blind, randomized controlled clinical trial. *Clin Infect Dis* 2013; **57**: 943–51.
- 131 Safronetz D, Falzarano D, Scott DP, Furuta Y, Feldmann H, Gowen BB. Antiviral efficacy of favipiravir against two prominent etiological agents of hantavirus pulmonary syndrome. *Antimicrob Agents Chemother* 2013; **57**: 4673–80.
- 132 Vaheeri A, Strandin T, Jääskeläinen AJ, et al. Pathophysiology of a severe case of Puumala hantavirus infection successfully treated with bradykinin receptor antagonist icatibant. *Antiviral Res* 2014; **111**: 23–25.
- 133 Pettersson L, Thunberg T, Rocklöv J, Klingström J, Evander M, Ahlm C. Viral load and humoral immune response in association with disease severity in Puumala hantavirus-infected patients—implications for treatment. *Clin Microbiol Infect* 2014; **20**: 235–41.
- 134 Bharadwaj M, Nofchissey R, Goade D, Koster F, Hjelle B. Humoral immune responses in the hantavirus cardiopulmonary syndrome. *J Infect Dis* 2000; **182**: 43–48.
- 135 Vial PA, Valdivieso F, Calvo M, et al. A non-randomized multicentre trial of human immune plasma for treatment of hantavirus cardiopulmonary syndrome caused by Andes virus. *Antivir Ther* 2015; **20**: 377–86.
- 136 Mittler E, Wec AZ, Tynell J, et al. Human antibody recognizing a quaternary epitope in the Puumala virus glycoprotein provides broad protection against orthohantaviruses. *Sci Transl Med* 2022; **14**: eabl5399.
- 137 Duehr J, McMahon M, Williamson B, et al. Neutralizing monoclonal antibodies against the Gn and the Gc of the Andes virus glycoprotein spike complex protect from virus challenge in a preclinical hamster model. *MBio* 2020; **11**: e00028–20.
- 138 Williamson BN, Prescott J, Garrido JL, Alvarez RA, Feldmann H, Barría MI. Therapeutic efficacy of human monoclonal antibodies against Andes virus infection in Syrian hamsters. *Emerg Infect Dis* 2021; **27**: 2707–10.
- 139 Wernly JA, Dietl CA, Tabe CE, et al. Extracorporeal membrane oxygenation support improves survival of patients with hantavirus cardiopulmonary syndrome refractory to medical treatment. *Eur J Cardiothorac Surg* 2011; **40**: 1334–40.
- 140 Arauco Brown R, Murthy J, Manian P, Rumbaoa B, Connolly T. An early aggressive strategy for the treatment of hanta virus cardiopulmonary syndrome: a perspective from an extracorporeal membrane oxygenation center. *Clin Infect Dis* 2014; **59**: 458–59.
- 141 Extracorporeal Life Support Organization. ELSO Worldwide Directory of ECMO and ECLS Centers. <https://www.else.org/Membership/CenterDirectory.aspx> (accessed Feb 13, 2023).
- 142 Koster F, Foucar K, Hjelle B, et al. Rapid presumptive diagnosis of hantavirus cardiopulmonary syndrome by peripheral blood smear review. *Am J Clin Pathol* 2001; **116**: 665–72.
- 143 López R, Vial C, Graf J, et al. Platelet count in patients with mild disease at admission is associated with progression to severe hantavirus cardiopulmonary syndrome. *Viruses* 2019; **11**: 693.
- 144 López R, Espinoza M, Graf J, et al. Proteinuria in hantavirus cardiopulmonary syndrome: a frequent finding linked to mortality. *Int J Infect Dis* 2021; **110**: 466–68.
- 145 López R, Pérez-Araos R, Salazar Á, et al. Hemodynamic and pulmonary permeability characterization of hantavirus cardiopulmonary syndrome by transpulmonary thermodilution. *Viruses* 2019; **11**: 900.
- 146 Hallin GW, Simpson SQ, Crowell RE, et al. Cardiopulmonary manifestations of hantavirus pulmonary syndrome. *Crit Care Med* 1996; **24**: 252–58.
- 147 Carvalho Santana R, Campos GM, Figueiredo LTM, de Castro Figueiredo JF. Clinical and laboratory findings related to a favorable evolution of hantavirus pulmonary syndrome. *Rev Soc Bras Med Trop* 2006; **39**: 237–40.
- 148 Arancibia Hernandez F, Fritz R, Sepúlveda C, et al. Impact of early ECMO support on survival of patients with hantavirus cardiopulmonary syndrome in Chile. *Eur Resp J* 2022; **60**: 122.
- 149 Dietl CA, Wernly JA, Pett SB, et al. Extracorporeal membrane oxygenation support improves survival of patients with severe hantavirus cardiopulmonary syndrome. *J Thorac Cardiovasc Surg* 2008; **135**: 579–84.
- 150 López R, Pérez-Araos R, Salazar Á, et al. Targeted high volume hemofiltration could avoid extracorporeal membrane oxygenation in some patients with severe hantavirus cardiopulmonary syndrome. *J Med Virol* 2021; **93**: 4738–47.
- 151 Brocato RL, Hooper JW. Progress on the prevention and treatment of hantavirus disease. *Viruses* 2019; **11**: 610.
- 152 Yi Y, Park H, Jung J. Effectiveness of inactivated hantavirus vaccine on the disease severity of hemorrhagic fever with renal syndrome. *Kidney Res Clin Pract* 2018; **37**: 366–72.
- 153 Li Z, Zeng H, Wang Y, et al. The assessment of Hantaan virus-specific antibody responses after the immunization program for hemorrhagic fever with renal syndrome in northwest China. *Hum Vaccin Immunother* 2017; **13**: 802–07.

Copyright © 2023 Published by Elsevier Ltd. All rights reserved.