

Successful extracorporeal membrane oxygenation therapy in a child with coronavirus 2019 disease-associated ARDS and chemotherapy for Ewing's sarcoma

Perfusion
2022, Vol. 0(0) 1–4
© The Author(s) 2022
Article reuse guidelines:
sagepub.com/journals-permissions
DOI: 10.1177/02676591221127570
journals.sagepub.com/home/prf
SAGE

Carmen Niño-Taravilla,^{1,2,3}  Yuri Zuleta-Morales,¹
Hugo Otaola-Arca,^{4,5}  Benigno Montenegro,^{1,6}
Cristian Sotomayor F,⁶ Claudia Greppi Q,⁶ Pamela Silva Garay⁶ and
Paula Ortiz-Fritz¹

Abstract

Most children and adolescents with SARS-CoV-2 infection show no or mild symptoms, but those with medical histories can be susceptible to more severe forms of disease. There are few reported cases of extracorporeal membrane oxygenation (ECMO) in pediatric patients with coronavirus disease 2019 (COVID-19). We present a previously healthy 13-year-old male diagnosed with metastatic Ewing's sarcoma at the same time as catastrophic acute respiratory distress syndrome due to COVID-19, who was successfully supported by venovenous-ECMO while he received the corresponding chemotherapy protocol.

ECMO can be used as salvage therapy in oncology pediatric patients with respiratory failure secondary to COVID-19. In addition, successful chemotherapy can be administered while patients are supported on ECMO.

Keywords

COVID-19, acute respiratory distress syndrome, extracorporeal membrane oxygenation, Ewing's sarcoma, chemotherapy

Introduction

SARS-CoV-2 mainly affects adults, many of whom require Intensive Care Unit (ICU) admission.¹ Most children and adolescents present the infection with no or mild symptoms, but those with medical histories can be susceptible to more severe forms of disease.² There are few reported extracorporeal membrane oxygenation (ECMO) management cases in pediatric patients with coronavirus 2019 disease (COVID-19).^{3–8} We present a previously healthy 13-year-old male diagnosed with metastatic Ewing's sarcoma while developing catastrophic acute respiratory distress syndrome (ARDS) due to COVID-19. He was successfully supported by venovenous-ECMO (VV-ECMO) while starting chemotherapy.

Case report

A previously healthy 13-year-old male weighing 50 kg consulted for progressive respiratory distress. Chest

computed tomography (CT) (Figure 1(a)) showed massive left pleural effusion and multiple nodular lesions in the right lung. In this context, he was connected to non-invasive mechanical ventilation, empiric antibiotic therapy was started, and a pleural catheter (PC) was placed. Blood tests showed elevated inflammatory markers (C-reactive protein (CRP) 191 mg/L, ferritin 535 ng/mL). In addition, abdominal and pelvic CT

¹Pediatric Intensive Care Unit, Hospital de Niños Roberto del Río, Santiago, Chile

²Pediatric Intensive Care Unit, Clínica Indisa, Santiago, Chile

³Faculty of Medicine, Andrés Bello University, Santiago, Chile

⁴Department of Urology, Clínica Alemana de Santiago, Santiago, Chile

⁵Faculty of Medicine, Clínica Alemana-Universidad del Desarrollo, Santiago, Chile

⁶Pediatric Oncology Service, Hospital de Niños Roberto del Río, Santiago, Chile

Corresponding author:

Carmen Niño-Taravilla, Pediatric Intensive Care Unit, Roberto del Río Children Hospital, Profesor Zañartu 1085, Santiago 7650723, Chile.

Email: carmen.nino@hotmail.com

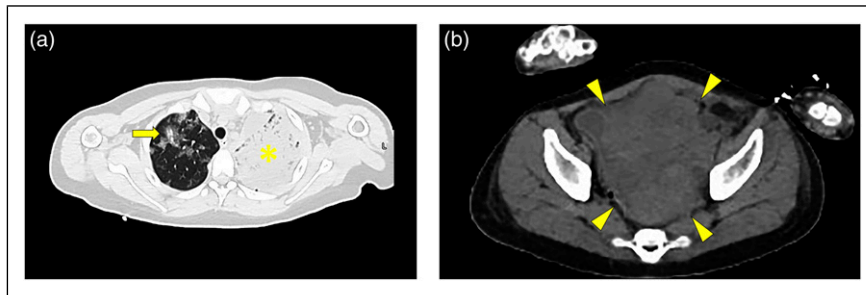


Figure 1. (a) Initial chest computed tomography. Extensive involvement of the left hemithorax containing condensation plus pleural effusion (marked with a yellow asterisk), necrotic areas, and nodules in the pleura, suggesting metastatic involvement; right lung involvement with condensation plus nodules (pointed with a yellow arrow). (b) Initial pelvis computed tomography. Multilobed, heterogeneous pelvic mass measuring $12.4 \times 15.7 \times 12.5$ cm (marked with a yellow arrowhead).

(Figure 1(b)) showed a multilobed, heterogeneous pelvic mass. Brain CT was normal. SARS-COV-2 was confirmed by polymerase chain reaction, so dexamethasone and enoxaparin anticoagulation were initiated. Other therapies such as remdesivir were not considered since they are unavailable in our country. The patient evolved towards severe respiratory distress, and he was connected to invasive mechanical ventilation (IMV) and transferred to the Pediatric Intensive Care Unit (PICU) of the corresponding reference hospital.

He presented a torpid respiratory evolution with severe ARDS, requiring prone position, lung recruitment maneuvers, and neuromuscular blockade. Discrete initial improvement was observed, but on day 11 of hospital admission, he was hypoxemic ($\text{PaO}_2/\text{FiO}_2$ 50, oxygenation index 29), and lung protective ventilation was impossible to sustain. VV-ECMO was decided via a 19 Fr drainage cannula in the right femoral vein and a 17 Fr return cannula in the right internal jugular. ECMO support was initiated at an average flow rate of 60–80 mL/kg/min using a Rotaflow console and a Quadrox-adult oxygenator (Maquet). Protective ventilatory parameters were maintained. Therapeutic anticoagulation was achieved with heparin titration according to the institutional protocol (dose range 15–25 units/kg/h). aPTT levels were monitored four times a day, with a goal of 70–80 s. According to our protocol, it was established that values of hemoglobin <9 g/dl, platelets $<100,000/\text{mm}^3$ and fibrinogen <150 mg/dl required transfusion of blood products. Free hemoglobin monitoring was also performed once a day to rule out the presence of hemolysis.

Etiologic study for the pelvic mass was performed, including beta-human chorionic gonadotropin and alpha-fetoprotein (normal), pleural fluid flow cytometry for malignant hematological diseases (negative), and an ultrasound-guided biopsy of the pelvic mass was made, which confirmed Ewing's sarcoma. South American Protocol for treatment of patients with Ewing's sarcoma

(GALOP/PINDA 2011) was started. Chemotherapy with vincristine, doxorubicin, and cyclophosphamide (VDC) was administered on day 16 of admission, with our patient already on VV-ECMO. The doses were not modified with respect to those indicated in the protocol, receiving on day 23 of admission an additional dose of VDC during ECMO support. Subsequently, he was continued according to this protocol.

He continued in critical condition, with suitable perfusion parameters, but without improvement of ARDS. He continued with high inflammatory biomarkers (maximum CRP 343 mg/L); antimicrobial coverage was changed empirically to vancomycin, meropenem, voriconazole, and cotrimoxazole. Bronchoalveolar lavage (BAL) was performed and ruled out bacterial, fungal, or viral intercurrent. Low IL-6 levels were measured (25 $\mu\text{g}/\text{dl}$), so the use of tocilizumab was ruled out. Due to torpid evolution, compatible with acute fibrinous organizing pneumonia, steroid dosage was increased, changing dexamethasone for methylprednisolone (10 mg/kg daily for 3 days), and maintained subsequently with prednisone in progressively decreasing doses. After that, a decrease in inflammatory parameters was observed but without improvement in the respiratory state.

He presented a new significant respiratory compromise during the third week of admission. A chest CT showed bilateral pleural effusion, more significant in the right lung, with extensive organized blood collections that produced a mass effect in the adjacent lung segments. Due to the patient's condition, resolution of the pulmonary clot was attempted with pleural administration of rt-PA. He presented partial response, so it was decided to perform a video-assisted thoracoscopic surgery, where a collection of clots was identified and cleaned. After the procedure, respiratory improvement was finally observed, but given prolonged IMV, a tracheostomy was performed 30 days after admission. He presented progressive improvement, and after 42 days of

VV-ECMO support, he was decannulated. During these 42 days of support, two oxygenator changes were made, the first was performed 21 days after the start of therapy due to oxygenator dysfunction and the second, 13 days after this first change, due to hemolysis diagnosed by increases in free hemoglobin and hemoglobinuria. In this second opportunity, the circuit was also changed.

Maintained improvement led to IMV weaning off after 85 days of hospital admission.

Chemotherapy protocol was continued, and a rehabilitation program was carried out. His tracheostomy was decannulated on day 118. He was finally discharged from the hospital after 138 days, with a Karnofsky score of 70.

Discussion

There are several reports of ECMO use in adult patients with COVID-19 who develop ARDS.⁹ Ramanathan et al. reported that most patients received VV-ECMO support, and the mortality in these patients was 37.1%, similar to those with non-COVID-19-related ARDS.

Nevertheless, there are no systematic reviews or case series with many pediatric patients who have required ECMO. The European Chapter of the Extracorporeal Life Support Organization (ELSO) reported a case series of only seven children that required ECMO from 52 centers.³ The majority were connected to venoarterial ECMO, and only in 3 cases, the indication for ECMO was hypoxemia. The mortality in this case series was 43%. Apart from this series, there are a few publications of COVID-19 and ECMO in pediatric patients.^{4–8} In them, all the patients described survived except one. However, thrombotic events were frequently reported despite anticoagulation protocols. While these events are common on ECMO, COVID-19 has been associated with an increase in the risk of thrombosis.¹⁰ Our patient's main complication was an organized pulmonary blood collection, probably due to COVID-19 related coagulation disorder and aggravated by chemotherapy. Some authors recommend use of a higher anticoagulation target and thromboelastography based monitoring, due to the hypercoagulable state produced by COVID-19.¹¹ However, ELSO guidelines for management pediatric patients with COVID-19 suggest using standard anticoagulation protocols.¹⁰

Another important aspect of our patient is the use of chemotherapy during ECMO support. This fact is poorly documented in the pediatric literature. We only found a case report of a pediatric patient with T-cell lymphoblastic lymphoma who received chemotherapy during ECMO support.¹² In the case of our patient, after a multidisciplinary meeting, it was decided not to make

changes in the chemotherapy protocol doses. No side effects other than the usual ones caused by these drugs were found. The question remains whether the hematological complications presented by our patient were secondary to the use of chemotherapy or to the coagulation alterations that patients with COVID-19 and ECMO may present.

Conclusion

Extracorporeal membrane oxygenation can be used as salvage therapy in pediatric patients with respiratory failure secondary to COVID-19, including patients with important comorbidities.

This case also illustrates that oncology patients can be supported on ECMO by multidisciplinary teams, and chemotherapy can be successfully administered while the patient is on ECMO support.

Declaration of conflicting interests

The author(s) declared no potential conflicts of interest with respect to the research, authorship, and/or publication of this article.

Funding

The author(s) received no financial support for the research, authorship, and/or publication of this article.

Ethical aspects

Written informed consent to publish this case report was obtained from the patient's guardians.

ORCID iDs

Carmen Niño-Taravilla  <https://orcid.org/0000-0002-3701-6634>

Hugo Otaola-Arca  <https://orcid.org/0000-0003-4952-2283>

References

1. Grasselli G, Zangrillo A, Zanella A, et al. Baseline characteristics and outcomes of 1591 patients infected with SARS-CoV-2 admitted to ICUs of the Lombardy Region, Italy. *JAMA* 2020; 323(16): 1574–1581. DOI: [10.1001/jama.2020.5394](https://doi.org/10.1001/jama.2020.5394)
2. Yasuhara J, Kuno T, Takagi H, et al. Clinical characteristics of COVID-19 in children: a systematic review. *Pediatr Pulmonol* 2020; 55(10): 2565–2575. DOI: [10.1002/ppul.24991](https://doi.org/10.1002/ppul.24991)
3. Di Nardo M, Hoskote A, Thiruchelvam T, et al. Extracorporeal membrane oxygenation in children with coronavirus disease 2019: preliminary report from the collaborative european chapter of the extracorporeal life support organization prospective survey. *ASAIO J* 2021; 67(2): 121–124. DOI: [10.1097/MAT.0000000000001309](https://doi.org/10.1097/MAT.0000000000001309)

4. Lewis D, Fisler G, Schneider J, et al. Veno-venous extracorporeal membrane oxygenation for COVID-19-associated pediatric acute respiratory distress syndrome. *Perfusion* 2020; 35(6): 550–553. DOI: [10.1177/0267659120939757](https://doi.org/10.1177/0267659120939757)
5. Alfoudri H, Shamsah M, Yousuf B, et al. Extracorporeal membrane oxygenation and extracorporeal cardiopulmonary resuscitation for a COVID-19 pediatric patient: a successful outcome. *ASAIO J* 2021; 67(3): 250–253. DOI: [10.1097/MAT.0000000000001377](https://doi.org/10.1097/MAT.0000000000001377)
6. Kakuturu J, McCluskey C, Casey FL, et al. Extracorporeal membrane oxygenation to treat a 15-year-old patient with severe coronavirus disease 2019 (COVID-19) respiratory failure. *JTCVS* 2021; 7: 265–266. DOI: [10.1016/j.xjtc.2021.03.012](https://doi.org/10.1016/j.xjtc.2021.03.012)
7. Flood SM, Osborne CM, Martin B, et al. Severe SARS-CoV-2 infection in a pediatric patient requiring extracorporeal membrane oxygenation. *Case Rep Pediatr* 2020; 2020: 8885022–8885025. DOI: [10.1155/2020/8885022](https://doi.org/10.1155/2020/8885022)
8. Ebach F, Hainmann I, Eis-Hübinger AM, et al. Successful ECMO therapy in a child with COVID-19-associated ARDS and acute lymphoblastic leukemia. *Pediatr Blood Cancer* 2021; 68(9): e29100. DOI: [10.1002/pbc.29100](https://doi.org/10.1002/pbc.29100)
9. Ramanathan K, Shekar K, Ling RR, et al. Extracorporeal membrane oxygenation for COVID-19: a systematic review and meta-analysis. *Crit Care* 2021; 25(1): 211. DOI: [10.1186/s13054-021-03634-1](https://doi.org/10.1186/s13054-021-03634-1)
10. Badulak J, Antonini MV, Stead CM, et al. Extracorporeal membrane oxygenation for COVID-19: updated 2021 guidelines from the extracorporeal life support organization. *ASAIO J* 2021; 67(5): 485–495. DOI: [10.1097/MAT.0000000000001422](https://doi.org/10.1097/MAT.0000000000001422)
11. Kaushik S, Ahluwalia N, Gangadharan S, et al. ECMO support in SARS-CoV2 multisystem inflammatory syndrome in children in a child. *Perfusion* 2021; 36(5): 524–528. DOI: [10.1177/0267659120954386](https://doi.org/10.1177/0267659120954386)
12. Frey TKE, Chopra A, Lin RJ, et al. A child with anterior mediastinal mass supported with veno-arterial extracorporeal membrane oxygenation. *Pediatr Crit Care Med* 2006; 7(5): 479–481. DOI: [10.1097/01.PCC.0000235247.10880.F8](https://doi.org/10.1097/01.PCC.0000235247.10880.F8)