



Tumor-like presentation of herpetic cervicitis: A case report

Pablo Boldrini L. ^{a,b,*}, Gabriel Vallejos P. ^{a,c,d}, Polentze Ballesteros P. ^{a,c},
Gonzalo Valenzuela L. ^{a,c}, Enrique Roncone D. ^{a,c}

^a Unidad de Ginecología, Hospital El Carmen Dr. Luis Valentín Ferrada, Camino Rinconada 1202 Maipú, 9274443 Santiago, Chile

^b Unidad de Piso Pélvico Femenino, Hospital Clínico Universidad de Chile, Dr. Carlos Lorca Tobar (ex Santos Dumont) 999 Independencia, 8380456 Santiago, Chile

^c Facultad de Medicina, Universidad Finis Terrae, Av. Pedro de Valdivia 1509 Providencia, 7501015 Santiago, Chile

^d Departamento de Ginecología y Obstetricia, Facultad de Medicina, Clínica Alemana – Universidad del Desarrollo, Av Plaza 680 Las Condes, 7610658 Santiago, Chile

ARTICLE INFO

Keywords:

Case report
Herpes simplex virus
Herpetic cervicitis
Cervical cancer

ABSTRACT

The case of a 20-year-old immunocompetent woman with necrotizing cervicitis of the cervix caused by a primary infection with herpes simplex virus type 2 is presented, along with its respective evolution in images. Cervical cancer was included in the differential diagnoses, but biopsies ruled out malignancy and laboratory tests demonstrated the viral etiology of the cervical inflammation. After initiating specific treatment, the cervical lesions completely healed within 3 weeks. This case highlights the need to consider herpes simplex infection in the differential diagnosis of cervical inflammation and tumor formation. Additionally, it provides images that can aid in diagnosis and allow for the observation of its clinical evolution.

1. Introduction

Herpes simplex virus (HSV) types 1 and 2 have a high prevalence in humans, producing a chronic and lifelong infection. Currently, it is estimated that up to two-thirds of the world's population is infected with HSV-1 and that 500 million individuals have an HSV-2 infection worldwide [1–3]. HSV is one of the most common sexually transmitted infections (STIs). Although ulcerative lesions are often the first sign of primary genital HSV infections, the initial presentation can suggest a wide range of diseases [4]. First-episode infections, on the acquisition of HSV, are usually more severe, with recurrent infections being milder. However, serological studies show that up to 25% of clinical first-episode infections are in fact first recognized recurrences, and their presentation often surprises the patient and physician [5,6]. First-episode infections are often accompanied by systemic symptoms, and up to 75% of primary infections go unrecognized by both the patient and the provider [7].

The case of a patient with an atypical presentation of HSV is reported here, in which a cervical tumor suggestive of cervical cancer was observed, with a necrotic surface, inflammatory exudate, and no skin signs of infection. Additionally, a sequence of images that reflect the evolution of cervical lesions during follow-up is shown.

2. CASE Presentation

A 20-year-old sexually active woman with no prior medical history or medication use, and a new male partner in the past 3 months, presented to the gynecology-obstetrics emergency unit with a 2-day history of pelvic pain, progressively increasing in intensity and associated with abnormal vaginal discharge. Additionally, the patient reported episodes of spotting in the last few days. The patient did not use any contraceptive methods and had never had a Pap smear.

The general physical examination was normal, with normal vital signs (temperature, heart rate, blood pressure, respiratory rate, and oxygen saturation). The gynecological examination showed no external genital lesions or abnormalities. The speculum examination revealed purulent vaginal discharge with streaks of blood, no apparent foul odor, and a solid, exudative, ulcerated, necrotic, and friable cervical tumor that was very sensitive to minimal contact with the speculum (Fig. 1). On vaginal examination, the cervix was mobile, very sensitive, with a solid consistency, irregular surface, and no apparent involvement of the parametria.

Due to the appearance of the cervix and the acute pain, the patient was hospitalized for further evaluation and management. Among the laboratory tests, the patient had a C-reactive protein (CRP) level of 43.9 mg/dL, a white blood cell count of $6.55 \times 10^9/L$, an erythrocyte sedimentation rate (ESR) of 18 mm/h, hemoglobin level of 13.0 g/dL, and

* Corresponding author at: Dr. Carlos Lorca Tobar (ex Santos Dumont) 999, Independencia, Santiago, Chile.

E-mail address: pablo.boldrini@usach.cl (P. Boldrini L.).

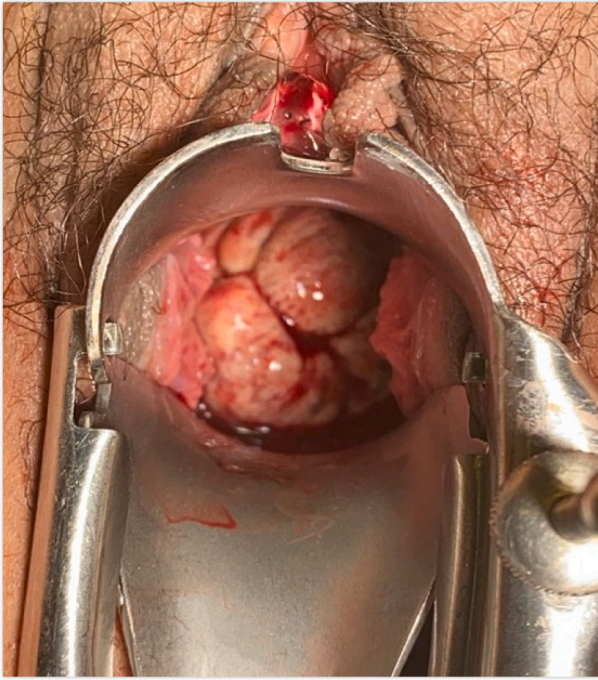


Fig. 1. Appearance of the patient's cervix at the time of the emergency unit consultation. It should be noted that the cervix was cleaned with a moist sterile gauze prior to the photograph being taken, which caused significant pain.

platelet count of $197 \times 10^9/L$. To rule out probable cervical malignancy, three specimens were obtained for histological examination using a Kevorkian cervical biopsy forceps, as the patient was intolerant to the procedure. Since the lesions did not appear to be cervical cancer on colposcopic evaluation and given the characteristics of the pain, empirical acyclovir and paracetamol were initiated, with ketoprofen reserved for pain relief, if necessary (indicated by a score >3 on a visual analog scale), and tests for sexually transmitted infections and vaginal discharge were requested. The appearance of the cervix improved significantly and there was a marked decrease in pain within 24–48 h of treatment. The patient was discharged to complete 7 days of treatment and then continued suppressive therapy with acyclovir, which was extended for 6 weeks. She had outpatient follow-up at 1, 3 and 6 weeks after hospital discharge (Fig. 2).

At the first week, there was significant clinical improvement in the appearance of the cervix and no pain (Fig. 2-B), a completely normal transvaginal ultrasound, negative tests for sexually transmitted infections, an inflammatory vaginal discharge study, and negative biopsy results for cancer, but with nonspecific acute inflammation. Tests for antibodies for HSV 1 and 2 were requested to confirm the etiology, 21 days after the onset of the clinical picture, and the results were positive for acute and active infection (Table 1). The patient showed complete normalization of the appearance of the cervix at 3 weeks (Fig. 2-C) and completed 6 weeks of follow-up, after which she was discharged from care. The timeline of the case is presented in Table 2.

3. Discussion

Although primary genital herpes simplex virus (HSV) infections typically present with cutaneous ulcerative lesions, the initial presentation is variable. The average incubation period after exposure to HSV is four days. Patients may present with systemic symptoms (i.e., fever, myalgias, malaise, and headache), vulvar pain, dysuria, ulcers, or painful lymphadenopathy. However, there are other, rare presentations, such as acute urinary retention and lumbosacral radiculopathy; the latter is mainly observed in immunocompromised patients [4–7]. The

most common cervical abnormalities associated with HSV infections are friability, ulcerative lesions, and cervicitis. It is therefore difficult to diagnose genital herpes based solely on clinical findings and the diagnosis should be confirmed by a laboratory or histological test.

The case of a young woman who presented with a painful cervical tumor and abnormal vaginal discharge as the initial manifestation of a primary genital herpes infection that initially suggested cervical cancer is presented here. There are few reports of primary HSV in immunocompetent patients that presented as a cervical tumor suggestive of cancer [8,9]. In none of the reported cases did the patients present with initial cutaneous or vulvar manifestations. However, there are more frequently reported cases in immunocompromised patients, specifically in patients with poorly controlled HIV [10,11].

There are two types of diagnostic methods: HSV detection or detection of specific antibodies to HSV-1 and HSV-2. Viral detection methods include viral culture and polymerase chain reaction (PCR) testing. Traditionally, the most commonly used test is viral culture due to its high specificity, wide availability, and relatively low cost. However, it has a low sensitivity in primary infections, with a false negative rate of up to 25% [4]. In the case of PCR, its availability has improved, and it has a sensitivity 1.5 to 4 times higher than culture; in addition, the samples are easier to obtain and more stable than for culture [12,13].

On the other hand, specific antibodies to HSV-1 and HSV-2 can also help establish the diagnosis. As mentioned, the incubation period is short, and by the time patients usually seek medical attention, ganglion infection has already occurred with the establishment of latency. Therefore, it is possible to detect antibodies against HSV-2 in the 2–12 weeks after acquisition of the infection, and they persist indefinitely [14]. The sensitivity of these tests for the detection of specific antibodies to HSV-2 ranges from 80% to 98%, and the specificity is 97–98% [14]. False negatives may be more frequent in the initial stages of the infection. In the case of IgM detection for HSV-1 and HSV-2, it should be noted that cross-elevations can occur. Likewise, for this diagnostic method, it is essential to consider that levels may be elevated by herpes from other sites or in recurrent genital herpes.

In the case presented, only antiviral serology could be determined since neither of the 2 viral detection techniques were available. Considering the levels of elevation of the HSV-2 antibodies and the absence of another compromised area, associated with the atypical clinical picture, absence of risk factors, and results of other tests, it is possible to state with confidence that this was a possible primary HSV-2 infection. The histopathological study has low sensitivity (it improves significantly when the sample is obtained from the skin with the characteristic vesicles), and only immunohistochemistry can differentiate between HSV-1, HSV-2, and Varicella-Zoster virus. In this case, it is highly probable that a representative sample was not obtained, as the patient's pain prevented >3 samples being taken and, as the initial objective was to rule out cancer, further samples were not taken under anesthesia. Additionally, PCR can be performed on biopsy samples, but this is very costly and, as mentioned, was anyway not available locally. Finally, the clinical evolution and the fact that only treatment with acyclovir was administered provide further support for the diagnosis.

Lastly, it should be noted that while our patient did not have cervical neoplasia, the literature tends to not support any association between HSV and cervical cancer.

4. Conclusion

In summary, a cervical tumor that simulates cancer is an atypical presentation of HSV, which can even be seen in immunocompetent patients. It is important to note that the manifestations of primary HSV infection are highly variable and to recognize this possible manifestation to diagnose and treat patients appropriately. Additionally, it is important to emphasize that while our patient did not have cervical neoplasia, the literature tends to not support any association between HSV and cervical cancer. Finally, follow-up images help in the diagnosis and to

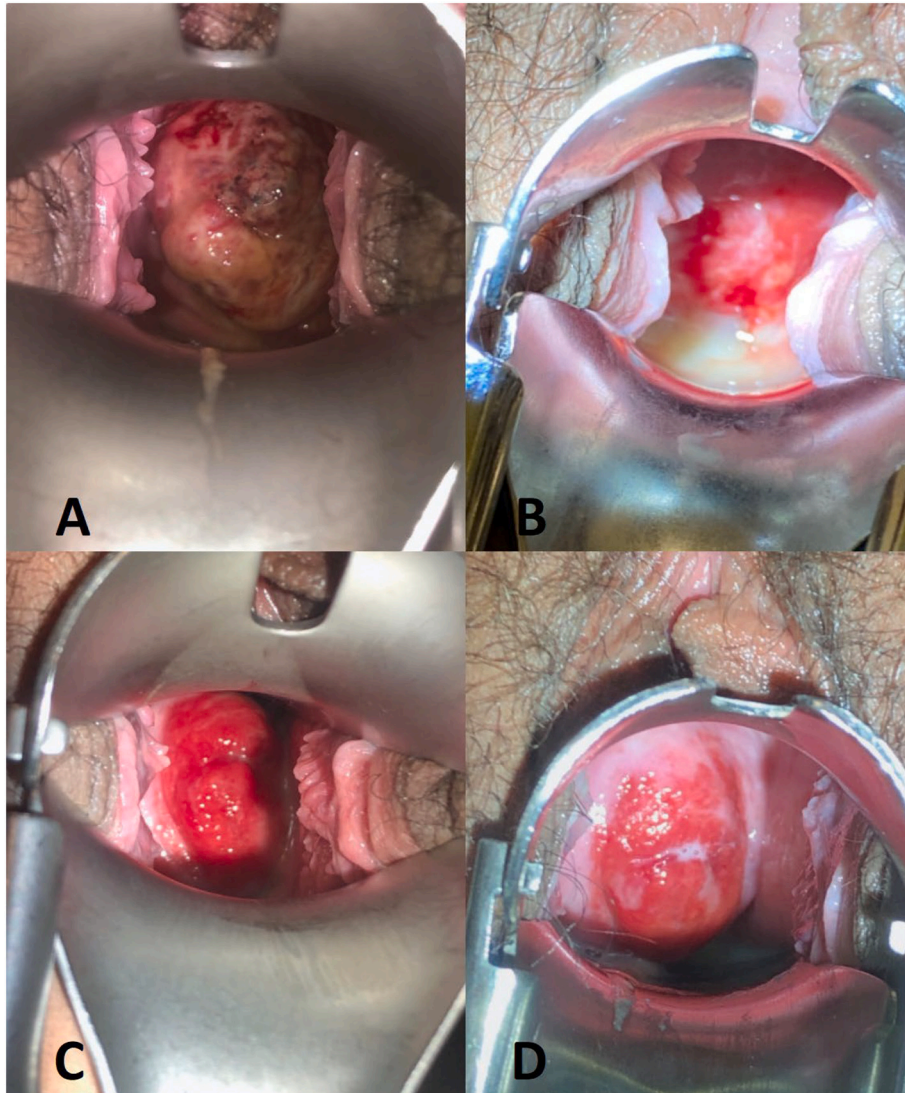


Fig. 2. Clinical evolution of cervicitis. (A),The cervix at 48 h and prior to hospital discharge. (B) At week 1, following treatment with acyclovir alone. The cervix shows significant recovery, with abundant exudate. (C) At 3-week follow-up, the cervix appears normal. (D) Six-week follow-up.

Table 1
Laboratory results.

| Day | Laboratory Test | Value | Unit |
|------------------------------------|-------------------------------------|-----------------------------|-----------------------|
| Day 1 | C-reactive protein | 43,9 | mg/dl |
| | White blood cell count | 6.550 | cells/mm ³ |
| | Erythrocyte sedimentation rate | 18 | mm/1 h |
| | Hemoglobin | 13,0 | g/dl |
| Day 1 | Platelet count | 197.000 | cells/mm ³ |
| | HIV 1 and 2 (ELISA test) | Non-reactive | |
| Day 2 | VDRL (Syphilis) | Non-reactive | |
| | Hepatitis B surface antigen | Negative | |
| Day 5 | Vaginal flow study | | |
| | - Leukocytes | Abundant amount | |
| | - Erythrocytes | Scant amount | |
| | - Bacteria | Moderate amount | |
| | - Descamative cells | Moderate amount | |
| | - Yeasts | Not observed | |
| | - Trichomonas | Not observed | |
| | - Fungal culture | No growth detected | |
| | - Standard culture | Normal bacterial microbiota | |
| | <i>Gardnerella vaginalis</i> (PCR) | Negative | |
| | <i>Mycoplasma hominis</i> (PCR) | Negative | |
| | <i>Mycoplasma genitalium</i> (PCR) | Negative | |
| | <i>Ureaplasma urealyticum</i> (PCR) | Positive | |
| | <i>Ureaplasma parvum</i> (PCR) | Negative | |
| <i>Chlamydia trachomatis</i> (PCR) | Negative | | |
| <i>Neisseria gonorrhoeae</i> (PCR) | Negative | | |
| Day 9 | Histological study* | Non-specific cervicitis | |
| Day 21 | ESR-1 IgM | 5,2 | UI/ml |
| Day 21 | ESR-1 IgG | 47,9 | UI/ml |
| | ESR-2 IgM | 97,1 | UI/ml |
| | ESR-2 IgG | > 200 | UI/ml |

PCR: polymerase-chain reaction; ESR: erythrocyte sedimentation rate.

* Corresponds to the date when the biopsy results were available.

Table 2
Timeline.

| Day | Description |
|--------|--|
| Day 0 | Patient consulted in the emergency department and was hospitalized due to acute pelvic pain associated with a tumoral-looking cervix. Septic condition was ruled out and biopsies were taken. |
| Day 1 | Due to low suspicion of cervical cancer on colposcopy, non-septic condition, nature of pain and lesion, probable herpes cervicitis was suspected and empirical therapy with acyclovir plus paracetamol was initiated. Transvaginal ultrasound was normal. Sexually transmitted infection tests were requested, with samples taken for HIV, VDRL and hepatitis B. |
| Day 2 | Patient was discharged without pain or vaginal discharge. Treatment with acyclovir was maintained. |
| Day 5 | Sample was taken for vaginal flow study and PCR for other STIs. Patient showed mild macroscopic improvement of the cervix and was pain-free |
| Day 9 | Patient was asymptomatic, with significant improvement of cervical lesions. STI tests were negative. Biopsy results were negative for cancer and showed non-specific cervicitis. Serology for HSV 1 and 2 was requested. Patient was kept on suppressive dose of acyclovir. |
| Day 21 | Sample was taken for HSV 1 and 2 serology. Complete normalization of the macroscopic aspect of the cervix. |
| Day 25 | Results consistent with acute and active VHS-2 infection were reported through serology. The patient was completely asymptomatic. |
| Day 42 | Completely asymptomatic patient with a normal-looking cervix. Suppressing therapy was discontinued and the patient was discharged. |

Timeline showing clinical findings, procedures performed, and laboratory results.

reveal the clinical evolution of the case.

Contributors

Pablo Boldrini López drafted and revised the manuscript and provided patient care.

Gabriel Vallejos Peñaloza revised the manuscript and prepared the tables.

Polente Ballesteros Polloni collected data and revised the manuscript.

Gonzalo Valenzuela Lantadilla collected data and revised the manuscript.

Enrique Roncone Ditzel revised the manuscript and provided patient care.

All authors approved the final manuscript.

Funding

No funding from an external source supported the publication of this case report.

Patient consent

Obtained.

Provenance and peer review

This article was not commissioned and was peer reviewed.

Conflict of interest statement

The authors declare that they have no conflict of interest regarding the publication of this case report.

References

- [1] K.J. Looker, G.P. Garnett, G.P. Schmid, An estimate of the global prevalence and incidence of herpes simplex virus type 2 infection, *Bull. World Health Organ.* 86 (2008) 805–812A.
- [2] P. Chayavichitsilp, J.V. Buckwalter, A.C. Krakowski, S.F. Friedlander, Herpes simplex, *Pediatr. Rev.* 30 (2009) 119–129 (quiz 30).
- [3] G. McQuillan, D. Kruszon-Moran, E.W. Flagg, R. Paulose-Ram, Prevalence of herpes simplex virus type 1 and type 2 in persons aged 14–49: United States, 2015–2016, *NCHS Data Brief* 304 (2018) 1–8.
- [4] American College of Obstetricians and Gynecologists, Gynecologic herpes simplex virus infections. *ACOG practice bulletin no. 57*, *Obstet. Gynecol.* 104 (2004) 1111–1117.
- [5] D.I. Bernstein, M.A. Lovett, Y.J. Bryson, Serologic analysis of first-episode nonprimary genital herpes simplex virus infection: presence of type 2 antibody in acute serum samples, *Am. J. Med.* 77 (1984) 1055–1060.
- [6] C. Diamond, S. Selke, R. Ashley, J. Benedetti, L. Corey, Clinical course of patients with serologic evidence of recurrent genital herpes presenting with signs and symptoms of first episode disease, *Sex. Transm. Dis.* 26 (1999) 221–225.
- [7] A.G. Langenberg, L. Corey, R.L. Ashley, W.P. Leong, S.E. Straus, A prospective study of new infections with herpes simplex virus type 1 and type 2. Chiron HSV vaccine study group, *N. Engl. J. Med.* 341 (1999) 1432–1438.
- [8] A. Tomkins, C. White, S.P. Higgins, Primary herpes simplex virus infection mimicking cervical cancer, *BMJ Case Reports* (2015), <https://doi.org/10.1136/bcr-2015-210194>.
- [9] C. Clure, C. Rivard, Primary herpes simplex virus infection mimicking a cervical malignancy in an immunocompetent individual, *Cureus* 10 (6) (2018), e2753, <https://doi.org/10.7759/cureus.2753>.
- [10] H. Ranu, J. Lee, M. Chio, P. Sen, Tumour-like presentations of anogenital herpes simplex in HIV-positive patients, *Int. J. STD AIDS* 22 (2011) 181–186, <https://doi.org/10.1258/ijsa.2010.010204>.
- [11] M. Mosunjac, J. Park, W. Wang, T. Tadros, M. Siddiqui, M. Bagirov, J. Little, Genital and perianal herpes simplex simulating neoplasia in patient with AIDS, *AIDS Patient Care STDs* 23 (2009) 153–158, <https://doi.org/10.1089/apc.2008.0143>.

- [12] M.J. Slomka, L. Emery, P.E. Munday, M. Moulds, D.W. Brown, A comparison of PCR with virus isolation and direct antigen detection for diagnosis and typing of genital herpes, *J. Med. Virol.* 55 (1998) 177–183.
- [13] A. Wald, M.L. Huang, D. Carrell, S. Selke, L. Corey, Polymerase chain reaction for detection of herpes simplex virus (HSV) DNA on mucosal surfaces: comparison with HSV isolation in cell culture, *J. Infect. Dis.* 188 (2003) 1345–1351.
- [14] R.L. Ashley, Sorting out the new HSV type-specific antibody tests, *Sex. Transm. Infect.* 77 (2001) 232–237.