



Discoid meniscus: current concepts

Manuel Saavedra¹
Matías Sepúlveda^{1,2,3}
María Jesús Tuca^{4,5,6}
Estefanía Birrer^{1,2}

- Discoid meniscus is the most frequent congenital malformation of the menisci, and primarily affects the lateral meniscus; it is highly prevalent in the Asian population.
- The anatomic, vascular, and ultrastructural features of the discoid meniscus make it susceptible to complex tears.
- Discoid meniscus anomalies are described according to their shape; however, there is consensus that peripheral stability of the meniscus should also be defined.
- Initial workup includes plain X-rays and magnetic resonance imaging, while arthroscopic evaluation confirms shape and stability of the meniscus.
- Clinical presentation is highly variable, depending on shape, associated hypermobility, and concomitant meniscal tears.
- Treatment seeks to re-establish typical anatomy using saucerization, tear reparation, and stable fixation of the meniscus.

Keywords: knee injuries; knee joint; magnetic resonance imaging; menisci; meniscus; tibia; X-rays

Cite this article: *EFORT Open Rev* 2020;5:371-379.

DOI: 10.1302/2058-5241.5.190023

Introduction

The meniscus plays a vital role in knee biomechanics. The discoid meniscus is a congenital variation of the meniscus shape, characterized by a central hypertrophy and a larger than normal diameter, leading to a lack of the characteristic 'C' configuration. The condition was initially described exclusively for the lateral meniscus in 1889 by Young, based on cadaveric studies.¹ Later, in 1930, Watson-Jones also described medial discoid meniscus, which is a very rare finding.² Lateral discoid meniscus is the most frequent anatomical variation, with an incidence in the United States varying from 3% to 5% and is present in up to 15% of Asian populations; however, there are numerous asymptomatic cases.³⁻⁵ Isolated cases of medial discoid

meniscus have been described, with an estimated incidence of 0.06%.⁶ Discoid meniscus in both knees has been described in between 15% and 25% of cases and is more common in the Asian population.^{4,7,8} Similarly, patients with bilateral discoid meniscus who require early surgical treatment have a higher risk of having a symptomatic discoid meniscus in the contralateral knee.⁹

Anatomy

Menisci are C-shaped fibrocartilaginous structures, with a triangular cross section, and cover up to two thirds of the tibial surface, which enlarges the contact surface with the femoral condyles. The meniscus comprises 75% water, 20% type I collagen, and 5% other substances, including elastin and proteoglycans. Each meniscus is attached to the subchondral bone of its respective tibial plateau through the anterior and posterior meniscal horns. The lateral meniscus is characteristically more circular, mobile, and smaller than the medial meniscus; however, proportionally, it covers a larger area of the articular surface. The posterior meniscal horn is fixed to the posterior cruciate ligament and the medial femoral condyle through the ligaments of Wrisberg (posterior meniscus-femoral ligament) and Humphrey (anterior meniscofemoral ligament).¹⁰ The main functions of the meniscus are load transmission, shock absorption, aiding joint stability, proprioception, and articular cartilage nutrition and lubrication.¹⁰

Fairbank was the first to describe the meniscus load transfer function when correlating degenerative changes of the knees subjected to total meniscectomy.¹⁰ Several studies have shown that the load is well distributed when the meniscus is intact, while a decrease of 40–50% in the contact area following total meniscectomy, with a consequent increase in stress load of 200–300%, has been described.¹¹

The menisci differentiate from the mesenchymal tissue in the eighth week of gestation, and by week 14 they have their mature anatomical form.¹² Originally, it was

considered likely that the discoid meniscus was the product of an arrest in normal development; however, this form does not occur at any stage during typical embryonic development.¹³ Kaplan, in an analysis of human and animal fetuses, did not identify discoid menisci as a stage during development and was the first to propose that the discoid form is due to a deficit in the posterior meniscofemoral fixation (Wrisberg).¹⁴ Although Kaplan's theory does not explain the existence of discoid menisci with normal posterior femoral fixation, it is established that there is a synergy between discoid shape and instability.¹⁵ The meniscus is completely vascularized at birth, with progressive decline until age 10 years, at which point only the most peripheral third of the meniscus is vascularized.^{13–16} Discoid menisci have less vascularization in the periphery than those with normal shape.⁶

The ultrastructure of the discoid meniscus is characterized by lower collagen density, with a disorganized network that predisposes it to breakage.¹⁷ Histologically, the discoid meniscus presents mucinous alterations, similar to those found in degenerative menisci.⁶

Classification

In 1969, Watanabe et al classified lateral discoid menisci based on appearance and stability to arthroscopy.¹⁸ Type I has a complete discoid shape, with full coverage of the tibial plate, and is mechanically stable and palpable, with normal posterior coronal insertions. Type II has a half-moon shape, reminiscent of a normal-shaped meniscus, with incomplete coverage of no more than 80% of the tibial surface and is stable to palpation. Type III (the Wrisberg variant) usually presents with a normal or slightly discoid shape and is characterized by instability caused by the absence of its posterior coronal fixation, with only its meniscofemoral junction (Wrisberg's ligament) maintained, inserted in the posterior meniscal horn (Fig. 1).

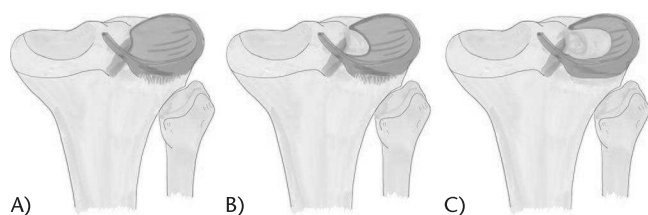


Fig. 1 Watanabe classification for lateral discoid meniscus. (A) Type I, complete discoid shape, with full coverage of the tibial plate, mechanically stable, with normal posterior coronal insertions. (B) Type II, incomplete coverage of no more than 80% of the tibial surface, stable to palpation, with normal posterior coronal insertions. (C) Type III (Wrisberg variant), normal or slightly discoid shape, with instability due to absence of posterior coronal fixation, only Wrisberg's ligament maintained.

Although widely accepted, Watanabe's classification has lost clinical relevance over time, since it does not categorize shape, presence of ruptures, and stability simultaneously. Jordan et al made the observation that Watanabe type I and II menisci do not usually cause symptoms until a tear occurs, and that discoid meniscus type III are most strongly associated with joint block, concluding that it is more relevant to classify menisci as stable versus unstable, independent of macroscopic morphology.^{19,20} In contrast, the coronal instability associated with discoid meniscus can be both anterior and middle third, even more frequently than the classic posterior instability described by Watanabe.²¹

Ahn et al proposed a magnetic resonance imaging (MRI)-based classification system that categorizes discoid menisci according to their peripheral stability and subsequent displacement, expecting to provide surgeons with more information in choosing the appropriate treatment. They reviewed 76 preoperative MRIs, and findings were classified according to four categories: no shift, anterocentral shift, posterocentral shift, and central shift. Results showed that shift-type knees were less frequent (43% of the sample), but had a significantly larger number of peripheral tears, and repairs were performed more frequently than in the no-shift-type knees.²²

Considering the above information, current recommendations are to grade discoid menisci according to discoid morphology (complete vs. incomplete), peripheral stability (stable vs. unstable), and the presence or absence of meniscal tears.

Presentation and clinical evaluation

As previously mentioned, discoid menisci are usually asymptomatic unless they are unstable or torn.^{21,23} Presentation is variable in intensity and duration, and depends on the type of rupture, the degree of peripheral instability, and the activity and age of the patient. In children, there is frequently no history of previous trauma and the progression of the symptoms is insidious. Regarding frequency, it is more common that the cause of clinical signs is a meniscal tear.²⁰

Disorganized collagen network, mucinous degeneration, and lack of vascularization make discoid menisci prone to tears, even in the absence of trauma.²⁴ In addition, authors have suggested that a larger meniscal size would be a predisposing factor for tears in discoid-shaped meniscus.^{25,26} Unlike traumatic tears in normal menisci, the most common tear patterns in discoid menisci are complex degenerative tears, and bucket-handles.²⁷

When there is instability, abnormal intra-articular displacements occur in the discoid meniscus. Displacements of the unstable discoid meniscus can be towards the intercondylar notch or towards the periphery, causing painful

protrusion during flexion and extension or joint blockage.^{3,28,29} Additionally, femorotibial clusters can be produced, generating areas of stress and tears within the meniscus.²⁴ A meniscal tear produces edema and pain; however, it can also cause instability, particularly if it occurs in the posterior horn.³⁰ The unstable, broken, or subluxated meniscus loses its ability to absorb impact and distribute load. Patients with pain due to a meniscal tear of more than six months of evolution have twice the risk of presenting with associated cartilage lesions.³¹

Physical examination of a painful knee begins with inspection of the gait and axes of the lower extremities. It is also convenient to look for asymmetries of the quadriceps and joint effusion, which may be present in acute tears. Upon palpation, pain can be located to the lateral joint line, accompanied by an increase in volume at flexion. Range of motion must be carefully examined, since movement may be painful, clicking, protruding, or even restricted in the presence of an unstable or torn discoid meniscus.¹³

Children with discoid meniscus sometimes have difficulty performing provocative manoeuvres and, while their predictive value is variable, we recommend including them in routine examination. The McMurray manoeuvre is 98% specific for meniscal injury.³² It is performed with the patient in the supine position; the examiner holds the knee and palpates the joint line with one hand, thumb on one side and fingers on the other, whilst the other hand holds the sole of the foot and acts to support the limb and provide the required movement. From a position of maximal flexion, the knee is extended with internal rotation of the tibia and a varus stress, then returned to maximal flexion and the knee is extended with external rotation of the tibia and a valgus stress. The Apley test is performed in the prone position, by rotation of the knee while the examiner applies axial pressure. The Thessaly test is performed with the patient standing up, with the knee in flexion and unipodal load. The patient then alternately rotates the examined knee. The result is positive when it elicits pain referred to the lateral joint line. This manoeuvre has a precision of 96% for lateral meniscus tears.³³ Further, a combination of the findings from different physical examinations increases the probability of making a correct diagnosis.³⁴

Imaging study

First-line examinations in patients with suspected discoid meniscus are plain X-rays of the knee; anteroposterior and lateral views. Although the main purpose of X-rays is to rule out differential diagnoses, such as fractures, tumours, or osteochondritis dissecans, there are also characteristic features that suggest the presence of a discoid meniscus.³⁵ The classic findings in lateral discoid meniscus are femoral

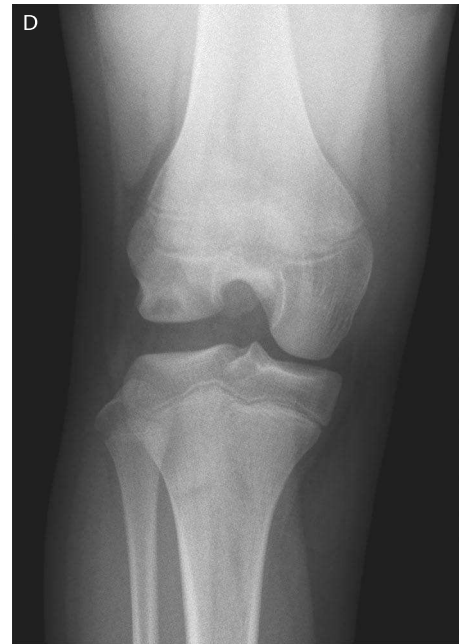

Fig. 2 Anteroposterior non-weight-bearing plain X-ray of right knee of a 12-year-old girl, symptomatic of a lateral discoid meniscus. ‘Squaring’ of the femoral condyle, increase in the joint space, and changes (‘cupping’) in the lateral tibial plateau are visible.

condyle with a block shape (‘squaring’), increased concavity of the tibial plateau, acquiring the shape of a cup, an increase in the joint space to > 11 mm, and hypoplasia of the lateral tibial spine (Fig. 2).³⁶ Ha et al estimated that the positive predictive value of these signs in children aged 10–16 years is of 76.2% (sensitivity, 65.3%; specificity, 79.6%).³⁷ Additionally, they described an association between severity in clinical presentation and cases where radiological signs were more evident.

MRI assessment is fundamental for confirming the diagnosis and preoperative planning, since it allows characterization of the meniscal shape, associated tears, stability, and concomitant injuries.³⁸ The following diagnostic criteria were described by Silverman et al in 1989: (a) presence of a band from anterior to posterior in the mid-meniscus area, with three contiguous sections measuring ≥ 5 mm in thickness; (b) upper-lower height in the augmented mid-zone generating a bowtie shape in the sagittal view; and (c) differences in size between the anterior and posterior horn, which are usually symmetrical. Additionally, coronal sections show (d) a complete meniscus in all sections from anterior to posterior through the knee, which is normally only present in the anterior and posterior sections; and (e) an increase in transverse diameter > 15 mm (Fig. 3 and Fig. 4).^{39,40} It is possible that these criteria are not observed in incomplete discoid menisci, or those described as type II and III in the Watanabe

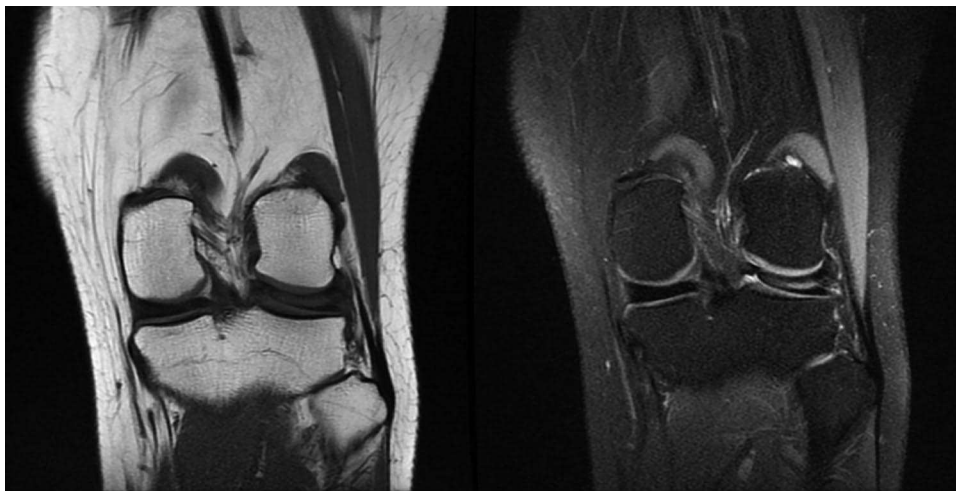


Fig. 3 Magnetic resonance imaging (MRI) coronal views of the knee of a 15-year-old girl. T1 (left) and FAT SAT (right) showing a lateral discoid meniscus with a concomitant horizontal tear.

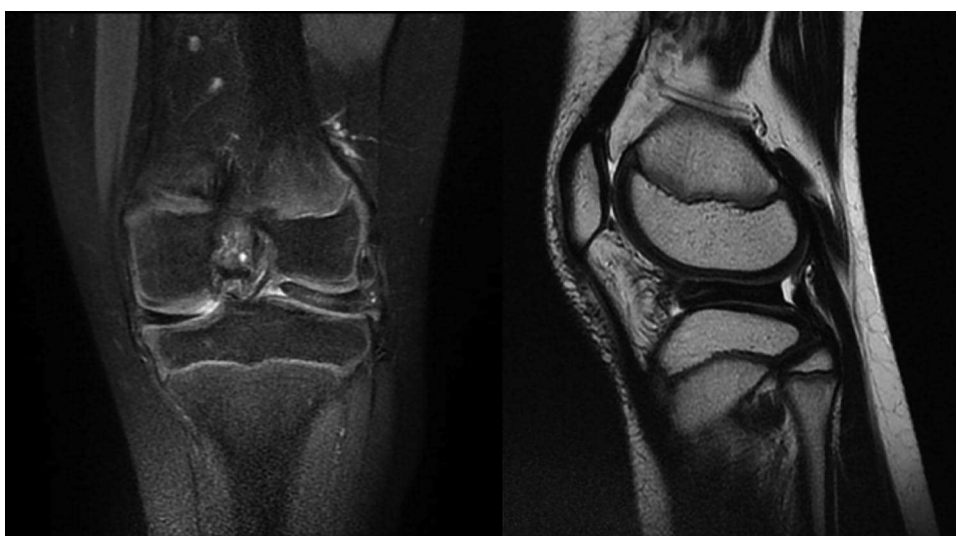

Fig. 4 Magnetic resonance imaging (MRI) of the knee of a 9-year-old girl, with a history of a snapping left knee. FAT SAT Coronal (left) and T2 Sagittal (right) MRI views show a complete discoid meniscus with intrasubstance degenerative changes.

classification, and they must be considered in the context of clinical findings. MRI signs of peripheral instability are: absence of capsular insertions (absence of normal observable fascicles; T2 signal increase, due to lack of coronal ligaments which simulates peripheral rupture) and anterior displacement of the posterior horn of the meniscus relative to the tibia (meniscus subluxation).⁴¹

Hamada et al determined that MRI can be used to visualize meniscal degeneration and intrasubstance breaks that are not usually detected by arthroscopy.³⁰ In contrast, Kocher et al observed that the sensitivity and specificity of MRI is not superior to clinical evaluation for diagnosis.⁴² They also reported that MRI has a significantly lower

sensitivity (61.7% vs. 78.2%) and specificity (90.2% vs. 95.5%) for children under 12 years old, relative to those between 12 and 16 years old.

Treatment

There is a broad consensus that most patients with discoid meniscus will not present with symptoms, since the knee eventually adapts to the anatomy, maintaining good function.³⁸ Hence, a significant number of patients will not require treatment, even in the presence of occasional symptoms, such as a non-painful bulge in the lateral aspect of their knee.^{24,27,36} Likewise, no benefit has been

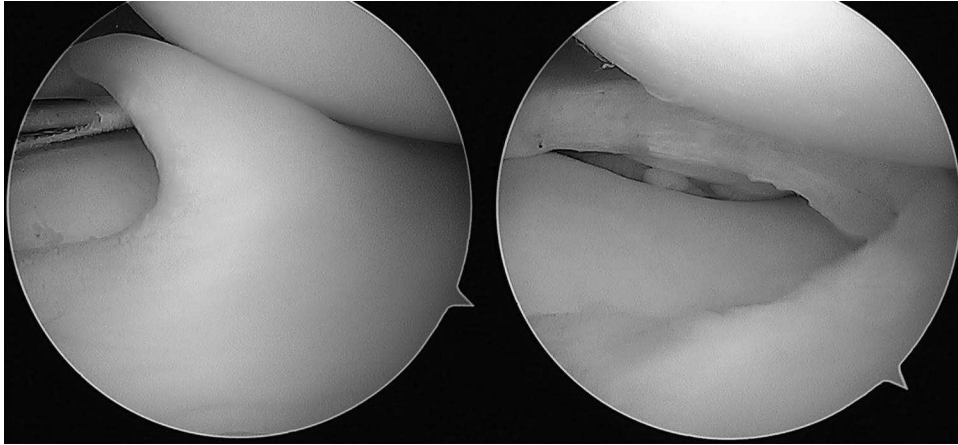


Fig. 5 Arthroscopic image of the knee of a 12-year-old boy, with a symptomatic discoid meniscus. A complete lateral discoid meniscus, without evidence of tears or instability (left), that underwent arthroscopic saucerization, leaving a stable meniscus with a peripheral rim of 8 mm (right).

demonstrated in performing surgical treatment of the asymptomatic contralateral knee while undertaking surgery of the symptomatic side.^{35,43} There are no long-term studies describing the natural evolution of the asymptomatic discoid meniscus without surgical treatment; hence, the only current recommendation is observation.²⁴ Consequently, asymptomatic patients can resume normal activities, while highlighting to patients and their parents that prompt medical evaluation must be obtained in case of symptoms related to the knee.

Surgical treatment is recommended where there are persistent symptoms, such as pain, blockage, edema, or limitation of sports activities, attributable to discoid meniscus.⁴⁴ Given the known importance of the meniscus to knee function, and the fact that its absence triggers early degenerative changes, attempts to preserve the structure are an absolute priority. This emphasizes the importance of timely intervention and the availability of technical capacity to repair the meniscus, while minimizing damage. From the biomechanical perspective, in the lateral compartment of the knee, 70% of the load is transmitted through the meniscus; therefore, in its absence, the forces that are transmitted to the joint surface increase by up to 200%.^{45,46}

Traditionally, a total, open, or arthroscopic meniscectomy was performed, since it was estimated that the remaining meniscus had a high rate of intrinsic abnormalities, either due to degeneration or lack of stability.⁴⁷ In a comparison of 38 cases of operated knees, Davidson et al reported that patients who underwent total resection had better results after one year of follow-up; however, there is a direct correlation between total meniscectomy and progression to osteoarthritis over time and the reported results were too early to have detected this.^{11,38,48–50} Although the comparison of progression to osteoarthritis of a healthy knee with a discoid meniscus remains a

matter of debate, it is now recommended to avoid this procedure in the paediatric population, orienting towards meniscal preservation whenever possible.²⁰

Currently, the main goal of treatment is to preserve a stable meniscus with an anatomy as close as possible to that of a normal meniscus. Aiming to maintain its function of absorbing and distributing loads, partial meniscectomy, with reshaping or meniscal saucerization, consists of removal of the central portion of the meniscus, restoring its 'C' shape (Fig. 5).^{51–53} Okazaki et al reported that good long-term levels of function are effectively maintained using this procedure.⁵⁴ If the meniscus presents peripheral instability, when possible, it should be associated with peripheral repair. Two studies compare saucerization alone or associated with fixation, and although both procedures have good long-term results overall, there is a slight but significant functional advantage and less degenerative changes in the knee of patients in whom the stability of the meniscus has been restored.^{50,55} However, the progression of degenerative changes in the cartilage or the meniscus is not directly associated with these long-term results, and probably the most important factor is the age of the patient at the time of surgery, with significantly lower expectations over 30 years old.^{54,56}

When conducting arthroscopic treatment of a discoid meniscus, the steps are as follows: (1) observation and diagnosis of the meniscus shape (complete vs. incomplete), stability, and associated tears; (2) meniscal carving, seeking to preserve the greatest amount of meniscus and emulating a normal meniscus shape; (3) repair with sutures those tears that are amenable; and finally (4) confirm the peripheral stability of the meniscus, and fix if unstable (Fig. 6).

Visualization can be particularly difficult in complete discoid meniscus, and care should be taken to avoid

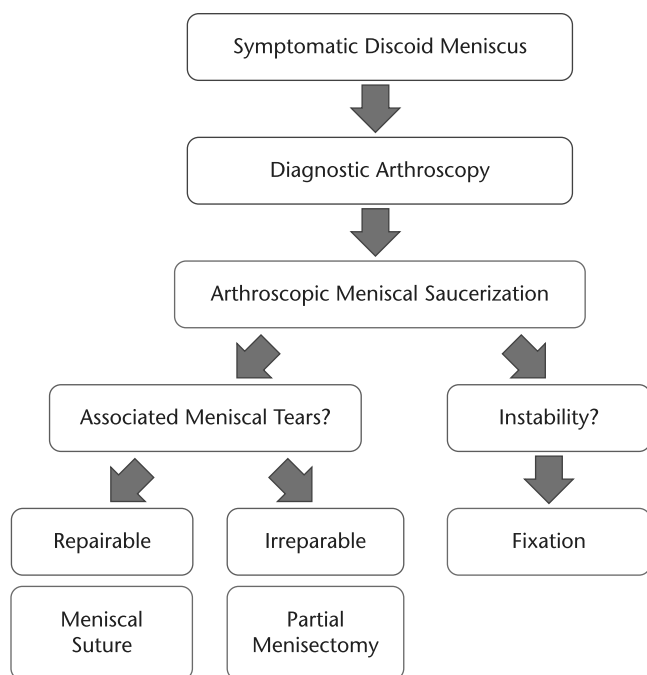


Fig. 6 Treatment algorithm for symptomatic discoid meniscus, investigated using magnetic resonance imaging (MRI).

removing too much meniscal tissue or damaging the anterior root attachment. The surgeon must carefully assess the peripheral rim during saucerization. The recommendation is to leave an intact peripheral rim of at least 6–8 mm.²⁴

During identification of peripheral detachments, it is important to consider that instability can occur anywhere from the anterior to posterior horns of the meniscus.⁵⁷ Regarding meniscal tears, to decide whether or not to repair, a surgeon must consider the location and extent of the tear, since this will determine healing potential, and the tear pattern, as complete multidirectional tears or radial tears may be irreparable. Further, repairing with sutures can be technically challenging in paediatric knees, and surgeons can combine all-inside, outside-in, and inside-out techniques, to achieve stable fixation.^{27,38}

Once saucerization and tear repair have been performed successfully, peripheral fixation must be conducted for unstable hypermobile discoid menisci.^{20,24,50,57} Fixation to the capsule can be achieved with sutures, where none of the above-mentioned techniques have been proven to be superior. Recently, Steinbacher et al reported 46 patients with hypermobile discoid meniscus repaired with all-inside sutures, with a return to competitive sports activity in 82%.⁵⁸

Different suture techniques have been described for either meniscal repair or peripheral fixations. As mentioned above, none has proven to yield superior outcomes, thus the decision is mainly based on the location

of the tear, costs, availability and the surgeon’s preference. For tears or detachments limited to the anterior portion of the meniscus, the outside-in suturing technique is the most frequently used.²⁴ For tears or detachments located in the body or posterior horn, the inside-out suturing technique was the first to be described for arthroscopic repair, and it is still considered to be the gold standard.⁵⁹ Inside-out repairs of the lateral meniscus require a posterolateral incision, developing a plane between the iliotibial band and the biceps tendon, retracting the lateral head of gastrocnemius posteriorly. Gunes et al compared inside-out versus last-generation all-inside fixations for meniscal repair of the posterior horn, reporting that they were at least equivalent in strength.⁶⁰ To date, all-inside devices are the most commonly used suturing technique for tears located in the body and posterior horn of the meniscus. They were designed to reduce surgical time and avoid external approaches, yet are not always available due to their higher cost. Moreover, the all-inside suturing technique can be technically challenging, especially in paediatric patients with smaller knees.²⁴ Cadaveric and MRI-based studies have demonstrated the close proximity of neurovascular structures to the posterior horn of the lateral meniscus in children, advising that special care should be taken when using all-inside devices for meniscal repair in paediatric knees.^{61,62} Our recommendation is to avoid aiming the all-inside device from the antero-lateral portal to the posterior horn of the lateral meniscus, and, if needed, make sure to limit the penetration depth.

Despite the overwhelming evidence highlighting the importance of meniscal preservation and the therapeutic approaches derived from this concept, repair is not always possible, requiring total or subtotal meniscectomies in those with severely damaged discoid menisci. Meniscal allograft transplantation has been proposed as a valid alternative in young patients with symptoms derived from a total or subtotal meniscal deficits, the so-called post meniscectomy syndrome.⁶³ Regardless of the variability of techniques for meniscal transplantations, the overall rate of reported functional improvement at 7–14 years is 70%, with a failure rate close to 10%.⁶⁴ In the adult population, Yoon et al compared this procedure among patients with meniscal deficit due to a discoid meniscus versus other causes, finding similar positive results.⁶⁵ Further, in a two-year follow-up of seven paediatric patients (average age, 12.3 years) with open (57%) and closed (43%) physis, Kocher et al reported satisfaction comparable to the adult population, as well as safety of the procedure when not observing residual alterations in growth.⁶⁶ Although with a higher average age, other authors have also previously reported similar results in populations under 21 years old.^{67,68}

Meniscal allograft transplantation is currently considered to be indicated in young or middle-aged patients with persistent pain, secondary to total or subtotal meniscectomy,

Table 1. Summarized outcomes for discoid meniscus surgical treatment

Study	No. of patients	Mean age (range)	Procedure	Mean follow-up and results
Okazaki <i>et al</i> ⁵⁴ 2006	27 (29 knees)	17.9 (6–55)	Saucerization	At 16 years: IKDC 82 90 with age 25 or less 72 with age 30 or more
Carter <i>et al</i> ⁵⁵ 2012	51 (57 knees)	11.7 (not available)	Group A (30) Saucerization and stabilization Group B (27) Saucerization	At 15 months: Lysholm 94 (A) vs. 89 (B) IKDC 86 (A) vs. 82 (B) Tegner activity level 7 (A) vs. 6 (B)
Ahn <i>et al</i> ⁵³ 2015	38 (48 knees)	9.9 (8–14)	Group A (22) Saucerization and stabilization Group B (18) Saucerization Group C (8) Partial meniscectomy	At 10.1 years: Ikeuchi 94% good/excellent results Lysholm improves from 74.9 to 97.6 HSS improves from 80.8 to 97.8 Tegner activity level 7 Degenerative changes on X-ray: 23% in group A, 39% in group B, 88% in group C
Lee <i>et al</i> ⁶⁹ 2016	20 (21 knees)	15.3 (5–38)	Saucerization	At 6.8 years: Lysholm 85.8 points Degenerative progression in remnant meniscus and femorotibial cartilage in MRI
Lee <i>et al</i> ⁵⁶ 2017	66 (73 knees)	22.2 (3–40)	Saucerization	At 10 years: Ikeuchi 64% with good/excellent results Lysholm 84.2 + 14.5 Re-operation rate 32.9% 54% degenerative changes on X-ray

Note. IKDC, International Knee Documentation Committee Subjective Knee Form; HSS, Hospital for Special Surgery Knee Score MRI, magnetic resonance imaging.

with a stable and well-aligned knee, without advanced chondral damage.⁶⁴ There is no consensus that patients would benefit from prophylactic meniscal allograft transplantation in cases of asymptomatic meniscal deficit.

Summarized literature outcomes for discoid meniscus surgical treatments are presented in Table 1.^{53-56, 69}

Rehabilitation

Postoperative programmes are dependent on surgeons' preferences, patient age, and the need for meniscal repairs or reattachments. Our preference for patients undergoing an isolated discoid meniscus saucerization is to allow immediate total weight-bearing. Physical therapy is started after two weeks, with gradual return to sports after eight weeks. Patients with a meniscal repair are instructed to begin partial weight-bearing with two crutches, and a hinged brace with range of movement limited from 0° to 30° for the first six weeks. Full weight-bearing and progressive free range of movement is allowed at six weeks postoperatively. Physical therapy begins after two weeks postoperatively and return to sports depends on the patient's movement and strength recovery, usually after 12 weeks. In younger patients, under the age of 6 years, a straight knee immobilizer is prescribed for four weeks postoperatively.

Conclusions

Evaluation of the shape and stability of a symptomatic discoid meniscus should be the basis for treatment decision.

This is performed through arthroscopic evaluation. After meniscal saucerization, associated meniscal tears and instability should be evaluated to determine the need for repair. Further studies should focus on long-term results and development of new techniques for transplantation.

AUTHOR INFORMATION

¹Universidad Austral de Chile, Valdivia, Chile.

²AO Foundation, PAEG Expert Group, Davos, Switzerland.

³Hospital Base de Valdivia, Valdivia, Chile.

⁴Clinica Alemana, Santiago, Chile.

⁵Universidad del Desarrollo, Santiago, Chile.

⁶Hospital Clínico Mutual de Seguridad, Santiago, Chile.

Correspondence should be sent to: Matías Sepúlveda, Yungay 773, App 501, Valdivia, Chile.

Email: contacto@matiassepulveda.com

ACKNOWLEDGEMENTS

The authors would like to acknowledge the help provided by the Vicerrectoría de Investigación, Desarrollo y Creación Artística and Escuela de Graduados Facultad de Medicina of the Universidad Austral de Chile in order to publish this work.

ICMJE CONFLICT OF INTEREST STATEMENT

The authors declare no conflict of interest relevant to this work.

FUNDING STATEMENT

No benefits in any form have been received or will be received from a commercial party related directly or indirectly to the subject of this article.

LICENCE

© 2020 The author(s)

This article is distributed under the terms of the Creative Commons Attribution-Non Commercial 4.0 International (CC BY-NC 4.0) licence (<https://creativecommons.org/licenses/by-nc/4.0/>) which permits non-commercial use, reproduction and distribution of the work without further permission provided the original work is attributed.

REFERENCES

- Young RB.** The external semilunar cartilage as a complete disc. In: Cleland J, Mackay JY, Young RB, eds. *Memoirs and memoranda in anatomy*. London, England: Williams and Norgate, 1889:179.
- Jones RW.** Specimen of internal semilunar cartilage as a complete disc. *Proc R Soc Med* 1930;23:1588–1589.
- Jordan MR.** Lateral meniscal variants: evaluation and treatment. *J Am Acad Orthop Surg* 1996;4:191–200.
- Ikeuchi H.** Arthroscopic treatment of the discoid lateral meniscus: technique and long-term results. *Clin Orthop Relat Res* 1982;167:19–28.
- Kim SJ, Lee YT, Kim DW.** Intraarticular anatomic variants associated with discoid meniscus in Koreans. *Clin Orthop Relat Res* 1998;356:202–207.
- Nathan PA, Cole SC.** Discoid meniscus: a clinical and pathologic study. *Clin Orthop Relat Res* 1969;64:107–113.
- Bae JH, Lim HC, Hwang DH, Song JK, Byun JS, Nha KW.** Incidence of bilateral discoid lateral meniscus in an Asian population: an arthroscopic assessment of contralateral knees. *Arthroscopy* 2012;28:936–941.
- Kato Y, Oshida M, Aizawa S, Saito A, Ryu J.** Discoid lateral menisci in Japanese cadaver knees. *Mod Rheumatol* 2004;14:154–159.
- Patel NM, Cody SR, Ganley TJ.** Symptomatic bilateral discoid menisci in children: a comparison with unilaterally symptomatic patients. *J Pediatr Orthop* 2012;32:5–8.
- Fairbank TJ.** Knee joint changes after meniscectomy. *J Bone Joint Surg Br* 1948;30B:664–670.
- Fox AJS, Wanivenhaus F, Burge AJ, Warren RF, Rodeo SA.** The human meniscus: a review of anatomy, function, injury, and advances in treatment. *Clin Anat* 2015;28:269–287.
- Gardner E, O’Rahilly R.** The early development of the knee joint in staged human embryos. *J Anat* 1968;102:289–299.
- Clark CR, Ogden JA.** Development of the menisci of the human knee joint: morphological changes and their potential role in childhood meniscal injury. *J Bone Joint Surg Am* 1983;65:538–547.
- Kaplan EB.** Discoid lateral meniscus of the knee joint; nature, mechanism, and operative treatment. *J Bone Joint Surg Am* 1957;39-A:77–87.
- Yaniv M, Blumberg N.** The discoid meniscus. *J Child Orthop* 2007;1:89–96.
- Arnoczky SP, Warren RF.** Microvasculature of the human meniscus. *Am J Sports Med* 1982;10:90–95.
- Atay OA, Pekmezci M, Doral MN, Sargon MF, Ayvaz M, Johnson DL.** Discoid meniscus: an ultrastructural study with transmission electron microscopy. *Am J Sports Med* 2007;35:475–478.
- Watanabe M, Takeda SJ, Ikeuchi HJ.** *Atlas of arthroscopy*. Second ed. Tokyo, Japan: Igaku-Shoin Ltd, 1969.
- Jordan MR, Duncan JB, Bertrand SL.** Discoid lateral meniscus: a review. *J South Orthop Assoc* 1993;2:239–253.
- Jordan MR.** Lateral meniscal variants. *Oper Tech Orthop* 2000;10:234–244.
- Klinge KE, Kocher MS, Hresko MT, Gerbino P, Micheli LJ.** Discoid lateral meniscus: prevalence of peripheral rim instability. *J Pediatr Orthop* 2004;24:79–82.
- Ahn JH, Lee YS, Ha HC, Shim JS, Lim KS.** A novel magnetic resonance imaging classification of discoid lateral meniscus based on peripheral attachment. *Am J Sports Med* 2009;37:1564–1569.
- Andrish JT.** Meniscal injuries in children and adolescents: diagnosis and management. *J Am Acad Orthop Surg* 1996;4:231–237.
- Kocher MS, Logan CA, Kramer DE.** Discoid lateral meniscus in children: diagnosis, management, and outcomes. *J Am Acad Orthop Surg* 2017;25:736–743.
- Ayala JD, Abril JC, Magán L, Epeldegui T.** Discoid meniscus: prognostic significance of meniscal thickness. *Rev Esp Cir Ortop Traumatol* 2004;48:195–200.
- Masquijo JJ, Bernocco F, Porta J.** Discoid meniscus in children and adolescents: correlation between morphology and meniscal tears. *Rev Esp Cir Ortop Traumatol* 2019;63:24–28.
- Kocher MS, Klingele K, Rassman SO.** Meniscal disorders: normal, discoid, and cysts. *Orthop Clin North Am* 2003;34:329–340.
- Dickhaut SC, DeLee JC.** The discoid lateral-meniscus syndrome. *J Bone Joint Surg Am* 1982;64:1068–1073.
- Yoo WJ, Choi IH, Chung CY, et al.** Discoid lateral meniscus in children: limited knee extension and meniscal instability in the posterior segment. *J Pediatr Orthop* 2008;28:544–548.
- Hamada M, Shino K, Kawano K, Araki Y, Matsui Y, Doi T.** Usefulness of magnetic resonance imaging for detecting intrasubstance tear and/or degeneration of lateral discoid meniscus. *Arthroscopy* 1994;10:645–653.
- Lau BC, Vashon T, Janghala A, Pandya NK.** The sensitivity and specificity of preoperative history, physical examination, and magnetic resonance imaging to predict articular cartilage injuries in symptomatic discoid lateral meniscus. *J Pediatr Orthop* 2018;38:e501–e506.
- Evans PJ, Bell GD, Frank C.** Prospective evaluation of the McMurray test. *Am J Sports Med* 1993;21:604–608.
- Karachalios T, Hantes M, Zibis AH, Zachos V, Karantanas AH, Malizos KN.** Diagnostic accuracy of a new clinical test (the Thessaly test) for early detection of meniscal tears. *J Bone Joint Surg Am* 2005;87:955–962.
- Fowler PJ, Lubliner JA.** The predictive value of five clinical signs in the evaluation of meniscal pathology. *Arthroscopy* 1989;5:184–186.
- Kushare I, Klingele K, Samora W.** Discoid meniscus: diagnosis and management. *Orthop Clin North Am* 2015;46:533–540.
- Kramer DE, Micheli LJ.** Meniscal tears and discoid meniscus in children: diagnosis and treatment. *J Am Acad Orthop Surg* 2009;17:698–707.
- Ha CW, Jang JW, Kim M, Na SE, Lee HJ, Park YB.** The utility of the radiographic condylar cut-off sign in children and adolescents with complete discoid lateral meniscus. *Knee Surg Sports Traumatol Arthrosc* 2017;25:3862–3868.
- Ahn JH, Shim JS, Hwang CH, Oh WH.** Discoid lateral meniscus in children: clinical manifestations and morphology. *J Pediatr Orthop* 2001;21:812–816.
- Silverman JM, Mink JH, Deutsch AL.** Discoid menisci of the knee: MR imaging appearance. *Radiology* 1989;173:351–354.

- 40. Araki Y, Ashikaga R, Fujii K, et al.** MR imaging of meniscal tears with discoid lateral meniscus. *Eur J Radiol* 1998;27:153–160.
- 41. Singh K, Helms CA, Jacobs MT, Higgins LD.** MRI appearance of Wrisberg variant of discoid lateral meniscus. *AJR Am J Roentgenol* 2006;187:384–387.
- 42. Kocher MS, DiCanzio J, Zurakowski D, Micheli LJ.** Diagnostic performance of clinical examination and selective magnetic resonance imaging in the evaluation of intraarticular knee disorders in children and adolescents. *Am J Sports Med* 2001;29:292–296.
- 43. Kim JG, Han SW, Lee DH.** Diagnosis and treatment of discoid meniscus. *Knee Surg Relat Res* 2016;28:255–262.
- 44. Wong T, Wang CJ.** Functional analysis on the treatment of torn discoid lateral meniscus. *Knee* 2011;18:369–372.
- 45. Seedholm BB, Dowson D, Wright V.** Functions of the menisci: a preliminary study. *J Bone Joint Surg Br* 1974;56-B:381–382.
- 46. Baratz ME, Fu FH, Mengato R.** Meniscal tears: the effect of meniscectomy and of repair on intraarticular contact areas and stress in the human knee: a preliminary report. *Am J Sports Med* 1986;14:270–275.
- 47. Aichroth PM, Patel DV, Marx CL.** Congenital discoid lateral meniscus in children: a follow-up study and evolution of management. *J Bone Joint Surg Br* 1991;73:932–936.
- 48. Davidson D, Letts M, Glasgow R.** Discoid meniscus in children: treatment and outcome. *Can J Surg* 2003;46:350–358.
- 49. Räber DA, Friederich NF, Hefti F.** Discoid lateral meniscus in children: long-term follow-up after total meniscectomy. *J Bone Joint Surg Am* 1998;80:1579–1586.
- 50. Kim SJ, Chun YM, Jeong JH, Ryu SW, Oh KS, Lubis AM.** Effects of arthroscopic meniscectomy on the long-term prognosis for the discoid lateral meniscus. *Knee Surg Sports Traumatol Arthrosc* 2007;15:1315–1320.
- 51. Rath E, Richmond JC.** The menisci: basic science and advances in treatment. *Br J Sports Med* 2000;34:252–257.
- 52. Brown TD, Davis JT.** Meniscal injury in the skeletally immature patient. In: Micheli LJ, Kocher MS, eds. *The pediatric and adolescent knee*. Philadelphia, PA: Elsevier, 2006;236–259.
- 53. Ahn JH, Kim KI, Wang JH, Jeon JW, Cho YC, Lee SH.** Long-term results of arthroscopic reshaping for symptomatic discoid lateral meniscus in children. *Arthroscopy* 2015;31:867–873.
- 54. Okazaki K, Miura H, Matsuda S, Hashizume M, Iwamoto Y.** Arthroscopic resection of the discoid lateral meniscus: long-term follow-up for 16 years. *Arthroscopy* 2006;22:967–971.
- 55. Carter CW, Hoellwarth J, Weiss JM.** Clinical outcomes as a function of meniscal stability in the discoid meniscus: a preliminary report. *J Pediatr Orthop* 2012;32:9–14.
- 56. Lee YS, Teo SH, Ahn JH, Lee OS, Lee SH, Lee JH.** Systematic review of the long-term surgical outcomes of discoid lateral meniscus. *Arthroscopy* 2017;33:1884–1895.
- 57. Good CR, Green DW, Griffith MH, Valen AW, Widmann RF, Rodeo SA.** Arthroscopic treatment of symptomatic discoid meniscus in children: classification, technique, and results. *Arthroscopy* 2007;23:157–163.
- 58. Steinbacher G, Alentorn-Geli E, Alvarado-Calderón M, Barastegui D, Álvarez-Díaz P, Cugat R.** Meniscal fixation is a successful treatment for hypermobile lateral meniscus in soccer players. *Knee Surg Sports Traumatol Arthrosc* 2019;27:354–360.
- 59. Laible C, Stein DA, Kiridly DN.** Meniscal repair. *J Am Acad Orthop Surg* 2013;21:204–213.
- 60. Gunes T, Bostan B, Erdem M, Asci M, Sen C, Kelestemur MH.** Biomechanical evaluation of arthroscopic all-inside meniscus repairs. *Knee Surg Sports Traumatol Arthrosc* 2009;17:1347–1353.
- 61. Beck JJ, Shifflett K, Greig D, Ebramzadeh E, Bowen RE.** Defining a safe zone for all-inside lateral meniscal repairs in pediatric patients: a magnetic resonance imaging study. *Arthroscopy* 2019;35:166–170.
- 62. Yen YM, Fabricant PD, Richmond CG, et al.** Proximity of the neurovascular structures during all-inside lateral meniscal repair in children: a cadaveric study. *J Exp Orthop* 2018;5:50.
- 63. Tuca M, Luderowski E, Rodeo S.** Meniscal transplant in children. *Curr Opin Pediatr* 2016;28:47–54.
- 64. Verdonk R, Volpi P, Verdonk P, et al.** Indications and limits of meniscal allografts. *Injury* 2013;44:S21–S27.
- 65. Yoon KH, Lee SH, Park SY, Jung GY, Chung KY.** Meniscus allograft transplantation for discoid lateral meniscus: clinical comparison between discoid lateral meniscus and nondiscoid lateral meniscus. *Arthroscopy* 2014;30:724–730.
- 66. Kocher MS, Tepolt FA, Vavken P.** Meniscus transplantation in skeletally immature patients. *J Pediatr Orthop B* 2016;25:343–348.
- 67. Chalmers PN, Karas V, Sherman SL, Cole BJ.** Return to high-level sport after meniscal allograft transplantation. *Arthroscopy* 2013;29:539–544.
- 68. Chang HC, Teh KL, Leong KL, Mak SL, Karim SA.** Clinical evaluation of arthroscopic-assisted allograft meniscal transplantation. *Ann Acad Med Singapore* 2008;37:266–272.
- 69. Lee CR, Bin SI, Kim JM, Kim NK.** Magnetic resonance imaging findings in symptomatic patients after arthroscopic partial meniscectomy for torn discoid lateral meniscus. *Arthroscopy* 2016;32:2366–2372.