








Consensus reclassification of inherited epidermolysis bullosa and other disorders with skin fragility*

C. Has ¹, J.W. Bauer,² C. Bodemer,³ M.C. Bolling,⁴ L. Bruckner-Tuderman,¹ A. Diem,² J.-D. Fine,⁵ A. Heagerty ⁶, A. Hovnanian,⁷ M.P. Marinkovich,⁸ A.E. Martinez,⁹ J.A. McGrath ¹⁰, C. Moss ¹¹, D.F. Murrell ¹², F. Palisson,¹³ A. Schwieger-Briel,¹⁴ E. Sprecher,¹⁵ K. Tamai,¹⁶ J. Uitto ¹⁷, D.T. Woodley,¹⁸ G. Zambruno¹⁹ and J.E. Mellerio ¹⁰

¹Department of Dermatology, Medical Center – University of Freiburg, Faculty of Medicine, University of Freiburg, Germany

²Department of Dermatology and Allergology and EB Haus Austria University Hospital of the Paracelsus Medical University Salzburg, Austria

³Department of Dermatology, Necker Hospital des Enfants Malades, University Paris-Centre APHP 5, Paris, France

⁴University Medical Center Groningen, University of Groningen, Groningen, the Netherlands

⁵Vanderbilt University School of Medicine, Nashville, TN, USA; National Epidermolysis Bullosa Registry, Nashville, TN, USA

⁶Heart of England Foundation Trust, Birmingham, UK

⁷INSERM UMR1163, Imagine Institute, Department of Genetics, Necker hospital for sick children, Paris University, Paris, France

⁸Stanford University School of Medicine, Stanford, Palo Alto Veterans Affairs Medical Center CA, USA

⁹Dermatology Department, Great Ormond Street Hospital for Children, NHS Foundation Trust, London, UK

¹⁰St John's Institute of Dermatology, King's College London and Guy's and St Thomas' NHS Foundation Trust, London, UK

¹¹Birmingham Children's Hospital and University of Birmingham, UK

¹²St George Hospital and University of New South Wales, Sydney, Australia

¹³DEBRA Chile, Facultad de Medicina Clínica Alemana–Universidad del Desarrollo, Santiago, Chile

¹⁴Department of Pediatric Dermatology, University Children's Hospital Zürich, Zürich, Switzerland

¹⁵Division of Dermatology, Tel Aviv Sourasky Medical Center and Sackler Faculty of Medicine, Tel Aviv University, Tel Aviv, Israel

¹⁶Dermatology Department, University of Osaka, Osaka, Japan

¹⁷Thomas Jefferson University, Philadelphia, PA, USA

¹⁸University of Southern California, Los Angeles, CA, USA

¹⁹Dermatology Unit, Bambino Gesù Children's Hospital, Rome, Italy

Linked Comment: Pope. *Br J Dermatol* 2020; **183**:603.

Summary

Correspondence

Cristina Has and Jemima Mellerio.

Emails: cristina.has@uniklinik-freiburg.de;

Jemima.Mellerio@gstt.nhs.uk

Accepted for publication

1 February 2020

Funding sources

The Consensus Conference was funded by Debra UK, Debra Austria and Debra Ireland. (Although the authors have acknowledged in other unrelated publications their extramural support for their own epidermolysis bullosa-related research programmes, none of these has provided funding for the Consensus Conference or the generation of this report.)

Conflicts of interest

None of the authors of this report has any potential conflicts or competing interests.

*Plain language summary available online

Background Several new genes and clinical subtypes have been identified since the publication in 2014 of the report of the last International Consensus Meeting on Epidermolysis Bullosa (EB).

Objectives We sought to reclassify disorders with skin fragility, with a focus on EB, based on new clinical and molecular data.

Methods This was a consensus expert review.

Results In this latest consensus report, we introduce the concept of genetic disorders with skin fragility, of which classical EB represents the prototype. Other disorders with skin fragility, where blisters are a minor part of the clinical picture or are not seen because skin cleavage is very superficial, are classified as separate categories. These include peeling skin disorders, erosive disorders, hyperkeratotic disorders, and connective tissue disorders with skin fragility. Because of the common manifestation of skin fragility, these 'EB-related' disorders should be considered under the EB umbrella in terms of medical and socioeconomic provision of care.

Conclusions The proposed classification scheme should be of value both to clinicians and researchers, emphasizing both clinical and genetic features of EB.

What is already known about this topic?

- Epidermolysis bullosa (EB) is a group of genetic disorders with skin blistering.

- The last updated recommendations on diagnosis and classification were published in 2014.

What does this study add?

- We introduce the concept of genetic disorders with skin fragility, of which classical EB represents the prototype.
- Clinical and genetic aspects, genotype–phenotype correlations, disease-modifying factors and natural history of EB are reviewed.
- Other disorders with skin fragility, e.g. peeling skin disorders, erosive disorders, hyperkeratotic disorders, and connective tissue disorders with skin fragility are classified as separate categories; these ‘EB-related’ disorders should be considered under the EB umbrella in terms of medical and socioeconomic provision of care.

Genetic disorders with skin fragility (SF) are characterized by structural anomalies that reduce the resilience of skin to mechanical stress. Depending on the location of the molecular and structural defect within the skin, clinical manifestations may include peeling, blisters, erosions, ulceration, wounds or scars. In April 2019, a number of leading experts met in London, UK, to review the relevant data and to revise the system of classification of these disorders, considering in particular epidermolysis bullosa (EB), and focusing on the molecular aetiology whenever possible.

EB is the prototypic group of disorders with SF defined by blistering from minimal mechanical trauma with disruption at the dermoepidermal junction (Table 1 and Figure S1; see Supporting information).¹ The four major classical EB types are – EB simplex (EBS), junctional EB (JEB), dystrophic EB (DEB) and Kindler EB (KEB). Other disorders with SF, where blisters are only a minor part of the clinical picture or are not seen because skin cleavage is very superficial, are classified as separate categories. These include peeling skin disorders, erosive disorders, hyperkeratotic disorders,

and connective tissue disorders with SF (Table 2 and Tables S1–S5; see Supporting information). Because of the common manifestation of SF, these ‘EB-related’ disorders should be taken into account in the differential diagnosis.

The proposed system remains largely clinically oriented, because the classification of patients with SF begins at the bedside based on personal and family history, and the presence or absence of specific clinical features. It is only later that laboratory diagnosis enables more accurate subclassification of these patients based on molecular findings (Tables 3–5). The EB classification is complex because mutations in the same gene may be inherited in an autosomal dominant or recessive manner and may result in distinct clinical phenotypes (e.g. KRT5, KRT14, PLEC, COL17A1 or COL7A1). On the other hand, in DEB and EBS, similar phenotypes may be either dominant or recessive, or may be caused by mutations in different genes (e.g. COL7A1, KRT5, KRT14, PLEC, DST, EXPH5 or KLHL24).

If EB is suspected, immunofluorescence mapping and molecular genetic diagnosis should be performed at an early

Table 1 Classification of classical epidermolysis bullosa (EB)

Classical types of EB				
Level of skin cleavage	EB type	Inheritance	Mutated gene(s)	Targeted protein(s)
Intraepidermal	EB simplex	Autosomal dominant	KRT5, KRT14	Keratin 5, keratin 14
			PLEC	Plectin
		Autosomal recessive	KLHL24	Kelch-like member 24
			KRT5, KRT14	Keratin 5, keratin 14
Junctional	Junctional EB	Autosomal recessive	DST	Bullous pemphigoid antigen 230 (BP230) (syn. BPAG1e, dystonin)
			EXPH5 (syn. SLAC2B)	Exophilin-5 (syn. synaptotagmin-like protein homolog lacking C2 domains b, Slac2-b)
			PLEC	Plectin
			CD151 (syn. TSPAN24)	CD151 antigen (syn. tetraspanin 24)
			LAMA3, LAMB3, LAMC2	Laminin 332
			COL17A1	Type XVII collagen
Dermal	Dystrophic EB	Autosomal dominant	ITGA6, ITGB4	Integrin $\alpha 6\beta 4$
			ITGA3	Integrin $\alpha 3$ subunit
			COL7A1	Type VII collagen
Mixed	Kindler EB	Autosomal recessive	COL7A1	Type VII collagen
			FERMT1 (syn. KIND1)	Fermitin family homolog 1 (syn. kindlin-1)

Table 2 Other disorders with skin fragility^a

Level of skin cleavage	Disorder name	Inheritance	Mutated gene(s)	Targeted protein(s)
Peeling skin disorders				
Intraepidermal	Peeling skin disorders	Autosomal recessive	TGM5 CSTA CTSB SERPINB8 FLG2 CDSN CAST DSG1 ^b SPINK5	Transglutaminase 5 Cystatin A Cathepsin B Serpin protease inhibitor 8 Filaggrin 2 Corneodesmosin Calpastatin Desmoglein 1 LEKTI
Erosive disorders				
Intraepidermal	Erosive skin fragility disorders	Autosomal recessive	DSP JUP PKP1 DSC3 DSG3	Desmoplakin Plakoglobin Plakophilin 1 Desmocollin 3 Desmoglein 3
Hyperkeratotic disorders with skin fragility				
Intraepidermal	Keratinopathic ichthyoses	Autosomal dominant Autosomal recessive	KRT1, KRT10, KRT2 KRT10	Keratin 1, 10, 2 Keratin 10
Intraepidermal	Pachyonychia congenita	Autosomal dominant	KRT6A, KRT6B, KRT6C, KRT16, KRT17	Keratin 6A, 6B, 6C, 16, 17
Connective tissue disorder with skin fragility				
Dermal	Syndromic connective tissue disorder with skin fragility	Autosomal recessive	PLOD3	Lysyl hydroxylase 3

^aFor details, see Tables S1–S5 (see Supporting information); ^balso hyperkeratotic features.

stage to determine the precise subtype, improve prognostication, and enable genetic counselling, prenatal diagnosis, inclusion in clinical trials and precision medicine.^{2,3} Guidelines for laboratory diagnosis of EB have been published recently,² and will therefore not be discussed in this article. Unifying clinical and molecular aspects, the previously introduced 'onion skin' approach for subclassification of EB,¹ including the major EB type (based on level of skin cleavage), the inheritance pattern and the clinical and molecular features has proved to be useful, and is further recommended.

The concept of syndromic SF disorders has been proposed recently,⁴ and comprises those entities which are characterized by primary manifestations of other organs or systems such as the gastrointestinal or urogenital tract, myocardium, skeletal muscle, etc. (Table S1; see Supporting information). In contrast to this, severe EB subtypes with long-lasting skin and mucosal defects over large surface areas, in particular severe recessive DEB (RDEB), evolve with secondary extracutaneous complications.^{5,6}

Classical types of epidermolysis bullosa

The main clinical and genetic features of classical types of EB are described in Appendix S1 (see Supporting information). Clinical aspects are illustrated in Figures 1–5 and Figures S2–S4 (see Supporting information).

Epidermolysis bullosa simplex

EBS is defined by skin blistering due to cleavage within the basal layer of keratinocytes. In most cases, EBS is inherited in an autosomal dominant manner; autosomal recessive inheritance is rare in Western countries but quite common in some regions in the world.^{7,8} There is a broad spectrum of clinical severity ranging from minor blistering on the feet, to subtypes with extracutaneous involvement and a lethal outcome. The genetic background is complex with mutations in seven distinct genes. New genes, KLHL24^{9,10} and CD151,¹¹ have been identified since the previous classification and extend the spectrum of EBS; still, a certain percentage of cases remain genetically unsolved. EBS is the most common EB type, with the majority of mild cases remaining underdiagnosed. Figures from the USA suggested a total incidence of 7.87 per million live births, and a prevalence of six per million.¹²

The common EBS subtypes are caused by monoallelic mutations within the genes encoding keratin 5 or 14, and comprise: localized (previously known as Weber–Cockayne), intermediate (previously known as generalized intermediate or Köbner) and severe (previously known as generalized severe or Dowling–Meara) EBS. Rare EBS subtypes are clinically heterogeneous and include several syndromic disorders (Table 3). Genetically, conditions are either autosomal dominant or recessive, some of them being caused by specific

Table 3 Epidermolysis bullosa simplex (EBS) clinical subtypes

Most common EBS clinical subtypes	Targeted protein(s)
Autosomal dominant EBS	
Localized	Keratin 5, keratin 14
Intermediate	Keratin 5, keratin 14
Severe	Keratin 5, keratin 14
With mottled pigmentation	Keratin 5 ^a
Migratory circinate erythema	Keratin 5
Intermediate	Plectin
Intermediate with cardiomyopathy	Kelch-like member 24
Autosomal recessive EBS	
Intermediate or severe	Keratin 14, keratin 5
Intermediate	Plectin
Localized or intermediate with BP230 deficiency	Bullous pemphigoid antigen 230 (BP230) (syn. BPAG1e)
Localized or intermediate with exophilin-5 deficiency	Exophilin-5 (syn. Slac2-b)
Intermediate with muscular dystrophy	Plectin
Severe with pyloric atresia	Plectin
Localized with nephropathy	CD151 (CD151 antigen) (syn. tetraspanin 24)

^aTypical recurrent mutation in keratin 5, but cases with other keratin 5, keratin 14 or exophilin-5 mutations have been reported; **bold**, syndromic EBS subtypes.

Table 4 Junctional epidermolysis bullosa (JEB) clinical subtypes

Most common JEB clinical subtypes	Targeted protein(s)
Severe	Laminin 332 ^a
Intermediate	Laminin 332
Intermediate	Type XVII collagen
With pyloric atresia	Integrin $\alpha 6\beta 4$
Localized	Laminin 332, type XVII collagen, integrin $\alpha 6\beta 4$, integrin $\alpha 3$ subunit
Inversa	Laminin 332
Late onset	Type XVII collagen
LOC syndrome	Laminin $\alpha 3A$
With interstitial lung disease and nephrotic syndrome	Integrin $\alpha 3$ subunit

LOC, laryngo–onycho–cutaneous. ^aJEB severe is rarely caused by pathogenic variants affecting the type XVII collagen gene; **bold**, syndromic JEB subtypes.

mutations with distinct molecular and phenotypic consequences that are not fully understood. A few cases of EBS caused by mutations in *ITGB4* or *COL17A1* (genes usually associated with JEB) that disrupt the cytoplasmic domains of the respective proteins have been reported.^{13,14}

Table 5 Dystrophic epidermolysis bullosa (DEB) clinical subtypes

DEB subtypes	Targeted protein
Autosomal dominant DEB (DDEB)	
Intermediate	Type VII collagen
Localized	
Pruriginosa	
Self-improving	
Autosomal recessive DEB (RDEB)	
Severe	Type VII collagen
Intermediate	
Inversa	
Localized	
Pruriginosa	
Self-improving	
Dominant and recessive (compound heterozygosity)	
DEB, severe	Type VII collagen

bold, most common subtypes.

Junctional epidermolysis bullosa

JEB is an autosomal recessive disorder characterized by skin blistering with a plane of cleavage through the lamina lucida of the cutaneous basement membrane zone (BMZ). The severity varies considerably across the two major subtypes, intermediate and severe, with the latter associated with early lethality in the first 6–24 months of life. Epidemiological data indicate that JEB is less common than simplex or dystrophic types of EB. Figures from the USA suggested a total incidence of just over two per million live births; however, prevalence rates lower than this likely reflect the short life expectancy of the severe form.^{12,15}

The two major subtypes of JEB are severe JEB (previously known as JEB generalized severe, Herlitz JEB) and intermediate JEB (previously known as JEB generalized intermediate, non-Herlitz JEB). While biallelic mutations in one of the three genes encoding the subunit chains of laminin 332 (*LAMA3*, *LAMB3*, *LAMC2*) give rise to either of these forms, biallelic mutations of the type XVII collagen gene (*COL17A1*) can also result in intermediate and rarely in severe JEB phenotypes.¹⁶ Rare JEB subtypes are clinically and genetically heterogeneous and include several syndromic disorders (Table 4).

Dystrophic epidermolysis bullosa

DEB is characterized by a plane of skin cleavage just beneath the lamina densa in the most superficial portion of the dermis. Ultrastructurally, this corresponds to the level of the anchoring fibrils, reflecting the underlying molecular pathology in the gene coding for the main component of these structures, type VII collagen. DEB may be inherited as a dominant or recessive trait; generally, RDEB is more severe than dominant disease (DDEB); however, there is considerable phenotypic overlap between types. The hallmark of DEB is that of scarring following blistering, both in the skin and in a variety of mucosae. Milia are also a specific finding in areas of healed blistering in DEB. Secondary extracutaneous

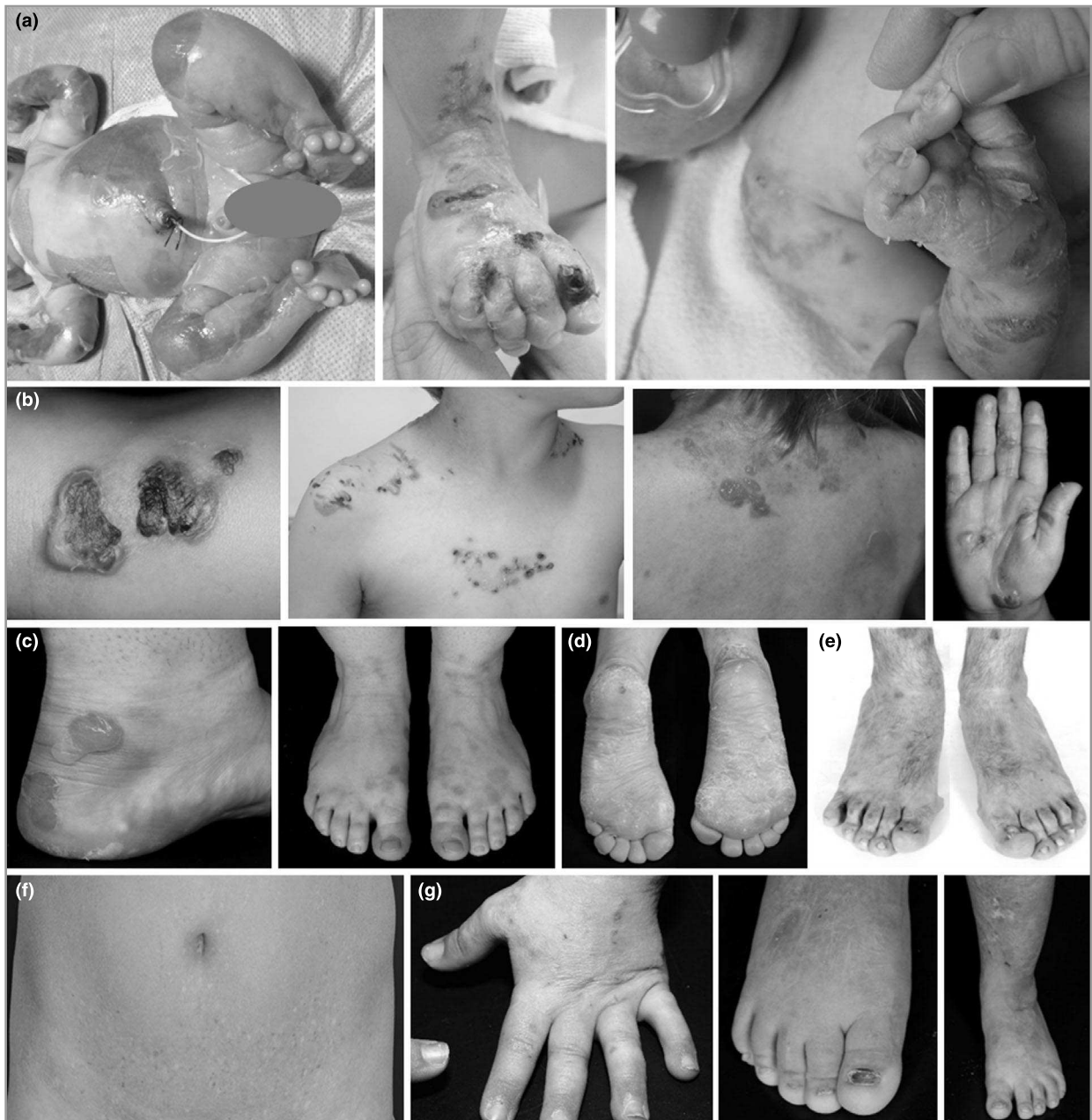

Figure 1 Epidermolysis bullosa simplex (EBS). (a) Neonatal severe EBS with widespread skin blistering, ulceration and crusting. Nails may be thickened. (b) Beyond the first months or year of life, arcuate or herpetiform blistering and crusting on an inflammatory base is typical of severe EBS. (c) Tense blisters and healing erosions affecting sites of friction on the feet in localized EBS. (d) Plantar keratoderma, here in severe EBS, is found in all three common EBS subtypes. (e) Nails may be thick and dystrophic, particularly in severe EBS. (f) Mottled hypo- and hyperpigmentation on the lower abdomen in EBS with mottled pigmentation. (g) Superficial crusts, erosions and scarring in KLHL24 EBS.

complications are common in the more severe forms of RDEB. Estimates of the incidence and prevalence of DEB vary, reflecting differences in recruitment to patient cohorts in different countries. The incidence of DDEB in Norway and the USA has been reported as 1.4 and 2.5 per million live births,¹⁷ respectively, and that of RDEB in the USA at 3.05 per million.¹⁵ Figures for prevalence of all types of DEB have been estimated at approximately six per million in the USA¹⁵ and Spain,¹⁸ eight per million in Australia¹⁹ and 20 per

million in Scotland,²⁰ the latter probably reflecting greater capture rather than a true higher prevalence.

All subtypes of DEB, both dominant and recessive, are caused by mutations in the gene coding collagen VII, COL7A1, the major component of the anchoring fibrils at the cutaneous BMZ. Major subtypes of DEB include localized DDEB (previously encompassing nails only, pretibial and acral DDEB), intermediate DDEB (previously known as generalized DDEB), intermediate RDEB (previously known as RDEB generalized

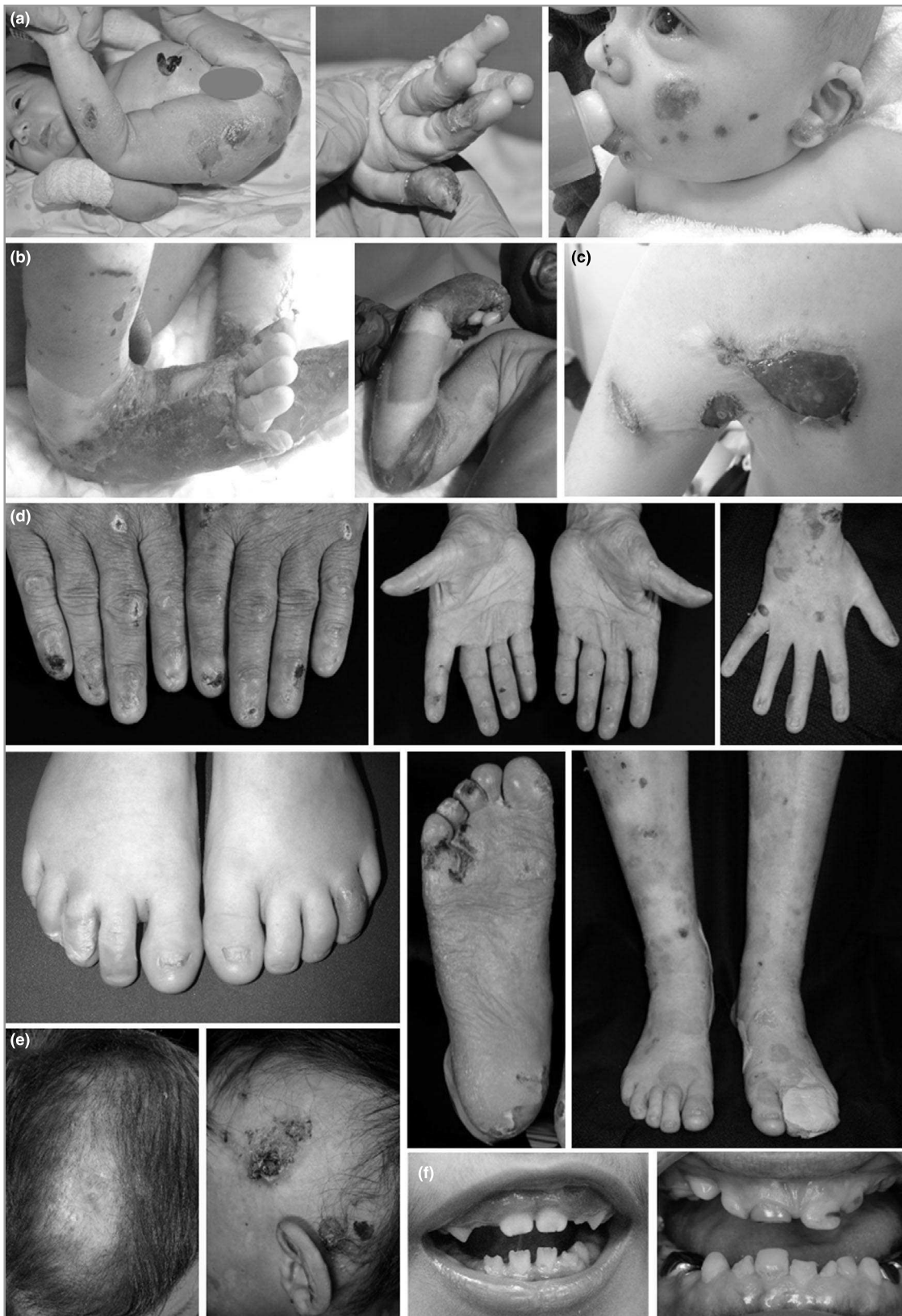

Figure 2 (a) Severe junctional epidermolysis bullosa (JEB). Neonatal skin blistering and crusting. Granulation tissue of the distal digits, face and ears are typical. In intermediate JEB, blistering may be widespread in infants (b) and lead to chronic overgranulated wounds in babies and older individuals (c). (d) Nail loss and dystrophy with skin blistering, crusting and scarring in intermediate JEB. (e) Scarring and nonscarring alopecia with patchily sparse hair in intermediate JEB. (f) Dental enamel defects with discoloured, pitted teeth in intermediate JEB.

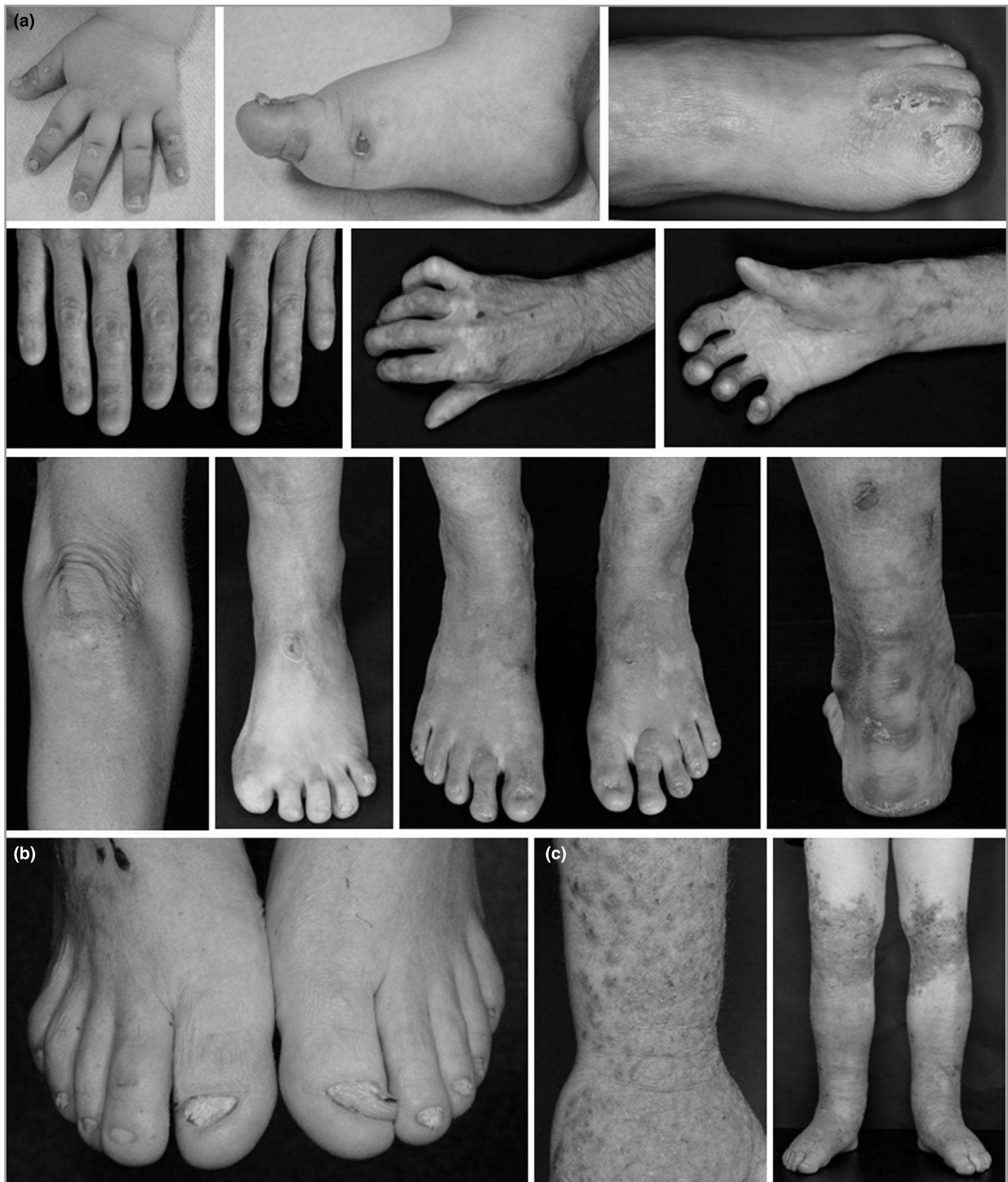

Figure 3 (a) Localized, dominant dystrophic epidermolysis bullosa (DDEB) and intermediate recessive DEB (RDEB) often display phenotypic overlap. Skin blistering may be limited in extent and mainly acral and over bony prominences such as elbows and knees. Blisters heal with scarring and may be associated with milia. Nail dystrophy or loss is common. Striate hyperkeratosis of the palms and fingers may cause flexion contractures. (b) Nail dystrophy in DDEB. (c) Lichenoid, excoriating papules of the distal limbs in EB pruriginosa.

intermediate, non-Hallopeau–Siemens RDEB) and severe RDEB (previously RDEB generalized severe, Hallopeau–Siemens RDEB). A number of rarer forms of DEB are recognized (Table 5).

Kindler epidermolysis bullosa

KEB is a rare type of EB with about 250 affected individuals reported worldwide since the first description in 1954.²¹ It is

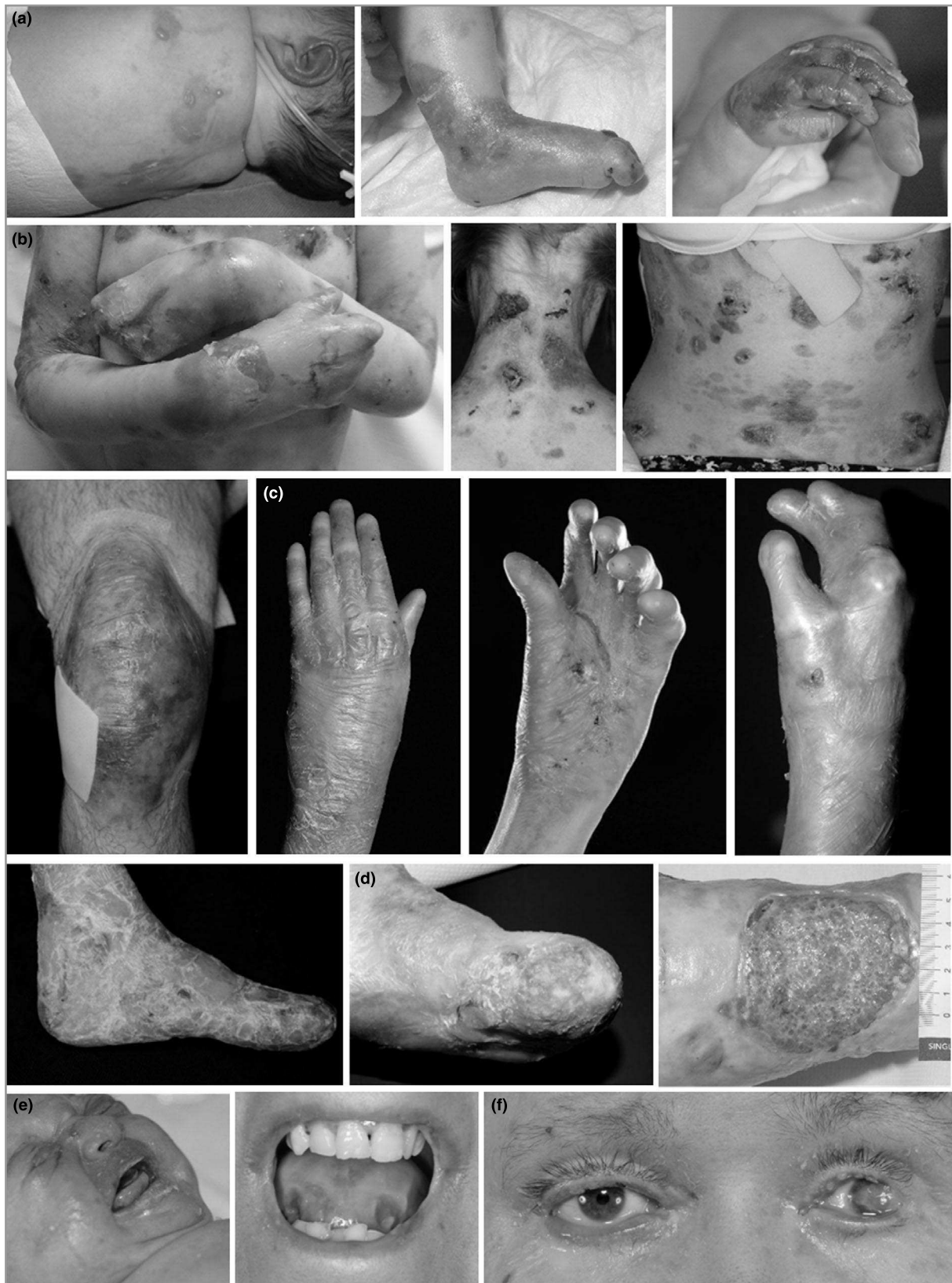

Figure 4 Severe recessive dystrophic epidermolysis bullosa (RDEB). (a) Widespread skin fragility and ulceration in neonates. (b) Extensive blistering and wounds lead to scarring and joint contractures. (c) Loss of the distal digits, digital fusion and flexion contractures increase with age. (d) Squamous cell carcinoma is common, especially on acral sites and the lower limbs. (e) Oral blistering and ulceration with a smooth, depapillated tongue. Progressive oral mucosal scarring leads to microstomia, loss of sulci and dental overcrowding. (f) Ectropion and pannus formation.

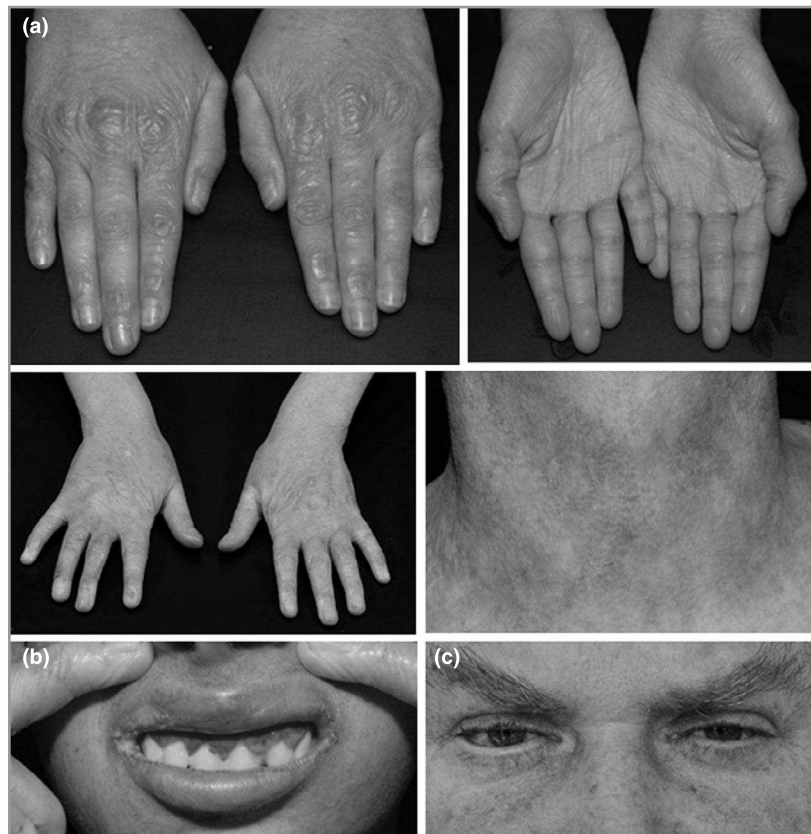


Figure 5 Kindler epidermolysis bullosa. (a) Skin atrophy and poikiloderma on the hands and neck. (b) Gingivitis with gingival hyperplasia. (c) Ectropion is common and may lead to corneal erosions.

more common in isolated or consanguineous populations.^{22,23} To avoid confusion regarding the syndromic nature of this disorder, the designation Kindler EB is proposed instead of Kindler syndrome. The genetic basis is represented by mutations in *FERMT1* (syn. *KIND1*), encoding fermitin family homolog 1 (kindlin-1), an intracellular protein of focal adhesions.

Other disorders with skin fragility

Besides the classical EB subtypes, SF is a feature of other groups of inherited diseases, including peeling skin, erosive, hyperkeratotic and connective tissue disorders (Table 2). These entities resemble EB with respect to the presence of skin and/or skin barrier defects and pathogenetic mechanisms,²⁴ and should be considered in the differential diagnosis, in particular in the newborn. Therefore, we recommend including the corresponding genes in next-generation sequencing targeted panels for EB. The main clinical and molecular characteristics of the disorders included in these groups are summarized in Tables S3–S5 (see Supporting information). For a detailed description we refer to the original and review articles.^{25–31}

Several disorders with SF deserve more detailed specification. The acral peeling skin disease has been reported to

resemble localized EBS in infants, while in adults, characteristic peeling on the extremities allows clinical diagnosis.^{32,33} Erosive disorders with acantholysis due to desmosomal defects may manifest with superficial blisters, but mostly with erosions. Individuals with keratinopathic ichthyoses exhibit skin blistering at birth and in infancy, but hyperkeratosis develops soon and dominates the clinical picture.

A disorder with acantholytic blisters of the oral mucosa has been described in a single individual so far, resulting from a homozygous nonsense mutation in the desmoglein 3 gene.³⁴

Although not included as ‘classical’ EB, this group of disorders is notable in that skin and often mucosal fragility are key phenotypic features, bringing with them the same clinical burden and healthcare needs. As such they should be considered under the EB umbrella in terms of medical and socioeconomic provision of care.

Genotype–phenotype correlations in epidermolysis bullosa

The number of pathogenic variants associated with classical EB and other disorders with SF is steadily growing, reaching several thousands (Human Gene Mutation Database, professional). Although many individual variants and genotype–phenotype relationships exist, some general rules apply and

are outlined below. Their importance relies on their medical relevance, in the context of prognostication of disease severity in neonates, and in prioritization of genetic testing to save resources. It is important to remain aware of the limitations of these correlations when counselling patients and their families as many exceptions to these rules have been reported.

Genotype–phenotype correlations in epidermolysis bullosa simplex with *KRT5* and *KRT14* mutations

For autosomal dominant EBS with *KRT5* or *KRT14* pathogenic variants, the position of the affected amino acid within the keratin polypeptide determines the severity of the phenotype and allows prognostication. Substitutions of highly conserved amino acids within the helix initiation or termination motifs impair heterodimerization of keratin 5 and 14 polypeptides and lead to severe EBS, whereas substitutions in other regions of the gene lead to localized EBS (www.interfil.org).³⁵ Monoallelic in-frame deletions, splice-site or premature termination codon (PTC) variants usually lead to formation of truncated proteins with dominant negative effects.^{36,37} Some pathogenic variants in keratin 5 or 14 have been correlated with a very severe clinical course.^{38,39} Most cases with autosomal recessive EBS are caused by *KRT14* nonsense or frameshift pathogenic variants. Absence of keratin 5 has been reported in two cases, both with early lethality.^{40,41}

Genotype–phenotype correlations in junctional epidermolysis bullosa

Pathogenic variants leading to absence of laminin 332 or integrin $\alpha 6\beta 4$ are associated with early lethality,^{42,43} whereas most *COL17A1* pathogenic variants result in absence of collagen XVII but are associated with less severe phenotypes.⁴⁴ Missense or splicing mutations allowing expression of a residual protein lead to milder phenotypes. Observations in patients with JEB clearly show that as little as 5–10% of residual protein, even if truncated and putatively partially functional, significantly alleviates the phenotype (reviewed in Condrat *et al.*⁴⁴ and Has *et al.*⁴⁵). Of particular interest are a few pathogenic variants associated with self-improving JEB with milder than expected phenotypes. The underlying molecular mechanisms are alternative modulation of splicing, spontaneous read-through of PTCs or skipping of exons containing PTCs.^{46–48}

Genotype–phenotype correlations in dystrophic epidermolysis bullosa

DDEB is mainly due to glycine substitutions in the collagenous domains around the hinge region of type VII collagen corresponding to exon 73 of *COL7A1*,⁴⁹ the most common being p.G2043R. However, there is considerable clinical variability between individuals bearing the same glycine substitution, even within the same family.⁵⁰ In addition, some glycine substitution mutations in the collagenous triple helix are associated with RDEB and others may result in either dominant or

recessive DEB.⁵¹ Monoallelic splice-site or indel mutations leading to in-frame skipping of entire exons (e.g. exon 87),⁵² or even large deletions within the triple-helical domain,⁵³ lead to mild localized DDEB. RDEB is caused by a broad spectrum of pathogenic variants resulting in absence of type VII collagen. Compound heterozygosity for dominant and recessive *COL7A1* mutations has been repeatedly reported to be associated with severe DEB.⁵⁴ Self-improving DEB was associated with in-frame skipping of exons (e.g. exon 36)⁵⁵ or with specific glycine substitutions.^{56,57} Specific glycine and arginine substitution mutations in *COL7A1* have been implicated in RDEB *inversa*, with the suggestion that they may affect the thermostability of type VII collagen.⁵⁸

Disease-modifying factors

In some cases, deviations from expected genotype–phenotype correlations can be explained by involvement of modifying factors, either genetic or epigenetic.

One type of genetic modifier is represented by variants in cis that may change the expression of the corresponding allele, resulting, for example, in in-frame skipping of the exon containing the disease-causing variant.⁵⁹ Such an event can alleviate the disease severity because truncated molecules often retain partial function. A second type of genetic modifier is mosaicism, either as postzygotic mosaicism for a disease-causing variant (described for *COL7A1* and *PKP1*)^{60–62} or as revertant mosaicism (described for *KRT14*,^{63,64} *COL17A1*,^{65–67} *LAMB3*,⁶⁸ *COL7A1*^{69–71} and *FERMT1*^{72,73}). Postzygotic mosaicism for dominant mutations may explain an apparently mild phenotype in a parent and more severe disease in the offspring, while Blaschko linear areas of affected skin may result from mosaicism for a second recessive mutation. Revertant mosaicism has been reported in all types of EB and accounts for skin areas with improved mechanical stability due to spontaneous repair of the disease-causing variant.⁷⁴ Thirdly, digenic mutations in two EB-associated genes, e.g. both *KRT5* and *KRT14*,⁷⁵ *EXPH5* and *COL17A1*⁷⁶ or *PLEC1* and *ITGB4*⁷⁷ variants have been reported to lead to unexpected phenotypes. A fourth type of genetic modifier mechanism is represented by variants in genes that are not directly associated with EB, but their products may modulate or influence EB-associated proteins. Such an example is *MMP1*, encoding matrix metalloproteinase 1, an enzyme that degrades type VII collagen. A frequent functional genetic variant in the *MMP1* promoter was reported to be associated with higher disease severity in RDEB due to an imbalance between type VII collagen synthesis and degradation.⁷⁸ Finally, on a consanguineous background, co-occurrence of EB and other genetic disorders leads to complex, apparently ‘new’ phenotypes.⁷⁹

Epigenetic factors modulating gene expression include heterochromatin components, polycomb proteins, noncoding RNA and DNA methylation;⁸⁰ such mechanisms remain to be demonstrated in EB. Changes in gene expression of decorin and transforming growth factor- β have been reported in RDEB.^{81,82} They are either secondary effects that arise in the

context of chronic wound healing processes and further deteriorate the local cutaneous environment, or are caused by discrete genetic variants. Nevertheless, they represent potential targets for therapy. Other epigenetic yet unknown factors remain to be identified.

Finally, individual (e.g. personality, family context), socio-economic (e.g. access to medical care and hygienic conditions) and environmental factors (e.g. climate) have a significant modulating influence on the course of EB. Taken together, genetic, epigenetic and nongenetic modifying factors appear to have a strong influence on EB phenotype; this variability means that phenotypes often reflect a continuum and, as such, strict categorization into subtypes is not always straightforward.

Natural history

The clinical features and complications of different forms of EB often change and evolve over time and an understanding of this is imperative to recognize different subtypes and anticipate the clinical course and related problems. While this natural history partly reflects changes related to different developmental stages throughout life, certain subtypes of EB have a natural evolution with variation in severity, either worsening or ameliorating, or the development or loss of specific features over time.

Distinguishing the major types of EB in the neonatal period on the basis of clinical features is extremely unreliable and highlights the need for rapid and accurate laboratory diagnosis.² Blistering in babies often has a predilection for the extremities and around the diaper area, but as the child develops, the pattern of blistering will usually become more characteristic of its subtype. For example, in EBS localized, blisters will form predominantly on the feet, whereas in intermediate or severe DEB subtypes, fragility will become more marked over bony prominences such as the knees and elbows. While babies with severe JEB may have relatively little skin blistering at birth, over the first few months the characteristic granulation tissue affecting the face, ears and distal digits becomes more prominent and distinctive. In KEB, early childhood blistering resolves as photosensitivity and progressive poikiloderma become more evident. Some sequelae of EB are irreversible and progressive, for example skin and oral mucosal scarring or nail loss in DEB; therefore, they tend to become more marked with age.

In severe EBS, infants have very severe and extensive skin blistering and this subtype can have a lethal course. However, the natural history is one of progressive improvement over time, such that adults may have very limited blistering confined largely to acral sites. The clinical features of EBS with mottled pigmentation also vary with time, often with blistering improving throughout childhood, paralleled by the development of the characteristic pigmentary changes unrelated to previous sites of blistering and punctate palmoplantar keratoses. Intermediate EBS with *KLHL24* mutations is notable for its severe skin loss at birth which ameliorates with age, and

also by the development of cardiomyopathy in early adulthood. Similarly, in EBS with *PLEC* mutations, SF is accompanied by the onset of progressive muscular dystrophy at any point between infancy and adulthood, and has also been associated with cardiomyopathy.

The extent and pattern of blistering may vary in distinct forms of EB. For example, RDEB *inversa* usually comprises intermediate severity of generalized blistering early in life, but later in childhood to adulthood, the sites of predilection become markedly flexural. Pruriginosa DEB also evolves over time, with the development of prurigo-like nodules and linear lesions on the lower legs initially, spreading generally more proximally and also onto the arms with time. The onset of specific pruriginosa features may be extremely delayed, with onset in late adulthood.⁸³ Similarly, the distribution of localized pretibial DEB evolves with age. In late-onset JEB, SF tends to start in mid-childhood with progressive scleroderma-like atrophy and nail changes developing subsequently. A number of cases of severe JEB in infancy have been associated with spontaneous amelioration and longer-term survival; in such cases, *LAMB3* mutations resulting in a truncated but partially functional $\beta 3$ laminin chain have been postulated to result in an intermediate clinical picture.^{47,84,85} The mechanisms behind the distinct patterns of distribution and their fluctuation over time in different subtypes of EB are not fully understood, but likely reflect specific genetic consequences at a protein level. Further elucidation of genotype–phenotype correlation in EB-causing genes as well as other genetic modifiers, may provide some clarification in time.

In addition to disease-specific natural history, EB may be accompanied by many secondary complications that develop over time and often depend on the general severity of the EB type, as well as environmental and confounding factors such as bacterial colonization. For example, anaemia, reduced bone mineral density, renal impairment, progressive skin contractures and the development of squamous cell carcinoma are all potential complications of severe RDEB but there is inter-individual variability around whether or when they may occur.⁸⁶

Relevance and perspectives

Revisions of the EB classification go along with developments in diagnostics and research, and should be a useful tool for clinicians dealing with people with EB (for counselling, prognostication, follow-up and screening for complications) and for researchers. Emerging therapeutic options and clinical trials open new perspectives and underscore the importance of molecular genetics and genotype–phenotype correlations to predict therapeutic options for precision medicine. EB-associated proteins have distinct roles in assuring the mechanical stability of the cells and adhesion, as well as structural and functional particularities (e.g. laminin 332, integrin $\alpha 6\beta 4$ ⁸⁷ or collagen XVII⁸⁸ in controlling keratinocyte stemness). Yet, there are common pathogenetic mechanisms, such as chronic tissue damage and inflammation that apply to all/several types of EB.⁸⁹ Some therapeutic principles, like induction of read-

through of PTC mutations,^{90–92} RNA-based therapies (e.g. antisense oligonucleotides for exon skipping⁹³) or modulation of protein misfolding,⁹⁴ may be applied for different genes/proteins, under the premise of knowledge of individual mutations and their consequences. Therefore, subclassification of EB and SF disorders on the basis of the molecular defect, and stratification of mutations for precision medicine⁴⁴ is a tempting challenge for the future.

Acknowledgments

Sarah Büchel is acknowledged for preparing Figure S1 (see Supporting information). MPM received salary support from the Office of Research and Development, Palo Alto VA Medical Center.

References

- 1 Fine J-D, Bruckner-Tuderman L, Eady RAJ *et al.* Inherited epidermolysis bullosa: updated recommendations on diagnosis and classification. *J Am Acad Dermatol* 2014; **70**:1103–26.
- 2 Has C, Liu L, Bolling M *et al.* Clinical practice guidelines for laboratory diagnosis of epidermolysis bullosa. *Br J Dermatol* 2020; **182**:574–92.
- 3 Uitto J, Atanasova VS, Jiang Q, South AP. Precision medicine for heritable skin diseases – the paradigm of epidermolysis bullosa. *J Invest Dermatol Symp Proc* 2018; **19**:S74–6.
- 4 Vahidnezhad H, Youssefian L, Saeidian AH, Uitto J. Phenotypic spectrum of epidermolysis bullosa: the paradigm of syndromic versus non-syndromic skin fragility disorders. *J Invest Dermatol* 2019; **139**:522–7.
- 5 Fine JD, Mellerio JE. Extracutaneous manifestations and complications of inherited epidermolysis bullosa: part I. Epithelial associated tissues. *J Am Acad Dermatol* 2009; **61**:367–84; quiz 385–6.
- 6 Fine JD, Mellerio JE. Extracutaneous manifestations and complications of inherited epidermolysis bullosa: part II. Other organs. *J Am Acad Dermatol* 2009; **61**:387–402; quiz 403–4.
- 7 Ciubotaru D, Bergman R, Baty D *et al.* Epidermolysis bullosa simplex in Israel: clinical and genetic features. *Arch Dermatol* 2003; **139**:498–505.
- 8 Takeichi T, Nanda A, Liu L *et al.* Founder mutation in dystonin-e underlying autosomal recessive epidermolysis bullosa simplex in Kuwait. *Br J Dermatol* 2015; **172**:527–31.
- 9 Lin Z, Li S, Feng C *et al.* Stabilizing mutations of KLHL24 ubiquitin ligase cause loss of keratin 14 and human skin fragility. *Nat Genet* 2016; **48**:1508–16.
- 10 He Y, Maier K, Leppert J *et al.* Monoallelic mutations in the translation initiation codon of KLHL24 cause skin fragility. *Am J Hum Genet* 2016; **99**:1395–404.
- 11 Vahidnezhad H, Youssefian L, Saeidian AH *et al.* Recessive mutation in tetraspanin CD151 causes Kindler syndrome-like epidermolysis bullosa with multi-systemic manifestations including nephropathy. *Matrix Biol J Int Soc Matrix Biol* 2018; **66**:22–33.
- 12 Pfendner E, Uitto J, Fine JD. Epidermolysis bullosa carrier frequencies in the US population. *J Invest Dermatol* 2001; **116**:483–4.
- 13 Jonkman MF, Pas HH, Nijenhuis M *et al.* Deletion of a cytoplasmic domain of integrin beta4 causes epidermolysis bullosa simplex. *J Invest Dermatol* 2002; **119**:1275–81.
- 14 Fontao L, Tasanen K, Huber M *et al.* Molecular consequences of deletion of the cytoplasmic domain of bullous pemphigoid 180 in a patient with predominant features of epidermolysis bullosa simplex. *J Invest Dermatol* 2004; **122**:65–72.
- 15 Fine J-D. Epidemiology of inherited epidermolysis bullosa based on incidence and prevalence estimates from the National Epidermolysis Bullosa Registry. *JAMA Dermatol* 2016; **152**:1231–8.
- 16 Abu Sa'd J, Indelman M, Pfendner E *et al.* Molecular epidemiology of hereditary epidermolysis bullosa in a Middle Eastern population. *J Invest Dermatol* 2006; **126**:777–81.
- 17 Fine JD, Bauer EA, McGuire J, Moshell A (eds). *Epidermolysis Bullosa: Clinical, Epidemiologic, and Laboratory Advances, and the Findings of the National Epidermolysis Bullosa Registry*. Baltimore: Johns Hopkins University Press, 1999.
- 18 Hernandez-Martín A, Aranegui B, Escámez MJ *et al.* Prevalence of dystrophic epidermolysis bullosa in Spain: a population-based study using the 3-source capture–recapture method. Evidence of a need for improvement in care. *Actas Dermosifiliogr* 2013; **104**:890–6.
- 19 Kho YC, Rhodes LM, Robertson SJ *et al.* Epidemiology of epidermolysis bullosa in the antipodes: the Australasian Epidermolysis Bullosa Registry with a focus on Herlitz junctional epidermolysis bullosa. *Arch Dermatol* 2010; **146**:635–40.
- 20 Horn HM, Priestley GC, Eady RA, Tidman MJ. The prevalence of epidermolysis bullosa in Scotland. *Br J Dermatol* 1997; **136**:560–4.
- 21 Kindler T. Congenital poikiloderma with traumatic bulla formation and progressive cutaneous atrophy. *Br J Dermatol* 1954; **66**:104–11.
- 22 Penagos H, Jaen M, Sancho MT *et al.* Kindler syndrome in Native Americans from Panama: report of 26 cases. *Arch Dermatol* 2004; **140**:939–44.
- 23 Youssefian L, Vahidnezhad H, Barzegar M *et al.* The Kindler syndrome: a spectrum of FERMT1 mutations in Iranian families. *J Invest Dermatol* 2015; **135**:1447–50.
- 24 Hamada T, Tsuruta D, Fukuda S *et al.* How do keratinizing disorders and blistering disorders overlap? *Exp Dermatol* 2013; **22**:83–7.
- 25 Samuelov L, Sarig O, Harmon RM *et al.* Desmoglein 1 deficiency results in severe dermatitis, multiple allergies and metabolic wasting. *Nat Genet* 2013; **45**:1244–8.
- 26 Samuelov L, Sprecher E. Inherited desmosomal disorders. *Cell Tissue Res* 2015; **360**:457–75.
- 27 Samuelov L, Sprecher E. Peeling off the genetics of atopic dermatitis-like congenital disorders. *J Allergy Clin Immunol* 2014; **134**:808–15.
- 28 Vahlquist A, Fischer J, Törmä H. Inherited nonsyndromic ichthyoses: an update on pathophysiology, diagnosis and treatment. *Am J Clin Dermatol* 2018; **19**:51–66.
- 29 Knöbel M, O'Toole EA, Smith FJD. Keratins and skin disease. *Cell Tissue Res* 2015; **360**:583–9.
- 30 Has C. Peeling skin disorders: a paradigm for skin desquamation. *J Invest Dermatol* 2018; **138**:1689–91.
- 31 Onoufriadis A, Ahmed N, Bessar H *et al.* Homozygous nonsense mutation in DSC3 resulting in skin fragility and hypotrichosis. *J Invest Dermatol* 2020; <https://doi.org/10.1016/j.jid.2019.10.015>.
- 32 Kiritsi D, Cosgarea I, Franzke CW *et al.* Acral peeling skin syndrome with TGM5 gene mutations may resemble epidermolysis bullosa simplex in young individuals. *J Invest Dermatol* 2010; **130**:1741–6.
- 33 Szczecinska W, Nesteruk D, Wertheim-Tysarowska K *et al.* Underrecognition of acral peeling skin syndrome: 59 new cases with 15 novel mutations. *Br J Dermatol* 2014; **171**:1206–10.
- 34 Kim JH, Kim S-E, Park HS *et al.* A homozygous nonsense mutation in the DSG3 gene causes acantholytic blisters in the oral and laryngeal mucosa. *J Invest Dermatol* 2019; **139**:1187–90.
- 35 Coulombe PA, Lee C-H. Defining keratin protein function in skin epithelia: epidermolysis bullosa simplex and its aftermath. *J Invest Dermatol* 2012; **132**:763–75.

- 36 Müller FB, Küster W, Wodecki K *et al.* Novel and recurrent mutations in keratin KRT5 and KRT14 genes in epidermolysis bullosa simplex: implications for disease phenotype and keratin filament assembly. *Hum Mutat* 2006; **27**:719–20.
- 37 Has C, Schumann H, Leppert J *et al.* Monoallelic large intragenic KRT5 deletions account for genetically unsolved cases of epidermolysis bullosa simplex. *J Invest Dermatol* 2017; **137**:2231–4.
- 38 Sathishkumar D, Orrin E, Terron-Kwiatkowski A *et al.* The p.Glu477Lys mutation in Keratin 5 is strongly associated with mortality in generalized severe epidermolysis bullosa simplex. *J Invest Dermatol* 2016; **136**:719–21.
- 39 Titeux M, Mazereeuw-Hautier J, Hadj-Rabia S *et al.* Three severe cases of EBS Dowling-Meara caused by missense and frameshift mutations in the keratin 14 gene. *J Invest Dermatol* 2006; **126**:773–6.
- 40 Vahidnezhad H, Youssefian L, Daneshpazhooh M *et al.* Biallelic KRT5 mutations in autosomal recessive epidermolysis bullosa simplex, including a complete human keratin 5 'knock-out'. *Matrix Biol J Int Soc Matrix Biol* 2019; **83**:48–59.
- 41 Tryon RK, Tolar J, Preusser SM *et al.* A homozygous frameshift variant in the KRT5 gene is compatible with life and results in severe recessive epidermolysis bullosa simplex. *JAAD Case Rep* 2019; **5**:576–9.
- 42 Hammersen J, Has C, Naumann-Bartsch N *et al.* Genotype, clinical course, and therapeutic decision making in 76 infants with severe generalized junctional epidermolysis bullosa. *J Invest Dermatol* 2016; **136**:2150–7.
- 43 Schumann H, Kiritsi D, Pigors M *et al.* Phenotypic spectrum of epidermolysis bullosa associated with $\alpha 6\beta 4$ integrin mutations. *Br J Dermatol* 2013; **169**:115–24.
- 44 Condrat I, He Y, Cosgarea R, Has C. Junctional epidermolysis bullosa: allelic heterogeneity and mutation stratification for precision medicine. *Front Med* 2018; **5**:363.
- 45 Has C, Nyström A, Saedian AH *et al.* Epidermolysis bullosa: molecular pathology of connective tissue components in the cutaneous basement membrane zone. *Matrix Biol J Int Soc Matrix Biol* 2018; **71–72**:313–29.
- 46 Chavanas S, Gache Y, Vailly J *et al.* Splicing modulation of integrin beta4 pre-mRNA carrying a branch point mutation underlies epidermolysis bullosa with pyloric atresia undergoing spontaneous amelioration with ageing. *Hum Mol Genet* 1999; **8**:2097–105.
- 47 McGrath JA, Ashton GH, Mellerio JE *et al.* Moderation of phenotypic severity in dystrophic and junctional forms of epidermolysis bullosa through in-frame skipping of exons containing non-sense or frameshift mutations. *J Invest Dermatol* 1999; **113**:314–21.
- 48 Pachó F, Zambruno G, Calabresi V *et al.* Efficiency of translation termination in humans is highly dependent upon nucleotides in the neighbourhood of a (premature) termination codon. *J Med Genet* 2011; **48**:640–4.
- 49 Mecklenbeck S, Hammami-Hauasli N, Hopfner B *et al.* Clustering of COL7A1 mutations in exon 73: implications for mutation analysis in dystrophic epidermolysis bullosa. *J Invest Dermatol* 1999; **112**:398–400.
- 50 Mellerio JE, Salas-Alanis JC, Talamantes ML *et al.* A recurrent glycine substitution mutation, G2043R, in the type VII collagen gene (COL7A1) in dominant dystrophic epidermolysis bullosa. *Br J Dermatol* 1998; **139**:730–7.
- 51 Almaani N, Liu L, Dopping-Hepenstal PJC *et al.* Identical glycine substitution mutations in type VII collagen may underlie both dominant and recessive forms of dystrophic epidermolysis bullosa. *Acta Derm Venereol* 2011; **91**:262–6.
- 52 Jiang W, Bu D, Yang Y, Zhu X. A novel splice site mutation in collagen type VII gene in a Chinese family with dominant dystrophic epidermolysis bullosa pruriginosa. *Acta Derm Venereol* 2002; **82**:187–91.
- 53 Chmel N, Bornert O, Hausser I *et al.* Large deletions targeting the triple-helical domain of collagen VII lead to mild acral dominant dystrophic epidermolysis bullosa. *J Invest Dermatol* 2018; **138**:987–91.
- 54 Turczynski S, Titeux M, Pironon N *et al.* Marked intrafamilial phenotypic heterogeneity in dystrophic epidermolysis bullosa caused by inheritance of a mild dominant glycine substitution and a novel deep intronic recessive COL7A1 mutation. *Br J Dermatol* 2016; **174**:1122–5.
- 55 Christiano AM, Fine JD, Uitto J. Genetic basis of dominantly inherited transient bullous dermolysis of the newborn: a splice site mutation in the type VII collagen gene. *J Invest Dermatol* 1997; **109**:811–14.
- 56 Fassihi H, Diba VC, Wessagowit V *et al.* Transient bullous dermolysis of the newborn in three generations. *Br J Dermatol* 2005; **153**:1058–63.
- 57 Shi B-J, Zhu X-J, Liu Y *et al.* Transient bullous dermolysis of the newborn: a novel *de novo* mutation in the COL7A1 gene. *Int J Dermatol* 2015; **54**:438–42.
- 58 van den Akker PC, Mellerio JE, Martinez AE *et al.* The inversa type of recessive dystrophic epidermolysis bullosa is caused by specific arginine and glycine substitutions in type VII collagen. *J Med Genet* 2011; **48**:160–7.
- 59 Schwieger-Briel A, Weibel L, Chmel N *et al.* A COL7A1 variant leading to in-frame skipping of exon 15 attenuates disease severity in recessive dystrophic epidermolysis bullosa. *Br J Dermatol* 2015; **173**:1308–11.
- 60 van den Akker PC, Pasmooij AM, Meijer R *et al.* Somatic mosaicism for the COL7A1 mutation p.Gly2034Arg in the unaffected mother of a patient with dystrophic epidermolysis bullosa pruriginosa. *Br J Dermatol* 2015; **172**:778–81.
- 61 Shipman AR, Liu L, Lai-Cheong JE *et al.* Somatic forward (nonrevertant) mosaicism in recessive dystrophic epidermolysis bullosa. *JAMA Dermatol* 2014; **150**:1025–7.
- 62 Vázquez-Osorio I, Chmel N, Rodríguez-Díaz E *et al.* A case of mosaicism in ectodermal dysplasia–skin fragility syndrome. *Br J Dermatol* 2017; **177**:e101–2.
- 63 Smith FJ, Morley SM, McLean WH. Novel mechanism of revertant mosaicism in Dowling-Meara epidermolysis bullosa simplex. *J Invest Dermatol* 2004; **122**:73–7.
- 64 Schuilenga-Hut PHL, Scheffer H, Pas HH *et al.* Partial revertant mosaicism of keratin 14 in a patient with recessive epidermolysis bullosa simplex. *J Invest Dermatol* 2002; **118**:626–30.
- 65 Jonkman MF, Scheffer H, Stulp R *et al.* Revertant mosaicism in epidermolysis bullosa caused by mitotic gene conversion. *Cell* 1997; **88**:543–51.
- 66 Pasmooij AM, Nijenhuis M, Brander R, Jonkman MF. Natural gene therapy may occur in all patients with generalized non-Herlitz junctional epidermolysis bullosa with COL7A1 mutations. *J Invest Dermatol* 2012; **132**:1374–83.
- 67 Darling TN, Yee C, Bauer JW *et al.* Revertant mosaicism: partial correction of a germ-line mutation in COL7A1 by a frame-restoring mutation. *J Clin Invest* 1999; **103**:1371–7.
- 68 Pasmooij AM, Pas HH, Bolling MC, Jonkman MF. Revertant mosaicism in junctional epidermolysis bullosa due to multiple correcting second-site mutations in LAMB3. *J Clin Invest* 2007; **117**:1240–8.
- 69 Pasmooij AM, Garcia M, Escamez MJ *et al.* Revertant mosaicism due to a second-site mutation in COL7A1 in a patient with recessive dystrophic epidermolysis bullosa. *J Invest Dermatol* 2010; **130**:2407–11.
- 70 Almaani N, Nagy N, Liu L *et al.* Revertant mosaicism in recessive dystrophic epidermolysis bullosa. *J Invest Dermatol* 2010; **130**:1937–40.

- 71 Tolar J, McGrath JA, Xia L *et al.* Patient-specific naturally gene-reverted induced pluripotent stem cells in recessive dystrophic epidermolysis bullosa. *J Invest Dermatol* 2014; **134**:1246–54.
- 72 Kiritsi D, He Y, Pasmooij AMG *et al.* Revertant mosaicism in a human skin fragility disorder results from slipped mispairing and mitotic recombination. *J Clin Invest* 2012; **122**:1742–6.
- 73 Lai-Cheong JE, Moss C, Parsons M *et al.* Revertant mosaicism in Kindler syndrome. *J Invest Dermatol* 2012; **132**:730–2.
- 74 Jonkman MF, Pasmooij AM. Revertant mosaicism – patchwork in the skin. *N Engl J Med* 2009; **360**:1680–2.
- 75 Padalon-Brauch G, Ben Amitai D, Vodo D *et al.* Digenic inheritance in epidermolysis bullosa simplex. *J Invest Dermatol* 2012; **132**:2852–4.
- 76 Vahidnezhad H, Youssefian L, Saeidian AH *et al.* Next generation sequencing identifies double homozygous mutations in two distinct genes (*EXPH5* and *COL17A1*) in a patient with concomitant simplex and junctional epidermolysis bullosa. *Hum Mutat* 2018; **39**:1349–54.
- 77 Kariminejad A, Vahidnezhad H, Ghaderi-Sohi S *et al.* Widespread aplasia cutis congenita in sibs with *PLEC1* and *ITGB4* variants. *Am J Med Genet A* 2019; **179**:1547–55.
- 78 Titeux M, Pendaries V, Tonasso L *et al.* A frequent functional SNP in the *MMP1* promoter is associated with higher disease severity in recessive dystrophic epidermolysis bullosa. *Hum Mutat* 2008; **29**:267–76.
- 79 Maccari ME, Speckmann C, Heeg M *et al.* Profound immunodeficiency with severe skin disease explained by concomitant novel *CARMIL2* and *PLEC1* loss-of-function mutations. *Clin Immunol* 2019; **208**:108228.
- 80 Cavalli G, Heard E. Advances in epigenetics link genetics to the environment and disease. *Nature* 2019; **571**:489–99.
- 81 Nyström A, Thriene K, Mittapalli V *et al.* Losartan ameliorates dystrophic epidermolysis bullosa and uncovers new disease mechanisms. *EMBO Mol Med* 2015; **7**:1211–28.
- 82 Odorisio T, Di Salvio M, Orecchia A *et al.* Monozygotic twins discordant for recessive dystrophic epidermolysis bullosa phenotype highlight the role of TGF-beta signalling in modifying disease severity. *Hum Mol Genet* 2014; **23**:3907–22.
- 83 Hayashi M, Kawaguchi M, Hozumi Y *et al.* Dystrophic epidermolysis bullosa pruriginosa of elderly onset. *J Dermatol* 2011; **38**:173–8.
- 84 Nakano A, Chao SC, Pulkkinen L *et al.* Laminin 5 mutations in junctional epidermolysis bullosa: molecular basis of Herlitz vs. non-Herlitz phenotypes. *Hum Genet* 2002; **110**:41–51.
- 85 Kiritsi D, Huilaja L, Franzke C-W *et al.* Junctional epidermolysis bullosa with *LAMB3* splice-site mutations. *Acta Derm Venereol* 2015; **95**:849–51.
- 86 Reimer A, Hess M, Schwieger-Briel A *et al.* Natural history of growth and anaemia in children with epidermolysis bullosa: a retrospective cohort study. *Br J Dermatol* 2020; **182**:1437–48.
- 87 De Rosa L, Secone Seconetti A, De Santis G *et al.* Laminin 332-dependent YAP dysregulation depletes epidermal stem cells in junctional epidermolysis bullosa. *Cell Rep* 2019; **27**:2036–49.e6.
- 88 Liu N, Matsumura H, Kato T *et al.* Stem cell competition orchestrates skin homeostasis and ageing. *Nature* 2019; **568**:344–50.
- 89 Has C. Chronic tissue damage: a common pathomechanism of genodermatoses. *Br J Dermatol* 2019; **181**:440–1.
- 90 Woodley DT, Cogan J, Hou Y *et al.* Gentamicin induces functional type VII collagen in recessive dystrophic epidermolysis bullosa patients. *J Clin Invest* 2017; **127**:3028–38.
- 91 Lincoln V, Cogan J, Hou Y *et al.* Gentamicin induces *LAMB3* nonsense mutation readthrough and restores functional laminin 332 in junctional epidermolysis bullosa. *Proc Natl Acad Sci U S A* 2018; **115**:E6536–45.
- 92 Atanasova VS, Jiang Q, Prisco M *et al.* Amlexanox enhances premature termination codon read-through in *COL7A1* and expression of full length type VII collagen: potential therapy for recessive dystrophic epidermolysis bullosa. *J Invest Dermatol* 2017; **137**:1842–9.
- 93 Turczynski S, Titeux M, Pironon N, Hovnanian A. Antisense-mediated exon skipping to reframe transcripts. *Methods Mol Biol Clifton NJ* 2012; **867**:221–38.
- 94 Maier K, He Y, Esser PR *et al.* Single amino acid deletion in *Kindlin-1* results in partial protein degradation which can be rescued by chaperone treatment. *J Invest Dermatol* 2016; **136**:920–9.

Supporting Information

Additional Supporting Information may be found in the online version of this article at the publisher's website:

Appendix S1 Clinical manifestations and genetics of classical epidermolysis bullosa; with supporting References.

Figure S1 Levels of skin cleavage and proteins involved in classical epidermolysis bullosa.

Figure S2 Epidermolysis bullosa (EB) naevi in (a) severe EB simplex; (b) intermediate junctional EB; (c) recessive dystrophic EB.

Figure S3 Junctional epidermolysis bullosa laryngo–onycho–cutaneous syndrome (JEB–LOC).

Figure S4 Recessive dystrophic epidermolysis bullosa (RDEB) inversa.

Table S1 Syndromic skin fragility disorders and affected genes.

Table S2 Characteristics of epidermolysis bullosa naevi.

Table S3 Peeling skin disorders.

Table S4 Erosive disorders.

Table S5 Hyperkeratotic disorders with skin fragility.