





Epidermolysis bullosa simplex–generalized severe type due to keratin 5 p.Glu477Lys mutation: Genotype-phenotype correlation and in silico modeling analysis

Leah Lalor MD¹  | Matthias Titeux PhD^{2,3} | Francis Palisson MD, PhD^{4,5} |
 Ignacia Fuentes PhD^{4,6} | María J. Yubero MD^{4,5} | Kaisa Tasanen MD⁷ |
 Laura Huilaja MD, PhD⁷ | Cristina Has MD⁸ | Gianluca Tadini MD⁹  |
 Anita N. Haggstrom MD¹⁰  | Alain Hovnanian MD, PhD^{2,3} | Anne W. Lucky MD¹¹ 

¹Division of Pediatric Dermatology, MCW Department of Dermatology, Milwaukee, Wisconsin

²Laboratory of Genetic Skin Diseases, Inserm UMR1163, Imagine Institute, Paris, France

³University Paris Descartes - Sorbonne Paris Cite, Paris, France

⁴Fundacion DEBRA Chile, Santiago, Chile

⁵Facultad de Medicina, Clinica Alemana Universidad del Desarrollo, Santiago, Chile

⁶Centro de Genetica y Genomica, Facultad de Medicina, Clinica Alemana Universidad del Desarrollo, Santiago, Chile

⁷Department of Dermatology, Pedego Research Unit, Oulu Center for Cell-Matrix Research, MRC Oulu, University of Oulu and Oulu University Hospital, Oulu, Finland

⁸Department of Dermatology, Medical Center - University of Freiburg, Freiburg, Germany

⁹Pediatric Dermatology, Fondazione IRCC Ca'Granda - Ospedale Maggiore Policlinico di Milano, Milan, Italy

¹⁰Department of Dermatology and Pediatrics, Indiana University, Indianapolis, Indiana

¹¹Epidermolysis Bullosa Center, Cincinnati Children's Hospital Medical Center, Cincinnati, Ohio

Correspondence

Leah Lalor, MD, Division of Pediatric Dermatology, MCW Department of Dermatology, Milwaukee, WI.
 Email: llalor@mcw.edu

Funding information

This work was partially supported by a grant from FONDECYT (11140440, Fondo Nacional de Desarrollo Científico y Tecnológico) to FP, IF, and MJY.

Abstract

Background/Objectives: Epidermolysis bullosa is a group of diseases caused by mutations in skin structural proteins. Availability of genetic sequencing makes identification of causative mutations easier, and genotype-phenotype description and correlation are important. We describe six patients with a keratin 5 mutation resulting in a glutamic acid to lysine substitution at position 477 (p.Glu477Lys) who have a distinctive, severe and sometimes fatal phenotype. We also perform in silico modeling to show protein structural changes resulting in instability.

Methods: In this case series, we collected clinical data from six patients with this mutation identified from their national or local epidermolysis bullosa databases. We performed in silico modeling of the keratin 5-keratin 14 coil 2B complex using CCBUILDER and rendered with Pymol (Schrodinger, LLC, New York, NY).

Results: Features include aplasia cutis congenita, generalized blistering, palmoplantar keratoderma, onychodystrophy, airway and developmental abnormalities, and a distinctive reticulated skin pattern. Our in silico model of the keratin 5 p.Glu477Lys mutation predicts conformational change and modification of the surface charge of the keratin heterodimer, severely impairing filament stability.

Conclusions: Early recognition of the features of this genotype will improve care. In silico analysis of mutated keratin structures provides useful insights into structural instability.

KEYWORDS

epidermolysis bullosa, genetic diseases/mechanisms, genodermatoses

1 | INTRODUCTION

Epidermolysis bullosa (EB) is an inherited mechanobullous disease resulting in blistering at sites of trauma. EB simplex (EBS) is the most common subtype and results in blistering within or above the epidermal basal layer. It is most commonly caused by autosomal dominant mutations in keratin 5 (*KRT5*) or keratin 14 (*KRT14*).¹ The protein products of these genes, keratin 5 (K5) and keratin 14 (K14), are paired intermediate filaments expressed in basal keratinocytes that contribute to mechanical stability.² Mutations in either of these genes result in altered proteins, causing instability of the cytoskeletal structure and blistering at pressure sites.

A range of severity is observed in EBS, from localized skin fragility to severe generalized mucocutaneous blistering.³ EBS-generalized severe (EBS-GS, formerly known as Dowling-Meara) is the most severe phenotype, characterized by generalized clustered blisters, severe palmoplantar keratoderma, dystrophic nails, and oral ulcerations.³ EBS-GS is most often caused by substitution mutations within the highly conserved 1A or 2B domains of *KRT5* and *KRT14*.⁴ There are currently 56 described causative mutations for EBS-GS in *KRT5* and *KRT14*.⁴

Keratins are heterodimeric proteins composed of a head, central rod domain, and tail region.^{5,6} The central rod domain is comprised of several subunits. Two subunits, 1A (or helix initiation peptide, HIP) and 2B (helix termination peptide, HTP), located at the ends of the central rod domain, are crucial for the creation of functional keratin filaments.⁷ Mutations in these regions interfere with early stages of filament elongation⁸ and are mutational “hot spots” in most hereditary keratin disorders.⁷

The change from guanine to adenine at nucleotide position 1429 in the coding DNA sequence within the HTP of *KRT5* results in a glutamic acid (Glu) to lysine (Lys) substitution at position 477 on K5 (p.Glu477Lys) and has been reported as a causative mutation for fatal or severe and generalized EBS.^{9–19} We describe six patients with an identical heterozygous c.1429 G>A (p.Glu477Lys) mutation in exon 7 of *KRT5*, located within the 2B domain of K5. We report these cases to elucidate the phenotype associated with this genotype. We also perform in silico modeling to understand the predicted structural changes this keratin mutation may cause and to discuss possible mechanisms by which this mutation confers a severe phenotype.

2 | MATERIALS AND METHODS

Of the six cases of EBS-GS caused by the K5 p.Glu477Lys substitution identified, two were from the United States and one each was from Italy, Germany, Finland, and Chile. Institutional review board approval was exempted. Mutational analysis was performed using Sanger sequencing, and the *KRT5* mutation was numbered according to the GenBank accession number NM_000424.3 and NP_000415.2 for mRNA and protein, respectively. None of the patients identified had a known family history of EB, and all were diagnosed around birth.

We performed in silico modeling of the K5-K14 coil 2B complex using CCBUILDER²⁰ and rendered with Pymol (Schrodinger, LLC).

3 | RESULTS

3.1 | Patient characteristics

Brief descriptions of each patient are listed in Table 1.

Case 1 was the first child of nonconsanguineous parents. He had extensive aplasia cutis at birth and generalized herpetiform blistering. He had severe oral blistering and required feeding support with a gastrostomy tube. He had epiglottal malacia in infancy that improved with age. He developed palmar and finger contraction, fusion of toes, severely dystrophic nails, and moderate palmoplantar keratoderma. He had delays in gross and fine motor development but normal cognitive development. He has continuously had severe and extensive blistering (Figure 1A,B). He has developed erythema and pigmentation in a strikingly uniform livedo-like pattern with some areas appearing more vascular and blanching and others more hyperpigmented. This pattern does not always correlate with blistering. Mutational analysis revealed a heterozygous c.1429 G>A (p.Glu477Lys) mutation in exon 7 of *KRT5*. Genetic analysis of both parents showed wild-type genotypes.

Case 2 was the fourth child of nonconsanguineous parents. At birth, he had extensive aplasia cutis requiring skin grafting and blood transfusions. He developed severe generalized blistering, some of which was herpetiform. Due to severe oral blistering, gastrostomy tube placement was placed. He was tracheostomy- and ventilator-dependent during infancy secondary to broncho- and laryngomalacia. He developed reticulated hyperpigmentation (Figure 2A), severely dystrophic nails, moderate to severe palmoplantar keratoderma (Figure 2B), and extensive hyperkeratosis, which has improved. Due to recurrent and severe infections and hypogammaglobulinemia, he received monthly intravenous immunoglobulin (IVIg) infusions during infancy and early childhood. He has had delays in speech, motor, cognitive, and social skills, but he is improving. He has had continuous severe and extensive generalized blistering. Mutational analysis revealed a heterozygous c.1429 G>A (p.Glu477Lys) mutation in exon 7 of *KRT5*. Genetic analysis of his parents has not yet been performed.

Case 3 was a girl born to healthy parents. At birth, she had hundreds of serohemorrhagic bullae. The baby died after 1 month of life due to severe sepsis caused by *Candida* species and other unidentified bacteria. Mutational analysis revealed a heterozygous c.1429 G>A (p.Glu477Lys) mutation in exon 7 of *KRT5*. Genetic analysis of both parents revealed wild-type genotypes.

Case 4 was the second child of healthy parents. At birth, she had extensive aplasia cutis of all extremities. As a neonate, she had pronounced skin fragility and oral blisters. She was fed with a gastrostomy tube and hospitalized for a long period after birth. In young childhood, she was in good general condition and developed blisters predominantly on her buttocks and back. Blisters healed with reticulated pigmentation and atrophy on the extremities. She also had

TABLE 1 Keratin 5 p.Glu477Lys mutation patient characteristics

	Patient 1	Patient 2	Patient 3	Patient 4	Patient 5	Patient 6
Parental testing	Wild-type	Unknown	Wild-type	Wild-type	Wild-type	Wild-type
Onset	Birth	Birth	Birth	Birth	Birth	Birth
Skin distribution	Generalized	Generalized	Generalized	Generalized	Generalized	Generalized
Skin/oral manifestations						
Aplasia cutis	Extensive	Extensive, legs		Extensive	Extensive	Extensive, legs
Blisters/pattern	Severe, clustered	Severe, some clustered	Severe	Severe, some clustered	Severe, palmoplantar with age	Severe in infancy, mild at childhood, mostly scattered
Milia	Absent	Absent		Absent	Mild	Extensive
Atrophic scars	Absent	Absent		Present	Present	Absent
Dystrophic nails	Severe	Severe		Severe	Moderate	Moderate
PPK	Moderate	Moderate to severe		Moderate to severe	Moderate to severe	Mild
Alopecia	Absent	Absent		Present	Absent	Diffuse
Tactile sensitivity	Moderate	Severe			Absent	Moderate
Hyperpigmentation/Erythema	Reticulate	Reticulate		Reticulate	Reticulate	Reticulate
Oral blistering	Severe	Severe		Present	Absent	During infancy
Enamel hypoplasia	Present	None		Present		Absent
Extracutaneous						
Growth retardation	Present	Absent		Present	Absent	Moderate
Eyes	Hyperopia	None		None	Photosensitivity	Congenital nystagmus, secondary corneal leukoma
Gastrostomy tube?	Yes	Yes		Yes	No	Yes
Pulmonary	None	Bronchomalacia, tracheostomy and ventilator in infancy		None	None	Tracheostomy and ventilator in infancy
Neurological	Developmental delays	Developmental delays, enlarged ventricles, craniosynostosis			Mild motor delay	Developmental delays
Hematological	None	Anemia as neonate, hypogammaglobulinemia		Mild anemia	None	Mild anemia, hypogammaglobulinemia and recurrent infections in infancy
Musculoskeletal	None	Muscular atrophy of lower legs		Muscular atrophy of lower legs		None
Ear, nose, throat	Epiglottal malacia	Epiglottal edema, suprastomal collapse, laryngomalacia		None	None	Severe laryngomalacia in infancy
Other	43 d in NICU	3 mo in NICU, hypoalbuminemia	Died at 1 mo due to sepsis	Extended time in NICU	Extended time in NICU	1 y in PICU, depapillated tongue at birth that resolved

NICU, Neonatal Intensive Care Unit; PICU, Pediatric Intensive Care Unit; PPK, palmoplantar keratoderma.

pronounced focal palmoplantar keratoses and mild finger contractures. Several nails were lost, and the rest were dystrophic. Mutational analysis revealed a heterozygous c.1429 G>A (p.Glu477Lys) mutation in exon 7 of *KRT5*. Genetic analysis of both parents showed wild-type genotypes.

Case 5 was the second child of healthy nonconsanguineous parents. Aplasia cutis and blistering were extremely severe at birth. In the neonatal period, she had some clustered but mostly scattered

generalized blistering and no mucosal blistering. She had moderate palmoplantar hyperkeratosis and severely dystrophic nails. After birth, she required feeding support with a nasogastric tube. For 2 years, she had continuous generalized blistering, after which the mechanical strength of her skin improved, but she still had palmoplantar blistering and hyperkeratosis. She also developed reticulate erythema, especially on the lateral trunk. She did not have growth retardation, but development of motor skills was slightly delayed. Mutational analysis revealed a

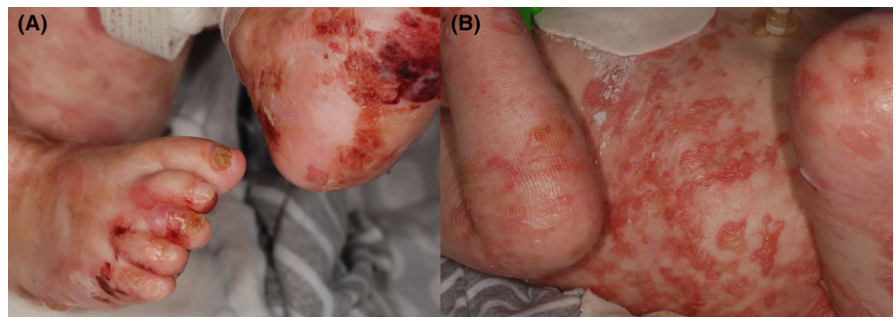


FIGURE 1 Patient 1 during infancy with (A) onychodystrophy and severe erosions and (B) generalized clustered blistering

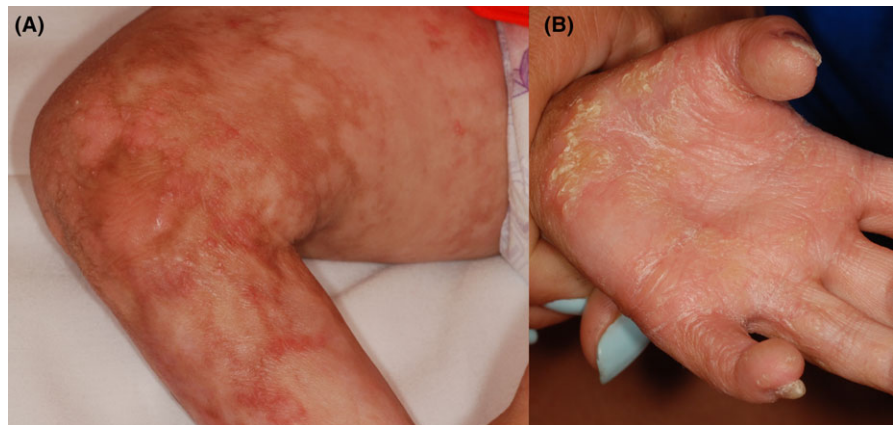


FIGURE 2 Patient 2 with (A) reticulated pigmentation and fewer blisters and (B) palmar hyperkeratosis and onychodystrophy

heterozygous c.1429 G>A (p.Glu477Lys) mutation in exon 7 of *KRT5*. Genetic analysis of both parents showed wild-type genotypes.

Case 6 was the second child of nonconsanguineous parents. At birth, she had aplasia cutis on the lower extremities; blistering mainly on the hands, legs, and buttocks; oral blistering; generalized milia; and absent or dystrophic nails. She required gastrostomy and tracheostomy placement, which have since been removed. For the first 6 months, she received monthly IVIg infusions due to recurrent severe infections and hypogammaglobulinemia. From infancy and currently during childhood, she has had mild blistering and palmoplantar hyperkeratosis and reticulated pigmentation. She had major delays in speech, motor, cognitive, and social skills, as well as failure to thrive. Mutational analysis revealed a heterozygous c.1429 G>A (p.Glu477Lys) mutation in exon 7 of *KRT5*. Genetic analysis of both parents showed wild-type genotypes.

3.2 | In silico modeling

Regarding the nature of the mutation, p.Glu477Lys predicts the replacement of an acidic, negatively charged residue (Glu) with a basic, positively charged residue (Lys) at position 477 of K5. In order to provide insight into the consequences of this change, we performed in silico modeling of the K5-K14 coil 2B complex using CCBUILDER²⁰ and rendered with Pymol (Schrodinger, LLC, New York, NY; Figure 3). The predicted surface model based on the van der Waals radius of atoms of the coiled-coil structure of 2B domains of K5 and K14 (Figure 3A) is close to the published model based on crystallographic data.²¹ In silico model of the K5 p.Glu477Lys

mutation predicts a local conformational change of arginine (Arg) 471, predicted to form a hydrogen bond with tyrosine (Tyr) 415 of K14 and an electrostatic interaction with Glu411 of K14.²² It also predicts a conformational change of leucine (Leu) 474 of K5 (Figure 3B,C), which is predicted to form a hydrophobic interaction with Leu419 of K14.²² Moreover, the local surface charge of the K5-K14 coil 2B complex is predicted to display a strong positive charge at its amino terminus and a strong negative charge at its carboxy terminus.²² Our in silico model reproduces a similar surface charge distribution, and mutation p.Glu477Lys is predicted to strongly modify the local surface charge of the heterodimer (Figure 3D).

4 | DISCUSSION

All six patients with the p.Glu477Lys mutation in K5 displayed EBS with severe generalized blistering and aplasia cutis and required intensive care unit admissions after birth (Table 2). One case was fatal. Blistering was mostly scattered with some clustering. In general, blistering improved with age, and surviving children developed a distinctive reticulated skin pattern that was erythematous, hyperpigmented, or both, with round, blanched patches of skin centrally. Most patients displayed severe onychodystrophy with moderate to severe palmoplantar hyperkeratosis. Often, there was severe neonatal oral blistering and poor weight gain, necessitating gastrostomy tube placement. Two patients displayed broncho- and/or laryngomalacia, requiring tracheostomy. None of the patients had corneal abrasions nor genitourinary blistering. Interestingly, most patients had

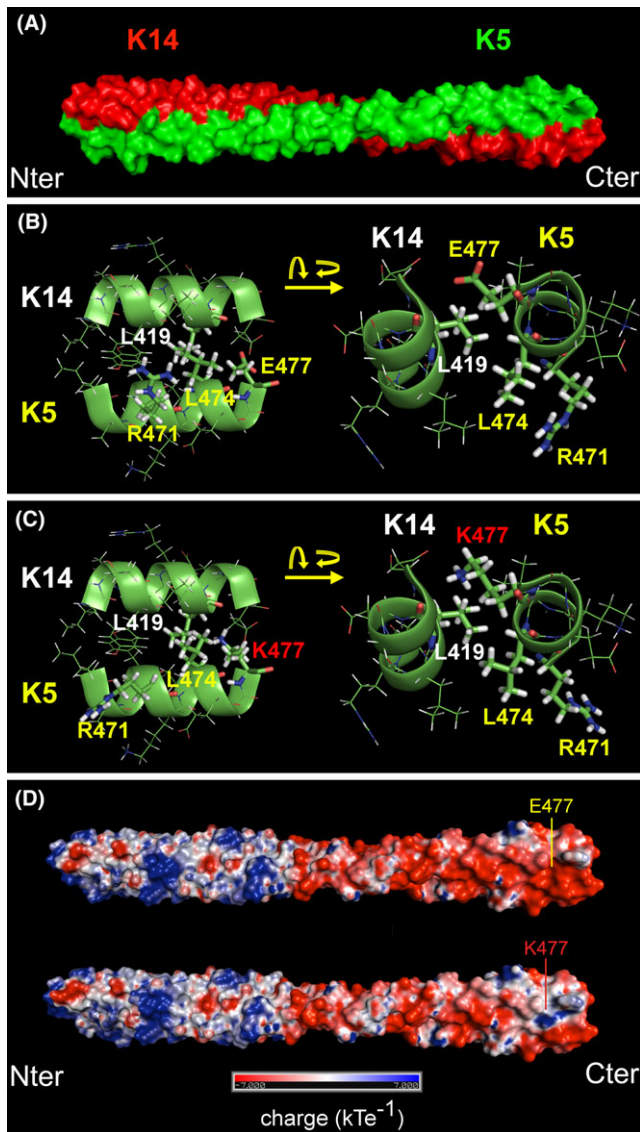


FIGURE 3 Keratin structure. (A) Surface model based on the van der Waals radius of atoms of the coiled-coil structure of 2B domains of keratin 14 (red, K14) and keratin 5 (green, K5). (B) Local structure of the coiled-coil structure within the 2B domain of wild-type K14 (IATYRRLLGE) and wild-type K5 (IATYRKLLGEE). Structure is shown from two different angles and only relevant residues are shown. Position of leucine 419 (L419) of K14 and arginine 471 (R471), leucine 474 (L474), and glutamic acid 477 (E477) of K5 are highlighted. (C) Local configuration of the coiled-coil structure within the 2B domain of wild-type K14 (IATYRRLLGE) and mutant K5 p.Glu477Lys (IATYRKLLGKE). Note the changes in positions of arginine 471 (R471) and leucine 474 (L474) of K5. (D) The Adaptive program Poisson-Boltzmann Solver (APBS)⁴² was used to calculate the potential map of the wild-type and mutant K14-K5 coil 2B complexes. Structures were prepared for APBS calculations using PDB2PQR software.⁴³ The calculated electrostatic surface potentials are similar to what have been calculated using crystallographic data,²² in particular the strong positive charge potential at the N-terminus and a strong negative charge potential at the C-terminus. Note the strong change in local electrostatic surface potential at the position of the mutation from glutamic acid 477 (E477) to lysine 477 (K477) (-7kTe^{-1} to 7kTe^{-1}). For all images, rendered using Pymol 1.7.7.1 (Schrodinger, LLC)

TABLE 2 Common clinical features seen in patients with keratin 5 p.Glu477Lys mutation

Common features (affected/total)
Severe, generalized blistering (6/6)
Blistering mostly scattered, some clustered (6/6)
Long stay in ICU after birth (6/6)
Reticulated pigmentation/erythema with age (5/6)
Extensive aplasia cutis congenita (5/6)
Severe onychodystrophy (5/6)
Blistering improves with age (5/6)
Gastrostomy tube placement (4/6)
Moderate to severe PPK (4/6)
Severe oral blistering (4/6)
Developmental delays (4/6)
Broncho- and laryngomalacia (3/6)

ICU, Intensive Care Unit; PPK, palmoplantar keratoderma.

multiple developmental delays. In contrast to the report of Sathishkumar et al,¹⁷ in which five of eight patients with the p.Glu477Lys mutation died, there was only one fatality of these six cases. Awareness of the potential severity of this particular EBS-GS mutation should alert providers to anticipate and treat the potential respiratory and nutritional complications they may develop.

The reticulated pattern of erythema, pigmentation, or both observed in these patients appears distinct and perhaps pathognomonic and is also noted by Komori et al¹⁸ in a recent report. It is different from the pigmentation observed in EBS with mottled pigmentation (EBS-MP), a condition due to different mutations in K5 (p.Pro25Leu, p.Gly138Glu, p.[Ile140AsnfsX0]+[Asp328His], p.Gly550AlafsX77),^{1,10,12,13,16,23-32} K14 (p.Met119Thr, p.Ile373-GlufsX53),^{13,33} and *EXPH5* encoding exophilin-5.³⁴ The condition is described as mottled pigmentation that may or may not be related to healing of blisters plus punctate palmoplantar keratoderma and onychodystrophy.³ Mutations in the V1 domain of the nonhelical head domain of K5 have been found in most cases of EBS-MP.^{1,10,12,13,16,23-32} It is unclear why this mutation results in this unique clinical phenotype, though research done by Irvine et al²⁴ indicates that the nonhelical head domain of K5 may be implicated in melanosome transport. How this may relate to our patients' mutation and phenotype remains to be elucidated.

The common features of this condition describe a unique and particularly severe EBS phenotype, which probably results from both the localization and nature of the glutamic acid to lysine substitution at position 477 on K5. Glu477 is located in the last position of the HTP sequence (469-477) of the rod domain of K5.^{8,9} This sequence is nearly perfectly conserved among all intermediate filament proteins, and like the HIP in the 1A domain, is known to play an essential role in keratin filament assembly.⁸ These two sequences tolerate no modification and account for the majority of EBS-GS mutations.⁴ Keratin rod domains have a coiled-coil configuration due to heptad repeats ("abcdefg"), which form a repeated pattern of charged and

hydrophobic amino acid residues, where residues at positions “a” and “d” are often hydrophobic and buried.⁷ Therefore, their defects usually have severe consequences for filament formation. In contrast, the charged surface-exposed residues (“b,” “c,” or “f”), which are in direct contact with the cytoplasm, have usually less deleterious effects when mutated. Glu477 is predicted to be located at the “d” position of the last heptad repeat of the 2B domain of K5.²² Residues at the “d” position of K5 are predicted to interact with residues at the “a” position of the corresponding heptad repeat of K14.⁸ Glu477 is thus predicted to interact with Leu419 located at the “a” position of K14, but the “d” positions in K5 are usually occupied by hydrophobic residues (such as leucine and alanine), and no glutamic acid residue is present in any “d” position in the heptads of K5 or K14 2B domains.²² Moreover, glutamic acid is a charged residue mainly found at position “g” (and at a lesser frequency at positions “b,” “c,” and “e”).²¹ In fact, radiograph crystallography data indicate that K5-K14 features more asymmetric salt bridges (between “g” and “e” positions) and fewer hydrophobic interaction clusters than homodimeric intermediate filaments. In addition, the HTP region of K5 features a dense array of nonhydrophobic interactions between K5 and K14 strands.²² In particular, arginine 471 of K5 interacts with Glu411 and Tyr415 of K14 through an electrostatic interaction and a hydrogen bond, respectively, while Leu474 of K5 (instead of Glu477) probably interacts with Leu419 of K14 through a hydrophobic interaction.²² Our *in silico* modeling analysis suggests that local changes are likely to modify the strength of these interactions and impair dimer and tetramer stability (Figure 3B,C). Additionally, our model of mutated p.Glu477Lys predicts a strong modification of the local surface charge of the heterodimer (Figure 3D). Such a modification of the electrostatic surface potential may also further impair the dimerization initiation, the axial alignment, and the lateral assembly of keratin coiled-coil dimers during filament assembly, contributing to mechanical instability.²²

Interestingly, Hut et al³⁵ reported a case of EBS-GS due to a leucine to glutamine substitution at position 419 of K14 (Leu419Gln), which is predicted to be located at position “a” of the last heptad repeat of K14. Though the presentation was less severe than our cases with K5 p.Glu477Lys, this supports the notion that amino acids located at “a” or “d” positions of the last heptad repeat of 2B and in the HIP region of K5 of K14 are of particular importance. It has been suggested that K14 mutations result in less severe phenotypes due to compensation by similar keratins, while no such compensation for mutated K5 has been demonstrated,³⁶ potentially explaining why the K14 p.Leu419Gln mutation resulted in a less severe phenotype than K5 p.Glu477Lys, despite those two residues being predicted to interact.

In addition to the p.Glu477Lys mutation in K5 reported here and by others, two other missense mutations at the 477 position in exon 7 have been reported.^{10,37} Schumann et al³⁷ describe a heterozygote for p.Glu477Asp. This mutation replaces an acidic, negatively charged amino acid (glutamic acid) by another acidic, negatively charged amino acid (asparagine), which may result in less drastic changes in dimer and tetramer formation and a less severe phenotype. The patient described by Hamada et al¹⁰ had localized EBS

with primary palmoplantar blistering beginning in early childhood. The K5 p.Glu477Gly mutation identified in this patient predicts a glutamic acid to glycine substitution. Because glycine is a small and amphoteric amino acid residue, this substitution may be less deleterious than glutamic acid to lysine, despite being at the same location.

It is not clear why several of the patients in our series had severe developmental delays beyond what might be expected for a chronically ill child. However, several investigators have discovered that keratins exert variable signaling functions unrelated to their mechanical ones.³⁸⁻⁴¹ We cannot say for certain that this K5 p.Glu477Lys mutation plays a causative role in their developmental delays, but perhaps with further research a relationship may become clear.

In conclusion, we describe six patients with an identical heterozygous p.Glu477Lys mutation in keratin 5 who display a consistent, severe, and sometimes fatal phenotype of EBS-GS characterized by severe generalized blistering, palmoplantar keratoderma, onychodystrophy, and distinctive, possibly pathognomonic, reticulated skin pattern. Early recognition of the phenotypic features of this genotype can improve care of these sick neonates.

ACKNOWLEDGMENT

We thank the patients and families for their willingness to participate and the physicians and scientists who provided DNA samples and clinical data.

ORCID

Leah Lalor  <http://orcid.org/0000-0003-1017-8649>

Gianluca Tadini  <http://orcid.org/0000-0003-1164-2802>

Anita N. Haggstrom  <http://orcid.org/0000-0002-9088-8079>

Anne W. Lucky  <http://orcid.org/0000-0002-6115-7584>

REFERENCES

- Bolling MC, Lemmink HH, Jansen GH, Jonkman MF. Mutations in KRT5 and KRT14 cause epidermolysis bullosa simplex in 75% of the patients. *Br J Dermatol*. 2011;164(3):637-644.
- Fuchs E. The cytoskeleton and disease: genetic disorders of intermediate filaments. *Annu Rev Genet*. 1996;30:197-231.
- Fine JD, Bruckner-Tuderman L, Eady RA, et al. Inherited epidermolysis bullosa: updated recommendations on diagnosis and classification. *J Am Acad Dermatol*. 2014;70(6):1103-1126.
- Szeverenyi I, Cassidy AJ, Chung CW, et al. The human intermediate filament database: comprehensive information on a gene family involved in many human diseases. *Hum Mutat*. 2008;29(3):351-360.
- Coulombe PA, Bousquet O, Ma L, Yamada S, Wirtz D. The “ins” and “outs” of intermediate filament organization. *Trends Cell Biol*. 2000;10(10):420-428.
- Bray DJ, Walsh TR, Noro MG, Notman R. Complete structure of an epithelial keratin dimer: implications for intermediate filament assembly. *PLoS ONE*. 2015;10(7):e0132706.
- Arin MJ. The molecular basis of human keratin disorders. *Hum Genet*. 2009;125(4):355-373.
- Steinert PM, Marekov LN, Fraser RD, Parry DA. Keratin intermediate filament structure. Crosslinking studies yield quantitative information

- on molecular dimensions and mechanism of assembly. *J Mol Biol.* 1993;230(2):436-452.
9. Stephens K, Ehrlich P, Weaver M, Le R, Spencer A, Sybert VP. Primers for exon-specific amplification of the KRT5 gene: identification of novel and recurrent mutations in epidermolysis bullosa simplex patients. *J Invest Dermatol.* 1997;108(3):349-353.
 10. Hamada T, Kawano Y, Szczecinska W, et al. Novel keratin 5 and 14 gene mutations in patients with epidermolysis bullosa simplex from Poland. *Arch Dermatol Res.* 2005;296(12):577-579.
 11. Muller FB, Kuster W, Wodecki K, et al. Novel and recurrent mutations in keratin KRT5 and KRT14 genes in epidermolysis bullosa simplex: implications for disease phenotype and keratin filament assembly. *Hum Mutat.* 2006;27(7):719-720.
 12. Yasukawa K, Sawamura D, Goto M, et al. Epidermolysis bullosa simplex in Japanese and Korean patients: genetic studies in 19 cases. *Br J Dermatol.* 2006;155(2):313-317.
 13. Arin MJ, Grimberg G, Schumann H, et al. Identification of novel and known KRT5 and KRT14 mutations in 53 patients with epidermolysis bullosa simplex: correlation between genotype and phenotype. *Br J Dermatol.* 2010;162(6):1365-1369.
 14. Jerabkova B, Marek J, Buckova H, et al. Keratin mutations in patients with epidermolysis bullosa simplex: correlations between phenotype severity and disturbance of intermediate filament molecular structure. *Br J Dermatol.* 2010;162(5):1004-1013.
 15. Kang TW, Lee JS, Kim SE, Oh SW, Kim SC. Novel and recurrent mutations in Keratin 5 and 14 in Korean patients with epidermolysis bullosa simplex. *J Dermatol Sci.* 2010;57(2):90-94.
 16. Garcia M, Santiago JL, Terron A, et al. Two novel recessive mutations in KRT14 identified in a cohort of 21 Spanish families with epidermolysis bullosa simplex. *Br J Dermatol.* 2011;165(3):683-692.
 17. Sathishkumar D, Orrin E, Terron-Kwiatkowski A, et al. The p.Glu477Lys mutation in keratin 5 is strongly associated with mortality in generalized severe epidermolysis bullosa simplex. *J Invest Dermatol.* 2016;136(3):719-721.
 18. Komori T, Dainichi T, Masuno Y, et al. p.Glu477Lys mutation in keratin 5 is not necessarily mortal in generalized severe epidermolysis bullosa simplex. *J Dermatol.* 2018;45:e209-e210.
 19. Kim EN, Harris AG, Bingham LJ, et al. A review of 52 pedigrees with epidermolysis bullosa simplex identifying ten novel mutations in KRT5 and KRT14 in Australia. *Acta Derm Venereol.* 2017;97(9):1114-1119.
 20. Wood CW, Bruning M, Ibarra A, et al. CCBUILDER: an interactive web-based tool for building, designing and assessing coiled-coil protein assemblies. *Bioinformatics.* 2014;30(21):3029-3035.
 21. Hanukoglu I, Ezra L. Proteopedia entry: coiled-coil structure of keratins. *Biochem Mol Biol Educ.* 2014;42(1):93-94.
 22. Lee CH, Kim MS, Chung BM, Leahy DJ, Coulombe PA. Structural basis for heteromeric assembly and perinuclear organization of keratin filaments. *Nat Struct Mol Biol.* 2012;19(7):707-715.
 23. Uttam J, Hutton E, Coulombe PA, et al. The genetic basis of epidermolysis bullosa simplex with mottled pigmentation. *Proc Natl Acad Sci USA.* 1996;93(17):9079-9084.
 24. Irvine AD, McKenna KE, Jenkinson H, Hughes AE. A mutation in the V1 domain of keratin 5 causes epidermolysis bullosa simplex with mottled pigmentation. *J Invest Dermatol.* 1997;108(5):809-810.
 25. Moog U, de Die-Smulders CE, Scheffer H, van der Vlies P, Henquet CJ, Jonkman MF. Epidermolysis bullosa simplex with mottled pigmentation: clinical aspects and confirmation of the P24L mutation in the KRT5 gene in further patients. *Am J Med Genet.* 1999;86(4):376-379.
 26. Horiguchi Y, Sawamura D, Mori R, Nakamura H, Takahashi K, Shimizu H. Clinical heterogeneity of 1649delG mutation in the tail domain of keratin 5: a Japanese family with epidermolysis bullosa simplex with mottled pigmentation. *J Invest Dermatol.* 2005;125(1):83-85.
 27. Pfendner EG, Sadowski SG, Uitto J. Epidermolysis bullosa simplex: recurrent and de novo mutations in the KRT5 and KRT14 genes, phenotype/genotype correlations, and implications for genetic counseling and prenatal diagnosis. *J Invest Dermatol.* 2005;125(2):239-243.
 28. Pascucci M, Posteraro P, Pedicelli C, et al. Epidermolysis bullosa simplex with mottled pigmentation due to de novo P25L mutation in keratin 5 in an Italian patient. *Eur J Dermatol.* 2006;16(6):620-622.
 29. Shurman D, Losi-Sasaki J, Grimwood R, et al. Epidermolysis bullosa simplex with mottled pigmentation: mutation analysis in the first reported Hispanic pedigree with the largest single generation of affected individuals to date. *Eur J Dermatol.* 2006;16(2):132-135.
 30. Trufant JW, Kreizenbeck GM, Carlson KR, Muthusamy V, Girardi M, Bosenberg MW. A transient epidermolysis bullosa simplex-like phenotype associated with bexarotene treatment in a G138E KRT5 heterozygote. *J Cutan Pathol.* 2010;37(11):1155-1160.
 31. Minakawa S, Nakano H, Nakajima K, et al. Mutational analysis on 16 Japanese population cases with epidermolysis bullosa simplex. *J Dermatol Sci.* 2013;72(3):330-332.
 32. Nagai H, Oiso N, Tomida S, et al. Epidermolysis bullosa simplex with mottled pigmentation with noncicatricial alopecia: identification of a recurrent p.P25L mutation in KRT5 in four affected family members. *Br J Dermatol.* 2016;174(3):633-635.
 33. Harel A, Bergman R, Indelman M, Sprecher E. Epidermolysis bullosa simplex with mottled pigmentation resulting from a recurrent mutation in KRT14. *J Invest Dermatol.* 2006;126(7):1654-1657.
 34. Turcan I, Pasmooij AM, Van den Akker PC, Lemmink H, Sinke RJ, Jonkman MF. Association of epidermolysis bullosa simplex with mottled pigmentation and EXPH5 mutations. *JAMA Dermatol.* 2016;152(10):1137-1141.
 35. Hut PH, v d Vlies P, Jonkman MF, et al. Exempting homologous pseudogene sequences from polymerase chain reaction amplification allows genomic keratin 14 hotspot mutation analysis. *J Invest Dermatol.* 2000;114(4):616-619.
 36. Coulombe PA, Kerns ML, Fuchs E. Epidermolysis bullosa simplex: a paradigm for disorders of tissue fragility. *J Clin Invest.* 2009;119(7):1784-1793.
 37. Schumann H, Roth W, Has C, et al. Verrucous carcinoma in epidermolysis bullosa simplex is possibly associated with a novel mutation in the keratin 5 gene. *Br J Dermatol.* 2012;167(4):929-936.
 38. Ku NO, Omary MB. A disease- and phosphorylation-related nonmechanical function for keratin 8. *J Cell Biol.* 2006;174(1):115-125.
 39. Kim S, Coulombe PA. Intermediate filament scaffolds fulfill mechanical, organizational, and signaling functions in the cytoplasm. *Genes Dev.* 2007;21(13):1581-1597.
 40. Ku NO, Strnad P, Zhong BH, Tao GZ, Omary MB. Keratins let liver live: mutations predispose to liver disease and crosslinking generates Mallory-Denk bodies. *Hepatology.* 2007;46(5):1639-1649.
 41. Marceau N, Schutte B, Gilbert S, et al. Dual roles of intermediate filaments in apoptosis. *Exp Cell Res.* 2007;313(10):2265-2281.
 42. Baker NA, Sept D, Joseph S, Holst MJ, McCammon JA. Electrostatics of nanosystems: application to microtubules and the ribosome. *Proc Natl Acad Sci USA.* 2001;98(18):10037-10041.
 43. Dolinsky TJ, Czodrowski P, Li H, et al. PDB2PQR: expanding and upgrading automated preparation of biomolecular structures for molecular simulations. *Nucleic Acids Res.* 2007;35(Web Server issue):W522-W525.

How to cite this article: Lalor L, Titeux M, Palisson F, et al. Epidermolysis bullosa simplex-generalized severe type due to keratin 5 p.Glu477Lys mutation: Genotype-phenotype correlation and in silico modeling analysis. *Pediatr Dermatol.* 2019;36:132-138. <https://doi.org/10.1111/pde.13722>