

Lateral hinge fracture in medial opening wedge high tibial osteotomy: a narrative review

Nicolás Franulic^{1,2}, José Tomas Muñoz³, Francisco Figueroa^{4,5}, Piero Innocenti¹ and Nicolás Gaggero¹

¹Hospital del Trabajador ACHS, Santiago, Chile

²Hospital Militar de Santiago, Santiago, Chile

³Universidad de los Andes, Santiago, Chile

⁴Hospital Sótero del Río, Santiago, Chile

⁵Clínica Alemana - Universidad del Desarrollo, Santiago, Chile

Correspondence
should be addressed
to N Franulic

Email
nafranulicm@achs.cl

- Lateral hinge fractures (LHF) are one of the most common complications of medial opening wedge high tibial osteotomy (MOWHTO), and are the leading cause of construct instability displacement, non-union, and varus recurrence after this procedure.
- To date, Takeuchi's classification is the most popular classification to describe this complication, and it can help surgeons to make intra and postoperative decisions.
- Opening medial gap width is the most recognized factor related to LHF occurrence.
- Recognizing the implications of LHF in patients' clinical and radiographic results has led many authors to propose surgical tips and the use of osteosynthesis materials such as K-wires and screws for its prevention, which should be considered when identifying risk factors for LHF during preoperative planning.
- The evidence for determining the optimal management of LHF is scarce and mostly supported by experts' opinions and recommendations; therefore, studies are still needed to identify the most appropriate behavior when dealing with such a complication.

Keywords

- ▶ lateral hinge fractures
- ▶ medial opening wedge high tibial osteotomy
- ▶ knee

EFORT Open Reviews
(2023) 8, 572–580

Introduction

Medial opening wedge high tibial osteotomy (MOWHTO) is a surgical procedure accepted as a treatment for medial compartment osteoarthritis in patients with knee varus malalignment, among other indications (1, 2, 3). Advantages of this surgery have been noted in comparison with the closing wedge high tibial osteotomy, such as minimizing the risk of common peroneal nerve injury (4, 5, 6). Nevertheless, as with any other surgical procedure, complications reported after MOWHTO are as high as 41.2%, with 24.7% of them being major complications (defined as complications that require additional or extended treatment) (7). Common major complications of MOWHTO are implant failure (8.2%), intraoperative lateral hinge fracture (LHF) (type II or III) (5.9%), distal locking screw breakage (4.7%), proximal locking screw breakage (3.5%), and superficial infection (2.4%), as listed by Yabuchi *et al.* (7).

LHFs are one of the most common complications of MOWHTO (8, 9, 10) and are the leading cause of construct instability, displacement, non-union, and varus recurrence after MOWHTO (2, 11, 12, 13, 14). Various risk factors have been described recently such as the location

of the osteotomy, hinge position, and the osteotomy width (15). The purpose of this article is to outline LHF characteristics, its prevention methods, and management.

Epidemiology and diagnosis

LHF reported incidence varies between 3 and 30%, mostly based on radiographic reports (2, 16, 17, 18, 19, 20, 21). Fractures may occur intraoperatively or during the postoperative period, with reported incidence rates up to 18 and 14%, respectively (2, 5, 16, 18, 22, 23).

Intraoperative fluoroscopy or immediate postoperative radiographs may underestimate the rate of occurrence of LHF (9, 24). Thus, multiple studies recommend the use of computed tomography (CT) as the gold standard to detect occult LHF because of the significant increase in detection rate compared to plain radiographs (8, 9, 10, 24, 25, 26).

In 2018, Lee *et al.* reported a significant increase in LHF detection rate by using CT scans compared with plain radiographs, 50 vs 14.6%, respectively (95% CI, $P < 0.001$). To date, this study has reported the greatest incidence of recognition of LHF (24).

In a systematic review published by Kim *et al.* in 2021, the estimated incidence of LHF using CT scans was increased by 9.9% in contrast to plain radiographs alone (25). This review reported that as many as 40% of LHF may not be diagnosed with intraoperative fluoroscopy or postoperative radiographs. The authors suggest CT evaluation in patients with consistent lateral pain at rest, intraoperative fluoroscopy or postoperative radiographs with suspected LHF, and if more than a 11.4 mm opening gap was performed.

To date, to the best of our knowledge, there are no studies that compare LHF detection rates between magnetic resonance imaging (MRI) and other modalities. Suh *et al.* (27) used MRI to evaluate the occurrence of LHF, detecting fractures in 25% of their patients.

Classifications

The first LHF classification was proposed in 2012 by Takeuchi *et al.* (2), differentiating them into three different types. Type I fractures extend throughout the osteotomy line and continue through the lateral cortex proximal or at the same level as the proximal tibiofibular joint. Type II fractures extend distal to the proximal tibiofibular joint. In type III fractures, the fracture line extends into the lateral tibial plateau (Fig. 1).

A recent biomechanical study conducted by Kang *et al.* (28) utilizing a finite element model of the knee, demonstrated that Takeuchi type I LHF had similar

stability as a MOWTHO with intact lateral hinge. The study reported that Takeuchi types II and III LHF were unstable fracture patterns.

Clinical studies (21, 29, 30) agree with the unstable behavior of LHF types II and III, as reported by Nakamura *et al.*, who described increased rates of delayed union, loss of correction, and overcorrection in comparison with type I LHF (17).

The Takeuchi classification allows the surgeon to properly characterize the fracture pattern and stability. However, it does not consider the fracture displacement. Dorofeev *et al.* proposed a modification to Takeuchi's original classification (31), by further subclassifying LHF in types A (non-displaced), B (with displacement >2 mm evident on first detection), and C (LHF not displaced in the first detection, but with displacement >2 mm in subsequent controls). In their retrospective study, the rates of non-union were significantly higher in patients who presented LHF (15.4 vs 1.8%). In this study, 76.9% of the LHF corresponded to Takeuchi's type I, and it was precisely this group that presented the highest rate of non-union (20%). This was probably due to the fact that the general management of type I fractures is less cautious compared to types II and III; however, the author does not specify in the study the management for these fractures. In their regression analysis, they highlighted the association between the degree of displacement and tibial non-union, with this parameter being more relevant than the specific type of fracture (31).

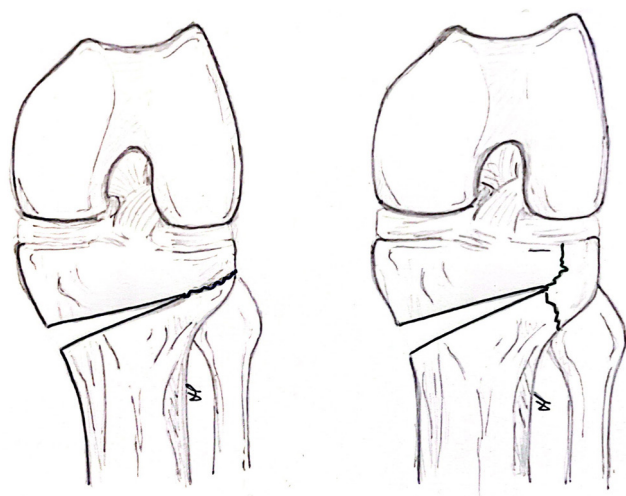


Figure 1

Takeuchi's Classification. Left: Type I fractures extend throughout the osteotomy line and continue through the lateral cortex proximal or at the same level as the proximal tibiofibular joint. Right: Type II fractures extend distal to the proximal tibiofibular joint and Type III fractures extends into the lateral tibial plateau..

Predictive factors

Multiple factors have been described in order to determine their correlation with LHF occurrence. Age (8, 10, 17, 21, 24, 25, 26, 29, 30, 32, 34, 35), body mass index (BMI) (8, 10, 17, 21, 24-26, 29, 30, 32, 34, 35), hip-knee-ankle angle (8, 21, 24, 25, 29, 35), fibular position (26, 33, 35), tibial plateau width (33, 35), osteotomy's position (21, 26, 29, 32), the magnitude of medial opening aperture (8, 10, 17, 21, 24-26, 30, 32, 34, 35), anterior gap and posterior gap (10, 26, 35), sagittal and coronal slope (10, 26), biplanar osteotomy (30), and wedge-hinge relation (21, 26) have been studied as contributing factors. Although only the opening medial gap width has shown consistent statistical significance throughout the literature (8, 10, 17, 21, 24, 25, 26, 30, 32, 34, 35). In a recent article published by Lee *et al.*, they established that the 11 mm cutoff for opening the medial gap had a sensitivity and specificity for LHF of 78.4 and 73.9%, respectively (26). Previous studies proposed a higher cutoff, varying between 11.4 and 12 mm (24, 25).

LHF consequences

LHF as a consequence of a MOWHTO has been a matter of discussion in recent years and is considered a critical factor that can lead to delayed union, non-union, and loss of correction (2, 11, 12, 13, 14, 17, 29, 34, 36, 37, 38).

Delayed union and non-union are among the most feared complications of LHF (12, 16, 21, 39). The retrospective study conducted by Dorofeev *et al.* reported significantly higher non-union rates in patients with LHF (15.4 vs 1.8%), a fact that led to a greater rate of re-osteosynthesis (10.3% in this series) (31). Song *et al.* described a significantly greater time to union in patients with LHF (7.3 months) in contrast with the nonfracture group (5 months) ($P < 0.001$) (40). It has been stated that Takeuchi's LHF type II had a higher risk of delayed union (41).

Osteotomy healing is not the only outcome affected by LHF, as fractures can alter the osteotomy correction precision and generate a sudden loss of correction on coronal alignment. Unstable fracture patterns, such as types II and III, or the presence of unnoticed complete osteotomies are considered risk factors that induce inadequate corrections. These unnoticed complete osteotomies may lead to imprecise correction even in type I stable patterns (29) since it is possible to lose the correction during the fixation of the osteotomy.

Loss of correction may alter the final tibial slope. Increases in tibial slope have been reported in patients with LHF and posterior cortex compromise. A 2.5° tibial slope change may be noticed as early as 3 weeks postoperatively in patients with LHF in comparison with 0.1° with the non-fractured posterior cortex (34).

Prevention

Recognizing the implications of LHF in the patients' clinical and radiographic results has led many authors to propose guidelines and new technical strategies to prevent this complication (2, 21, 17, 32, 42).

Diverse technical considerations have been described to diminish the LHF occurrence risk (2, 32, 42, 43, 44, 45, 46, 47). Lobenhoffer and Agneskirchner (45) recommend the preservation of 10 mm between the osteotomy and the lateral cortex. To do that, the osteotomy is set to reach the proximal third of the tibiofibular joint without extending proximally. Takeuchi *et al.* (2) described that only 5 mm between the osteotomy and the lateral cortex is needed. Kessler *et al.* (46), in line with Lobenhoffer and Agneskirchner, suggested 10 mm from the lateral cortex, in addition to a 20 mm bone bridge between the osteotomy and the lateral tibial plateau to minimize LHF risk.

Nakamura *et al.* (32) proposed a zone classification for hinge position, dividing osteotomies by their relation

with the proximal tibio-fibular joint (PTFJ) and their depth in below (B), above shallow (AM), above deep (AL), within shallow (WM), and within deep (WL). The authors found that WL had a 0.24 relative risk of type II/III LHF, recommending this zone as the hinge-safe zone.

A significant association had been found between a sufficient osteotomy – a cut including the anterior and posterior cortex and ending at the same level as the tibiofibular joint (as defined by Ogawa *et al.*) – and LHF absence (21). Biplanar osteotomies have been introduced as a novel technique to reduce the risk of LHF (48) and may allow the surgeon to create a greater wedge gap. Nevertheless, recent literature has been published against this idea, stating that biplanar osteotomies lead to higher LHF rates than uniplanar osteotomies (30), which might reflect the real contribution of the soft tissues around the PTFJ, biomechanical properties of the proximal tibia, and the surgical differences implemented between both techniques in this study.

The use of a protective K-wire as a preventive measure for LHF has been popularized recently, with some clinical and biomechanical studies confirming its utility (50, 51). The K-wire is positioned intersecting the cutting plane at the theoretical location of the lateral hinge, acting as a mechanical restraint, and reducing the risk of lateral cortex fracture (Fig. 2) (50, 51). A cadaveric study conducted by Dessyn *et al.* demonstrated that a protective K-wire may increase load failure and maximum tolerable displacement up to 880 and 260%, respectively (50). Cannulated screws have also been used intending to increase MOWHTO structural stability (52, 53, 54). The screw is inserted from the lateral cortex with a 50-degree angle in the coronal plane and a 38.5-degree angle in the axial plane into the zone just below the lateral and medial tibial plateau (52). Contrarily to the K-wire technique, which is used to prevent intraoperative LHF, cannulated screws are placed to prevent secondary LHF; therefore, they are inserted after the osteotomy's opening.

Other strategies, like the insertion of bone graft substitutes and allografts have been proposed to increase stability (10, 55, 56). Van Genechten *et al.* (55) impacted a structural gap-filling bone allograft in their series, adding additional stability to the osteotomy site. In their prospective series, they reported a significant reduction in postoperative pain, early ambulation, and short-term clinical outcomes. Only one unstable LHF with non-union was listed in complications. However, systematic reviews and meta-analysis have failed to prove significant results regarding time to union, delayed union and nonunion (57, 58, 59). Contrarily, the incidence of LHF was noted to be lower when no bone filler was used (59).

Computer-assisted surgery may offer the surgeon a better control of the osteotomy's depth. Saragaglia *et al.* have performed over 700 procedures between 2001 and

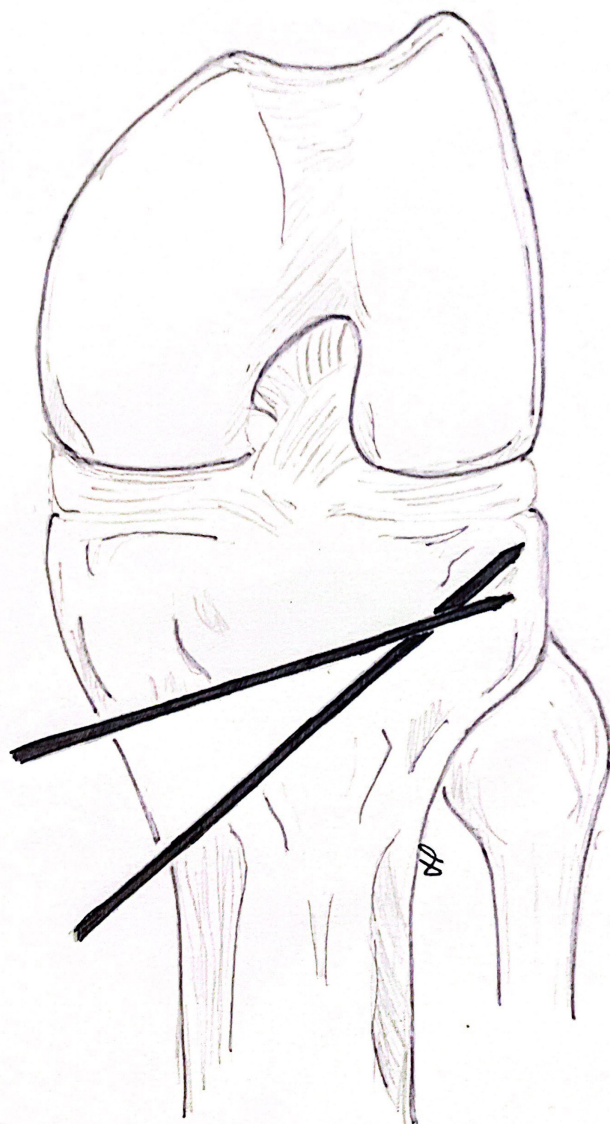


Figure 2

A K-wire is positioned intersecting the cutting plane at the theoretical location of the lateral hinge, acting as a mechanical restraint, and reducing the risk of lateral hinge fracture.

2015, obtaining more precise radiological outcomes (60). However, no significant differences have been found between navigated and conventional MOWHTO regarding clinical outcomes (61, 62), and no analysis has been made between the addition of navigation and the prevention of LHF.

Treatment

Stable fixation is required to assure a MOWHTO healing process. The presence of an LHF may affect the osteotomy's outcome; thus, it becomes paramount to treat this

complication if present. Yet, the evidence for determining the optimal management of LHF is scarce and mostly supported by experts' opinions and recommendations.

Takeuchi *et al.* (2) suggest that according to the type of LHF, there may be differences regarding the osteotomy's healing process, and the same was confirmed and developed by Nakamura *et al.* (17). Soft tissues adjacent to the proximal tibiofibular joint maintain the osteotomy's stability in type I LHF, allowing a normal rehabilitation program under strict follow-up if early full weight-bearing is authorized. In type II LHF, the energy is absorbed by the fibula and transformed into rotational energy generating external rotation between the two fragments and contributing to the development of correction loss and non-union. A non-weight-bearing (NWB) rehabilitation program until a callus formation is evidenced on the osteotomy's site is recommended. In type III LHF, the articular surface is damaged, as the fracture line exits through the lateral tibial plateau. The MOWHTO itself generates the passage of the axial load from the medial plateau to the lateral one, which is unfavorable in the presence of type III LHF. Takeuchi *et al.* (2) refer to type III LHF as a serious complication, but no clear recommendations are given to treat this particular type of LHF. On the other hand, Nakamura *et al.* (17) favors a modified rehabilitation protocol, in which partial weight-bearing is delayed for 3 weeks and full weight-bearing for 6 weeks. Additional fixation methods – lateral cannulated screws or locking plates – are only necessary if there is an articular surface displacement or loss of the osteotomy's correction.

Conservative treatment of type I LHF with no weight-bearing restriction, as recommended by Takeuchi *et al.* (2), has been endorsed by several authors (20, 25, 63) when using long locking plates. Locking plates have been advocated to generate higher rotational and axial stability in comparison to conventional plates (13, 38, 49) and diminishing non-union rates (20, 50). A recent systematic review by Kim *et al.* (25) found no statistically significant clinical or radiographic differences between patients that suffered from LHF and those who did not. All patient groups included in this study were fixed with long locking plates, being TomoFix Anatomical Plate (Synthes, Oberdorf, Switzerland), the most frequently used.

A cautious acceptance of this recommendation is suggested as several of the series that propose unrestricted weight-bearing programs really apply partial weight-bearing in the initial stages. For instance, 7 of the 11 studies included in the systematic review by Kim *et al.* (25) reported initial restrictive rehabilitation programs for patients with LHF, irrespective of LHF type and emphasizing the weight-bearing restriction role in LHF management (8, 10, 21, 24, 32, 51, 64). The same authors reported in a previous study (63) good results for 16 type

I and 21 type II LHF fixed with locked plate systems and a restrictive weight-bearing for 6 weeks. They described no correction loss or fracture union issues. Also, Lee *et al.* (10) observed a significant coronal alignment correction loss of type I LHF on their series while allowing full weight-bearing and, therefore, advised delaying weight-bearing regardless of the type of LHF.

Despite the positive results obtained from fixed locking systems and restrictive rehabilitation programs, these methods are not exempt from complications. Nakamura *et al.* (17) reported delayed union, loss of correction, and overcorrection in their case series of patients with unstable LHF type II and III, despite having used the TomoFix Plate and rehabilitation under a strict restrictive regime. Furthermore, a recent computational study (65) demonstrated that medial-locked plates do not grant sufficient stability for bone healing at the osteotomy and fracture line. An increment in medial plate's tension due to LHF was found, elevating the risk of failure. The authors of this study recommended fixation with medial and lateral locked plates in the event of LHF, questioning the capacity of a medial plate to avoid displacement. However, this computational study has important limitations as the fibula was not included in the biomechanical model, therefore their conclusions could not reflect the *in-vivo* scenario.

In order to avoid complications, authors like Stannard and Kfuri advocate a prolonged NWB program and

eventual fixation of type II LHF with a small-fragment lateral plate. For type III LHF, they recommend reduction and fixation with one or two lateromedial screws underneath the articular surface (66).

Author's approach

We consider that the recognition of predictive factors is paramount in the preoperative planning of any MOWHTO. In cases when we plan medial openings greater than 11 mm, we consider a freehand placement of a protective K-wire guided by fluoroscopy which intersects in the cutting plane at the theoretical location of the lateral hinge, generating a mechanical stop of the oscillating saw and increasing load failure and maximum tolerable displacement. We consider that K-wires are a quick, economic, effective, and simple preventive LHF method. In all MOWHTO, we preserve at least 10 mm between the osteotomy and the lateral cortex regardless of the width of the medial opening.

We highlight the importance of an active search of LHF by using intraoperative fluoroscopy after the initial opening and also after fixation, regardless of the size of the opening gap. A postoperative radiographic control with anteroposterior and lateral projections of the knee is performed in all our patients. We perform monthly serial radiological follow-ups up to 4 months post-operative. As proposed by Kim *et al.* (25), we use

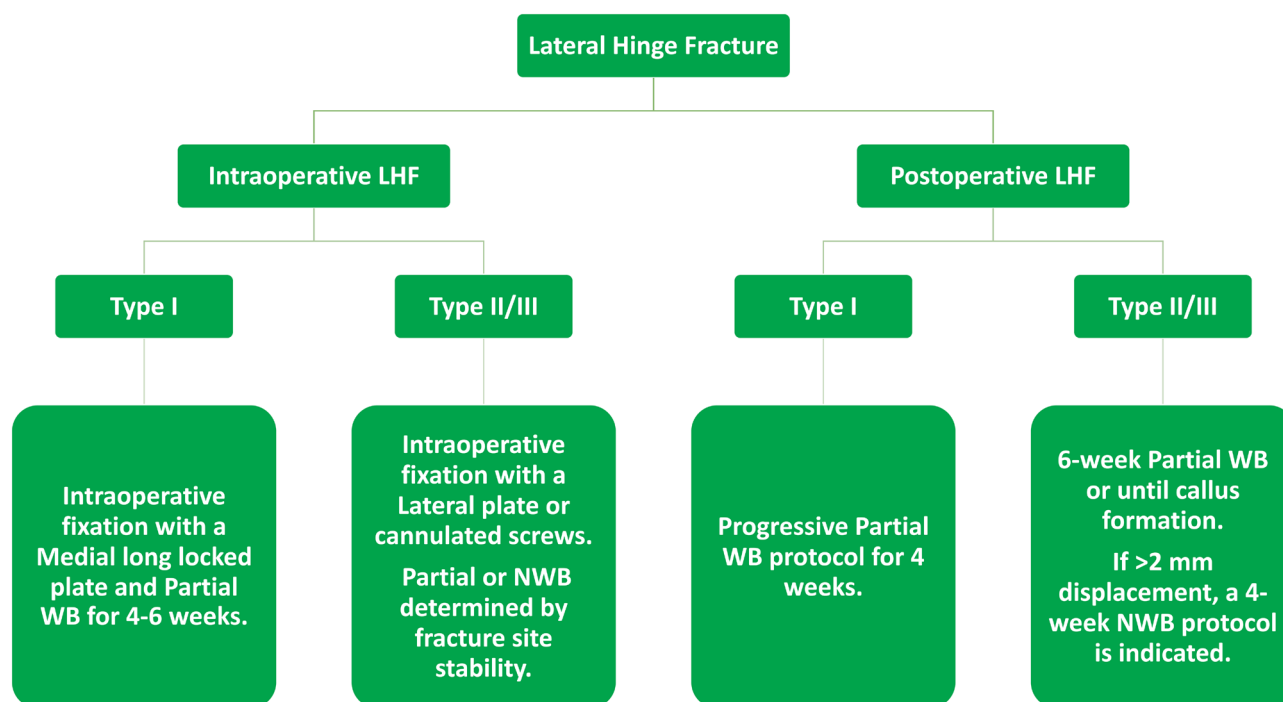


Figure 3

Author's lateral hinge fracture management algorithm. LHF: lateral hinge fracture. WB: weight bearing. NWB: Non weight bearing.

further CT evaluation in patients with consistent lateral pain at rest, intraoperative fluoroscopy or postoperative radiographs with suspected LHF, and if a 11.4 mm opening gap was performed.

If an LHF is detected, we recommend classifying it by using the Takeuchi *et al.* classification (2), as it is not only descriptive but also guides treatment for LHF. In this fashion, our treatment modality for LHF varies considering two main variables: Takeuchi's classification and time of fracture detection (intra or postoperative) (Fig. 3).

For intraoperative type I LHF, despite the results obtained by Chen *et al.* in their computational finite element model – with the limitations described earlier – (20), we consider that the fixation with a medial long locked plate is adequate, and we advocate partial weight-bearing during the initial 4–6 weeks of the rehabilitation period. If a type II or III LHF is evidenced during the surgical act, we prefer to add stability with a lateral anatomic plate or cannulated screws. Regarding the postoperative load, the initial NWB or partial weight-bearing protocol is determined by fracture site stability.

For postoperative type I LHF, we suggest a progressive partial weight-bearing protocol for 4 weeks. As for type II or III LHF identified postoperatively, we advocate for a 6-week partial weight-bearing period from fracture detection or until callus formation. If a >2mm displacement is identified postoperatively, considering the results obtained by Dorofeev *et al.* (31), we use a 4-week NWB protocol.

Irrespective of LHF type or time of detection, serial radiographic controls are maintained until the fracture is healed.

As a group, we advocate revision surgery in three scenarios. First, if correction loss is identified during follow-up. Second, in cases of established nonunion of the osteotomy site. And third, in displaced type III LHF with >5 mm of articular or condylar widening. It is important to add that to our knowledge, no evidence-based recommendations for revision surgery have been made in the literature.

Summary

LHFs are one of the most common complications of MOWHTO and the leading cause of displacement, nonunion and varus recurrence. Due to the importance of its detection, the use of CT scan is recommended when there is suspicion for its diagnosis demonstrating a significant increase in detection rates compared to standard X-rays. Takeuchi's classification is the most frequently used and it aids treatment decision-making, as stated by Nakamura *et al.* (17). The subclassification proposed by Dorofeev *et al.* (31) may assist decision treatment for postoperative LHF. Generally, type I LHF have been managed with

partial load restrictions or early full weight bearing in the postoperative period. On the other hand, in LHF types II and III NWB regimes are indicated. Regardless of the type of fracture, prevention is always preferable to treatment. Knowing predisposing factors – such as making a medial opening > 11 mm – is essential. Applying prevention strategies such as preserving at least a 5–10 mm distance from the osteotomy to the lateral cortex, positioning the hinge in Nakamura's WL safe zone (32), or the use of K-wires – while opening – or cannulated screws – after opening – may be good alternatives.

ICMJE conflict of interest statement

The authors declare that there is no conflict of interest that could be perceived as prejudicing the impartiality of the research reported.

Funding

This study did not receive any specific grant from any funding agency in the public, commercial, or not-for-profit sector.

References

1. Noyes FR, Goebel SX & West J. Opening wedge tibial osteotomy: the 3-triangle method to correct axial alignment and tibial slope. *American Journal of Sports Medicine* 2005 **33** 378–387. (<https://doi.org/10.1177/0363546504269034>) [published correction appears in *American Journal of Sports Medicine* 2006 **34** 1537. (<https://doi.org/10.1177/036354650603400919>)].
2. Takeuchi R, Ishikawa H, Kumagai K, Yamaguchi Y, Chiba N, Akamatsu Y & Saito T. Fractures around the lateral cortical hinge after a medial opening-wedge high tibial osteotomy: a new classification of lateral hinge fracture. *Arthroscopy* 2012 **28** 85–94. (<https://doi.org/10.1016/j.arthro.2011.06.034>)
3. Yoo MJ & Shin YE. Open wedge high tibial osteotomy and combined arthroscopic surgery in severe medial osteoarthritis and Varus malalignment: minimum 5-year results. *Knee Surgery and Related Research* 2016 **28** 270–276. (<https://doi.org/10.5792/kssr.15.075>)
4. Spahn G. Complications in high tibial (medial opening wedge) osteotomy. *Archives of Orthopaedic and Trauma Surgery* 2004 **124** 649–653. (<https://doi.org/10.1007/s00402-003-0588-7>)
5. Staubli AE, De Simoni C, Babst R & Lobenhoffer P. TomoFix: a new LCP-concept for open wedge osteotomy of the medial proximal tibia—early results in 92 cases. *Injury* 2003 **34** (Supplement 2) B55–B62. (<https://doi.org/10.1016/j.injury.2003.09.025>)
6. Takeuchi R, Ishikawa H, Aratake M, Bito H, Saito I, Kumagai K, Akamatsu Y & Saito T. Medial opening wedge high tibial osteotomy with early full weight bearing. *Arthroscopy* 2009 **25** 46–53. (<https://doi.org/10.1016/j.arthro.2008.08.015>)
7. Yabuuchi K, Kondo E, Onodera J, Onodera T, Yagi T, Iwasaki N & Yasuda K. Clinical outcomes and complications during and after medial open-wedge high tibial osteotomy using a locking plate: a 3- to 7-year follow-up study. *Orthopaedic Journal of Sports Medicine* 2020 **8** 2325967120922535. (<https://doi.org/10.1177/2325967120922535>)
8. Han SB, Choi JH, Mahajan A & Shin YS. Incidence and predictors of lateral hinge fractures following medial opening-wedge high tibial osteotomy using locking plate

system: better performance of computed tomography scans. *Journal of Arthroplasty* 2019 **34** 846–851. (<https://doi.org/10.1016/j.arth.2019.01.026>)

9. Lee BS, Jo BK, Bin SI, Kim JM, Lee CR & Kwon YH. Hinge fractures are underestimated on plain radiographs after open wedge proximal tibial osteotomy: evaluation by computed tomography. *American Journal of Sports Medicine* 2019 **47** 1370–1375. (<https://doi.org/10.1177/0363546519836949>)

10. Lee OS & Lee YS. Diagnostic value of computed tomography and risk factors for lateral hinge fracture in the open wedge high tibial osteotomy. *Arthroscopy* 2018 **34** 1032–1043. (<https://doi.org/10.1016/j.arthro.2017.08.310>)

11. Kazımoğlu C, Akdoğan Y, Sener M, Kurtulmuş A, Karapınar H & Uzun B. Which is the best fixation method for lateral cortex disruption in the medial open wedge high tibial osteotomy? A biomechanical study. *Knee* 2008 **15** 305–308. (<https://doi.org/10.1016/j.knee.2008.04.004>)

12. Meidinger G, Imhoff AB, Paul J, Kirchoff C, Sauerschnig M & Hinterwimmer S. May smokers and overweight patients be treated with a medial open-wedge HTO? Risk factors for non-union. *Knee Surgery, Sports Traumatology, Arthroscopy* 2011 **19** 333–339. (<https://doi.org/10.1007/s00167-010-1335-6>)

13. Miller BS, Dorsey WO, Bryant CR & Austin JC. The effect of lateral cortex disruption and repair on the stability of the medial opening wedge high tibial osteotomy. *American Journal of Sports Medicine* 2005 **33** 1552–1557. (<https://doi.org/10.1177/0363546505275488>)

14. Rose T & Imhoff AB. Complications after transgenicular osteotomies. *Operative Techniques in Orthopaedics* 2007 **17** 80–86. (<https://doi.org/10.1053/j.oto.2006.09.014>)

15. Chen P, Zhan Y, Zhan S, Li R, Luo C & Xie X. Biomechanical evaluation of different types of lateral hinge fractures in medial opening wedge high tibial osteotomy. *Clinical Biomechanics* 2021 **83** 105295. (<https://doi.org/10.1016/j.clinbiomech.2021.105295>)

16. Martin R, Birmingham TB, Willits K, Litchfield R, Lebel ME & Giffin JR. Adverse event rates and classifications in medial opening wedge high tibial osteotomy. *American Journal of Sports Medicine* 2014 **42** 1118–1126. (<https://doi.org/10.1177/0363546514525929>)

17. Nakamura R, Komatsu N, Murao T, Okamoto Y, Nakamura S, Fujita K, Nishimura H & Katsuki Y. The validity of the classification for lateral hinge fractures in open wedge high tibial osteotomy. *Bone and Joint Journal* 2015 **97-B** 1226–1231. (<https://doi.org/10.1302/0301-620X.97B9.34949>)

18. Schröter S, Gonser CE, Konstantinidis L, Helwig P & Albrecht D. High complication rate after biplanar open wedge high tibial osteotomy stabilized with a new spacer plate (Position HTO plate) without bone substitute. *Arthroscopy* 2011 **27** 644–652. (<https://doi.org/10.1016/j.arthro.2011.01.008>)

19. van Houten AH, Heesterbeek PJ, van Heerwaarden RJ, van Tienen TG & Wymenga AB. Medial open wedge high tibial osteotomy: can delayed or nonunion be predicted? *Clinical Orthopaedics and Related Research* 2014 **472** 1217–1223. (<https://doi.org/10.1007/s11999-013-3383-y>)

20. Dixel J, Fritzsche H, Beyer F, Harman MK & Lützner J. Open-wedge high tibial osteotomy: incidence of lateral cortex fractures and influence of fixation device on osteotomy healing. *Knee Surgery, Sports Traumatology, Arthroscopy* 2017 **25** 832–837. (<https://doi.org/10.1007/s00167-015-3730-5>)

21. Ogawa H, Matsumoto K & Akiyama H. The prevention of a lateral hinge fracture as a complication of a medial opening wedge high tibial osteotomy: a case control study. *Bone and Joint Journal* 2017 **99-B** 887–893. (<https://doi.org/10.1302/0301-620X.99B7.BJJ-2016-0927.R1>)

22. Fujisawa Y, Masuhara K & Shiomi S. The effect of high tibial osteotomy on osteoarthritis of the knee. An arthroscopic study of 54 knee joints. *Orthopedic Clinics of North America* 1979 **10** 585–608. ([https://doi.org/10.1016/S0030-5898\(20\)30753-7](https://doi.org/10.1016/S0030-5898(20)30753-7))

23. Seo SS, Kim OG, Seo JH, Kim DH, Kim YG & Lee IS. Complications and short-term outcomes of medial opening wedge high tibial osteotomy using a locking plate for medial osteoarthritis of the knee. *Knee Surgery and Related Research* 2016 **28** 289–296. (<https://doi.org/10.5792/ksr.16.028>)

24. Lee SS, Celik H & Lee DH. Predictive factors for and detection of lateral hinge fractures following open wedge high tibial osteotomy: plain radiography versus computed tomography. *Arthroscopy* 2018 **34** 3073–3079. (<https://doi.org/10.1016/j.arthro.2018.06.041>)

25. Kim JH, Lee DK & Park YB. Computed tomography detects hinge fractures after medial opening wedge high tibial osteotomy: a systematic review. *Arthroscopy* 2021 **37** 1337–1352. (<https://doi.org/10.1016/j.arthro.2020.11.031>)

26. Lee SJ, Kim JH, Baek E, Ryu HS, Han D & Choi W. Incidence and factors affecting the occurrence of lateral hinge fracture after medial opening-wedge high tibial osteotomy. *Orthopaedic Journal of Sports Medicine* 2021 **9** 23259671211035372. (<https://doi.org/10.1177/23259671211035372>)

27. Suh DW, Nha KW, Han SB, Cheong K & Kyung BS. Biplane medial opening-wedge high tibial osteotomy increases posterior tibial slope more than uniplane osteotomy. *Journal of Knee Surgery* 2022 **35** 1229–1235. (<https://doi.org/10.1055/s-0040-1722659>)

28. Kang KT, Koh YG, Lee JA, Lee JJ & Kwon SK. Biomechanical effect of a lateral hinge fracture for a medial opening wedge high tibial osteotomy: finite element study. *Journal of Orthopaedic Surgery and Research* 2020 **15** 63. (<https://doi.org/10.1186/s13018-020-01597-7>)

29. Song JH, Bin SI, Kim JM & Lee BS. Unstable lateral hinge fracture or occult complete osteotomy adversely affects correction accuracy in open-wedge high tibial osteotomy. *Arthroscopy* 2021 **37** 3297–3306. (<https://doi.org/10.1016/j.arthro.2021.04.032>)

30. Nha KW, Shin MJ, Suh DW, Nam YJ, Kim KS & Kyung BS. Uniplane medial opening wedge high tibial osteotomy relative to a biplane osteotomy can reduce the incidence of lateral-hinge fracture. *Knee Surgery, Sports Traumatology, Arthroscopy* 2020 **28** 1436–1444. (<https://doi.org/10.1007/s00167-019-05522-2>)

31. Dorofeev A, Tylla A, Benco M, Drescher W & Stangl R. Opposite hinge fractures in high tibial osteotomy: a displacement subtype is more critical than a fracture type. *European Journal of Orthopaedic Surgery and Traumatology: Orthopédie Traumatologie* 2020 **30** 297–305. (<https://doi.org/10.1007/s00590-019-02549-6>)

32. Nakamura R, Komatsu N, Fujita K, Kuroda K, Takahashi M, Omi R, Katsuki Y & Tsuchiya H. Appropriate hinge position for prevention of unstable lateral hinge fracture in open wedge high tibial osteotomy. *Bone and Joint Journal* 2017 **99-B** 1313–1318. (<https://doi.org/10.1302/0301-620X.99B10.BJJ-2017-0103.R1>)

33. Kim TW, Lee SH, Lee JY & Lee YS. Effect of fibular height and lateral tibial condylar geometry on lateral cortical hinge fracture in open wedge high tibial osteotomy. *Arthroscopy* 2019 **35** 1713–1720. (<https://doi.org/10.1016/j.arthro.2019.01.044>)

34. Lee SS, Nha KW & Lee DH. Posterior cortical breakage leads to posterior tibial slope change in lateral hinge fracture following opening wedge high tibial osteotomy. *Knee Surgery, Sports Traumatology, Arthroscopy* 2019 **27** 698–706. (<https://doi.org/10.1007/s00167-018-4977-4>)

35. Choi HG, Kim JS, Jung YS, Yoo HJ & Lee YS. Prediction and development of preventive strategies for lateral hinge fracture during opening wedge high tibial osteotomy based on osteotomy configurations. *American Journal of Sports Medicine* 2021 **49** 2942–2954. (<https://doi.org/10.1177/03635465211028985>)

36. Na YG, Kwak DS, Chong S & Kim TK. Factors affecting stability after medial opening wedge high tibial osteotomy using locking plate: a cadaveric study. *Knee* 2019 **26** 1313–1322. (<https://doi.org/10.1016/j.knee.2019.07.016>)
37. Hernigou P, Medevielle D, Debeyre J & Goutallier D. Proximal tibial osteotomy for osteoarthritis with varus deformity. A ten to thirteen-year follow-up study. *Journal of Bone and Joint Surgery. American Volume* 1987 **69** 332–354. (<https://doi.org/10.2106/00004623-198769030-00005>)
38. van Raaij TM, Brouwer RW, de Vlieger R, Reijman M & Verhaar JA. Opposite cortical fracture in high tibial osteotomy: lateral closing compared to the medial opening-wedge technique. *Acta Orthopaedica* 2008 **79** 508–514. (<https://doi.org/10.1080/17453670710015508>)
39. Schröter S, Freude T, Kopp MM, Konstantinidis L, Döbele S, Stöckle U & van Heerwaarden R. Smoking and unstable hinge fractures cause delayed gap filling irrespective of early weight bearing after open wedge osteotomy. *Arthroscopy* 2015 **31** 254–265. (<https://doi.org/10.1016/j.arthro.2014.08.028>)
40. Song KY, Koh U, Kim MS, Choi NY, Jeong JH & In Y. Early experience of lateral hinge fracture during medial opening-wedge high tibial osteotomy: incidence and clinical outcomes. *Archives of Orthopaedic and Trauma Surgery* 2020 **140** 161–169. (<https://doi.org/10.1007/s00402-019-03237-0>)
41. Goshima K, Sawaguchi T, Shigemoto K, Iwai S, Nakanishi A, Inoue D & Shima Y. Large opening gaps, unstable hinge fractures, and osteotomy line below the safe zone cause delayed bone healing after open-wedge high tibial osteotomy. *Knee Surgery, Sports Traumatology, Arthroscopy* 2019 **27** 1291–1298. (<https://doi.org/10.1007/s00167-018-5334-3>)
42. Han SB, Lee DH, Shetty GM, Chae DJ, Song JG & Nha KW. A "safe zone" in medial open-wedge high tibia osteotomy to prevent lateral cortex fracture. *Knee Surgery, Sports Traumatology, Arthroscopy* 2013 **21** 90–95. (<https://doi.org/10.1007/s00167-011-1706-7>)
43. Jacobi M, Wahl P & Jakob RP. Avoiding intraoperative complications in open-wedge high tibial valgus osteotomy: technical advancement. *Knee Surgery, Sports Traumatology, Arthroscopy* 2010 **18** 200–203. (<https://doi.org/10.1007/s00167-009-0928-4>)
44. Vanadurongwan B, Siripisitsak T, Sudjai N & Harnroongroj T. The anatomical safe zone for medial opening oblique wedge high tibial osteotomy. *Singapore Medical Journal* 2013 **54** 102–104. (<https://doi.org/10.11622/smedj.2013033>)
45. Lobenhoffer P & Agneskirchner JD. Improvements in surgical technique of valgus high tibial osteotomy. *Knee Surgery, Sports Traumatology, Arthroscopy* 2003 **11** 132–138. (<https://doi.org/10.1007/s00167-002-0334-7>)
46. Kessler OC, Jacob HA & Romero J. Avoidance of medial cortical fracture in high tibial osteotomy: improved technique. *Clinical Orthopaedics and Related Research* 2002 **395** 180–185. (<https://doi.org/10.1097/00003086-200202000-00020>)
47. Azoti W, Aghazade M, Ollivier M, Bahlouli N, Favreau H & Ehlinger M. Orientation and end zone of the osteotomy cut for high tibial osteotomy: influence on the risk of lateral hinge fracture. A finite element analysis. *Orthopaedics and Traumatology, Surgery and Research* 2021 **107** 103031. (<https://doi.org/10.1016/j.otsr.2021.103031>)
48. Türkmen F, Kaçira BK, Özkaya M, Erkoçak ÖF, Acar MA, Özer M, Tokar S & Demir T. Comparison of monoplanar versus biplanar medial opening-wedge high tibial osteotomy techniques for preventing lateral cortex fracture. *Knee Surgery, Sports Traumatology, Arthroscopy* 2017 **25** 2914–2920. (<https://doi.org/10.1007/s00167-016-4049-6>)
49. Stoffel K, Stachowiak G & Kuster M. Open wedge high tibial osteotomy: biomechanical investigation of the modified Arthrex Osteotomy Plate (Puddu Plate) and the TomoFix Plate. *Clinical Biomechanics (Bristol, Avon)* 2004 **19** 944–950. (<https://doi.org/10.1016/j.clinbiomech.2004.06.007>)
50. Dessyn E, Sharma A, Donnez M, Chabrand P, Ehlinger M, Argenson JN, Parratte S & Ollivier M. Adding a protective K-wire during opening high tibial osteotomy increases lateral hinge resistance to fracture. *Knee Surgery, Sports Traumatology, Arthroscopy* 2020 **28** 751–758. (<https://doi.org/10.1007/s00167-019-05404-7>)
51. Gulagaci F, Jacquet C, Ehlinger M, Sharma A, Kley K, Wilson A, Parratte S & Ollivier M. A protective hinge wire, intersecting the osteotomy plane, can reduce the occurrence of perioperative hinge fractures in medial opening wedge osteotomy. *Knee Surgery, Sports Traumatology, Arthroscopy* 2020 **28** 3173–3182. (<https://doi.org/10.1007/s00167-019-05806-7>)
52. Yang JC, Lobenhoffer P, Chang CM, Chen CF, Lin HC, Ma HH, Lee PY & Lee OK. A supplemental screw enhances the biomechanical stability in medial open-wedge high tibial osteotomy. *PLoS One* 2020 **15** e0244557. (<https://doi.org/10.1371/journal.pone.0244557>)
53. Yang J C-S, Chen CF & Lee OK. Benefits of opposite screw insertion technique in medial open-wedge high tibial osteotomy: a virtual biomechanical study. *Journal of Orthopaedic Translation* 2019 **20** 31–36. (<https://doi.org/10.1016/j.jot.2019.06.004>)
54. Jacquet C, Marret A, Myon R, Ehlinger M, Bahlouli N, Wilson A, Kley K, Rossi JM, Parratte S & Ollivier M. Adding a protective screw improves hinge's axial and torsional stability in High Tibial Osteotomy. *Clinical Biomechanics (Bristol, Avon)* 2020 **74** 96–102. (<https://doi.org/10.1016/j.clinbiomech.2020.02.015>)
55. Van Genechten W, Van den Bempt M, Van Tilborg W, Bartholomeeusens S, Van Den Bogaert G, Claes T & Claes S. Structural allograft impaction enables fast rehabilitation in opening-wedge high tibial osteotomy: a consecutive case series with one year follow-up. *Knee Surgery, Sports Traumatology, Arthroscopy* 2020 **28** 3747–3757. (<https://doi.org/10.1007/s00167-019-05765-z>)
56. Takeuchi R, Bito H, Akamatsu Y, Shiraishi T, Morishita S, Koshino T & Saito T. In vitro stability of open wedge high tibial osteotomy with synthetic bone graft. *Knee* 2010 **17** 217–220. (<https://doi.org/10.1016/j.knee.2009.09.002>)
57. Lash NJ, Feller JA, Batty LM, Wasiak J & Richmond AK. Bone grafts and bone substitutes for opening-wedge osteotomies of the knee: a systematic review. *Arthroscopy* 2015 **31** 720–730. (<https://doi.org/10.1016/j.arthro.2014.09.011>)
58. Han JH, Kim HJ, Song JG, Yang JH, Bhandare NN, Fernandez AR, Park HJ & Nha KW. Is bone grafting necessary in opening wedge high tibial osteotomy? A meta-analysis of radiological outcomes. *Knee Surgery and Related Research* 2015 **27** 207–220. (<https://doi.org/10.5792/ksrr.2015.27.4.207>)
59. Slevin O, Ayeni OR, Hinterwimmer S, Tischer T, Feucht MJ & Hirschmann MT. The role of bone void fillers in medial opening wedge high tibial osteotomy: a systematic review. *Knee Surgery, Sports Traumatology, Arthroscopy* 2016 **24** 3584–3598. (<https://doi.org/10.1007/s00167-016-4297-5>) [published correction appears in *Knee Surgery, Sports Traumatology, Arthroscopy* 2017 **25** 987. (<https://doi.org/10.1007/s00167-016-4344-2>)]

60. Saragaglia D, Chedal-Bornu B, Rouchy RC, Rubens-Duval B, Mader R & Pailhé R. Role of computer-assisted surgery in osteotomies around the knee. *Knee Surgery, Sports Traumatology, Arthroscopy* 2016 **24** 3387–3395. (<https://doi.org/10.1007/s00167-016-4302-z>)

61. Yan J, Musahl V, Kay J, Khan M, Simunovic N & Ayeni OR. Outcome reporting following navigated high tibial osteotomy of the knee: a systematic review. *Knee Surgery, Sports Traumatology, Arthroscopy* 2016 **24** 3529–3555. (<https://doi.org/10.1007/s00167-016-4327-3>)

62. Wu ZP, Zhang P, Bai JZ, Liang Y, Chen PT, He JS & Wang JC. Comparison of navigated and conventional high tibial osteotomy for the treatment of osteoarthritic knees with varus deformity: a meta-analysis. *International Journal of Surgery* 2018 **55** 211–219. (<https://doi.org/10.1016/j.ijsu.2018.03.024>)

63. Kim KI, Kim GB, Kim HJ, Lee SH & Yoon WK. Extra-articular lateral hinge fracture does not affect the outcomes in medial open-wedge high tibial osteotomy using a locked plate system. *Arthroscopy* 2018 **34** 3246–3255. (<https://doi.org/10.1016/j.arthro.2018.07.022>)

64. Kobayashi H, Akamatsu Y, Kumagai K, Kusayama Y & Saito T. Radiographic and computed tomographic evaluation of bone union after medial opening wedge high tibial osteotomy with filling gap. *Knee* 2017 **24** 1108–1117. (<https://doi.org/10.1016/j.knee.2017.06.002>)

65. Chen YN, Chuang CH, Yang TH, Chang CW, Li CT, Chang CJ & Chang CH. Computational comparison of different plating strategies in medial open-wedge high tibial osteotomy with lateral hinge fractures. *Journal of Orthopaedic Surgery and Research* 2020 **15** 409. (<https://doi.org/10.1186/s13018-020-01922-0>)

66. Stannard J, Schmidt A & Kfuri M *Knee Surgery*, 1st ed. New York: Thieme 2022.